Boston University

OpenBU **http://open.bu.edu**

Goldman School of Dental Medicine GSDM: Historical Theses and Dissertations (Open Access)

1969

The effects of autogenous and of decalcified, homologous bone grafts on the healing of experimental defects in the canine mandible

https://hdl.handle.net/2144/35622

Downloaded from DSpace Repository, DSpace Institution's institutional repository

9680-1
33

THE EFFECT OF AUTOGENOUS AND OF DECALCIFIED, HOMOLOGOUS BONE GRAFTS ON THE HEALING OF EXPERIMENTAL DEFECTS IN THE CANINE MANDIBLE.

Ramesh Narang, B.D.S.

LIBRARY
BOSTON UNIVERSITY
SCHOOL OF MEDICINE

Research performed at Boston University School of Graduate Dentistry.

Thesis submitted to the faculty of Boston University School of Graduate Dentistry in partial fulfillment of the requirements for the degree of Master of Science (M.Sc.D.) for graduate work in Oral Surgery.

March 1969

Boston University

Copyright and Digitization Notice

Copyright of this work is held by the author.

This work is protected against unauthorized copying under Title 17, United States code.

This reproduction is made available for personal use, and is not for distribution.

The image quality of this digital reproduction depends on the quality of the print original. Signatures and personal information, if present, have been redacted.

WU 610
N218e
1969
C.1

LIBRARY
BOSTON UNIVERSITY
SCHOOL OF MEDICINE

ACKNOWLEDGMENTS

The author expresses his sincere appreciation to the following people who advised, assisted and guided throughout the course of this project.

Henry M. Goldman, Dean of the School of Graduate Dentistry, whose devotion to research and to excellance in dental education has made this project possible.

Kurt H. Thoma, Professor of Oral Surgery, whose surgical ideas provided the basis of this project.

Melvyn H. Harris, Acting Chairman of Oral Surgery, whose advice and sincere personal interest in all phases in learning has guided this project to completion.

Herbert Wells, Professor of Pharmacology, for his invaluable assistance and continued encouragement.

Morris P. Ruben, Assistant Dean and Professor of Stomatology, for help in photography and development of ideas.

Morton J. Olin, Associate Professor of Oral Surgery, for his counsel and continued encouragement.

Arthur Bloom, Head of the Histopathology Laboratory, who arranged for acquisition and care of the animals, and prepared and stained all histologic sections with due care and patience.

Robert Pierce and his personnel at the Animal Research Laboratory for providing the necessary facilities.

My wife, Joan, whose encouragement, patience, and, most of all, understanding enabled me to complete this thesis.

TABLE OF CONTENTS

	Page
ACKNOWLEDGMENTS	i
TABLE OF CONTENTS	iv
LIST OF FIGURES	v
INTRODUCTION AND PURPOSE	1
HISTORY AND REVIEW OF THE LITERATURE	7
MATERIALS AND METHODS	16
RESULTS	23
DISCUSSION	28
SUMMARY	32
BIBLIOGRAPHY	34
APPENDIX	43-70

LIST OF FIGURES

Figure No.	Title	Page No.
	CLINICAL PHOTOGRAPHS	
1	Size of bone graft	44
2	Anaesthetic technic	44
3-5	Surgical procedure	45
6	Six week postoperatively specimen	46
7	Radiograph of six week specimen	46
	PHOTOMICROGRAPHS	
8-11	Autogenous graft two weeks postoperatively	47,48
12-15	Decalcified graft two weeks postoperatively	49,50
16-19	Control group two weeks postoperatively	51,52
20-22	Autogenous graft four weeks postoperatively	53,54
23-26	Decalcified graft four weeks postoperatively	54,55,56
27-30	Control gruop four weeks postoperatively	56,57,58
31-34	Autogenous graft six weeks postoperatively	58,59,60
35-38	Decalcified graft six weeks postoperatively	60,61,62
39-42	Control group six weeks postoperatively	62,63,64
43-46	Autogenous graft eight weeks postoperatively	64,65,66
47-51	Decalcified graft eight weeks postoperatively ...	66,67,68
52-55	Control group eight weeks postoperatively	69,70

INTRODUCTION AND PURPOSE

1. OBJECTIVES IN MANAGEMENT OF BONE DEFECTS:

Various bone and bone substitutes have been utilized in the treatment of bone defects and deformities of the jaws caused by trauma, infections (osteomyelitis), cysts, neoplasms, congenital defects and surgical procedures. The objectives of this treatment are to fill the gaps and defects in the bone, (83) to facilitate the healing of fractures, (3) to restore normal morphologic facial contour, (42,74,75) to restore normal function and mechanical strength, (96,114) to improve esthetics, (18,19,83) to eliminate bony defects in order to aid in the reduction and prevention of infection, (1,71) to prevent soft tissue growth into the defects, (96) and to aid in retention of prosthetic appliances, if necessary.(29) Grafts are also utilized where there is the chance of a fracture occurring during or after enucleation of large cysts or tumors.(103)

According to Bell (10) the ideal graft or bone substitute ought have the following properties:

a- it should cause little or no reaction in the tissue;

b- it can be rapidly revascularized;

c- it can be replaced with new host tissue;

d- there should be little or no surface resorption by the host.

At present, no such ideal graft or substitute is available.

The purpose of this experimental study was to investigate the comparative regenerative potential of autogenous grafts and of decalcified homologous grafts.

2. LIST OF BONE AND BONE SUBSTITUTES:

The various types of bone and bone substitutes which have been used are:

A- Autogenous graft: a graft from the same individual from one part to another. Maximum success has been reported in the literature with this type of graft. (32,34)

B- Homologous graft: a graft from one individual to another of the same species. (22,32)

C- Heterogenous graft: a graft from one species to different species. (9,35)

D- Alloplasts: Various bone substitutes such as plaster of paris,(23,87) urinary bladder epithelium,(58) alcohol,(17,98) cartilage,(18,34) oxidized cellulose (Gelfoam),(103) Ostamer (polyurethane foam),(68,97) glass,(67) calcium salts,(2,13, 59,109) polyvinyl sponge;(27,38,48) metals such as Titanium, (8) Tantalum,(11,40) and Vitallium;(36,113) and synthetic materials such as Silicone,(19) Teflon,(19,66,90) Silastic, (20,83) Supramyd,(20) methyl methacrylate (acrylic),(20,53,86) and Polyethylene.(20,25) These alloplasts have been used clinically and in experimental animals with some success.

3. BONE REGENERATION CONCEPT:

Hinds (55) suggested that bone regenerates in three possible ways:

a. By survival of the graft cells.

b. Invasion by the host bone into the graft.

c. Bone induction: The invasion of the graft by connective tissue cells possessing the pluripotential characteristics of primitive mesenchyme. These immigrant cells are then influenced to undergo differentiation into osteoblasts.

The most important single factor in the success of any graft appears to be the response of the host vascular bed. The host blood vessels and new connective tissue must grow into the transplant and replace the substance of the donor tissue in order to incorporate the transplant into the host bone.(3,91) Bone contact is one of the requirements for success in transplants.(103) That is, the donor bone must be in close approximation to the host bone in order for connective tissue invasion to take place.

The periosteum acts chiefly as a limiting membrane of bone. Underneath this, bone can live, grow, undergo repair and produce fresh periosteum after the latter has been removed. (49) It has been shown that periosteum has no true osteogenic activity.(65,67) However, bone grafts without periosteum are far inferior both in viability and osteogenesis to those covered with periosteum.(4,39)

Cortical compact bone has a dual blood supply, from endosteum and periosteum, either of which is adequate for its proper growth and repair. Compact bone which has lost both blood supplies, undergoes loss of viability. When it is utilized as a graft, this loss of viability can be seen microscopically by empty lacunae.(6) During healing the graft becomes vascularized, and then, in the new Haversian canals, new bone is deposited.(49) Thus, the bone is rebuilt by successive stages of resorption and apposition of new bone from beneath the periosteum which has proliferated from the adjoining host bone.(4) Cortical bone grafts are used where stability (22) and preservation of the shape of bone (37) are important factors. It is useful where strength is required at the fracture site.(1) As compared to cancellous bone, however, cortical bone has less osteogenic power.(1)

The presence of blood clot, preserved osteoblasts, and contact with living tissues are the requirements for growth of new bone.(41) Mowlem (74) began correcting facial defects with chip grafts in order to facilitate revascularization and survival of graft cells. He found that fixation of these grafts was obtained within ten days, when only a pressure dressing was utilized. Cancellous bone fragments stimulate osteoblasts and undifferentiated marrow cells of the host bone to grow into the midst of the fragments and lay down on many of the fragments' surfaces.(51) Cancellous bone unites more quickly and more

firmly than cortical bone (41) and is preferable in treatment of malunited fractures, tumors, cysts and infection.(1,37,47)

Bone formation by autoinduction has been first reported by Urist.(106) He suggested that, when using implants of decalcified bone, the degradation products of the organic matrix stimulate the production of wandering histiocytes, foreign body giant cells, inflammatory cells and connective tissue cells, all of which grow into and repopulate the area of the implant. Histiocytes are more numerous than any other cell form and may transfer collagenolytic activity to the substrate to cause dissolution of the matrix. The process is followed immediately by new bone formation by autoinduction. This involves both inductor cells and induced cells which are derived from the ingrowing cells of the host bed. The inductor cell is a descendant of a wandering histiocyte, while the induced cell is a fixed histiocyte or perivascular young connective tissue cell. Wherever bone induction occurs, there is a pool of stem cells, osteoprogenitor cells and small capillaries, surrounded by palisades of deeply basophillic, plump osteoblasts.

HISTORY AND REVIEW OF THE LITERATURE

1. AUTOGENOUS GRAFTS:

Ollier (81) in 1867, after wide animal experimentation, described the scientific basis for bone implantation. He demonstrated that a flap of periosteum transplanted from the tibia into the frontal region formed new bone in forty days. An emulsion made of the scrapings from the deep surface of periosteum transplanted into the thigh produced small bone nodules. If the periosteum was stripped from a bone, the latter regenerated a new periosteum. A bone, deprived of its periosteum, continued to live and increased in thickness and length. A bone, deprived of its periosteum and then fractured, united by normal callus formation. Bone formed from a free transplantation of periosteum was resorbed after 6-8 weeks. Ollier in his work with autogenous and homologous grafts concluded that autogenous grafts were superior to homologous bone grafts.

Macewen (67) in 1881 reported that removal of the entire periosteum did not effect the life and growth of bone and that the periosteum had no role in the osteogenesis.

On the other hand, Axhausen in 1908,(4) transplanted autogenous grafts and suggested that periosteum is very important for regeneration and osteogenesis. Grafts covered with viable periosteum showed marked cellular proliferation under the periosteum. Periosteum has a capacity for survival, proliferation and production of new bone, but it does not survive in those parts where muscle tissue or blood effusion prevent its organic

growth to the surrounding tissue.

Du Bouchet (39) in 1917 treated fractures of the mandible with autogenous grafts, including its periosteum, taken from the internal face of the tibia. He also employed bone chips from the tibia in bone cavities with some success. Mc Williams (71) in 1917 used costal cartilage in bone defects due to osteomyelitis because it was more resistant to infection as compared to bone. However, Cohen(28) and Converse (33) reported that intraoral bone or cartilage grafts can be satisfactorily implanted with proper use of antibiotics. They felt that the stabilization of bone fragments is a very important factor in the healing and union of the fragments.(70,79)

Groves (49) in 1917 stated that bone grafts were both osteogenic and osteoconductive, and stressed the need for complete fixation. Metal for fixation was not to interfere with osteogenesis. Carter,(26) Peer,(84,85) Campbell,(24) Converse,(34) Weinstein,(114) and Hirakawa (56) reported that autogenous grafts were superior to homologous grafts and were more readily tolerated by the host tissue.

Mowlem (74,75) treated war injuries with cancellous chip grafts. He concluded that immediate survival of bone graft probably depends upon the establishment of blood supply to its contained cells sufficiently early to ensure continued activity. Cancellous chip grafts were used for restoration of contour and continuity of fractures of facial and cranial bones.

This procedure is universally accepted and was used by Blocker, (14) Converse,(31) Dick,(37) and Gordon (46).

Autogenous cancellous chip grafts are of value in the repair of bone defects and in some forms of non-union or delayed union of fractures.(14,31,57,95) Mowlem concluded that cancellous chips from iliac crest have a greater degree of resistance to infection and are of use in the treatment of malunited fractures, osteomyelitis, cysts, tumors and mandibular defects.(1,52,61,69)

In autogenous grafts, bone formation occurs during the first two weeks both from the surrounding host bone and in the area of transplant. In homologous grafts, on the other hand, bone formation occurs primarily in the area of the transplant primarily by means of resorption of transplant and new bone formation. During these two weeks there is little activity from surrounding tissues.(92)

Peer (84,85) reported that the cells in free autogenous grafts tend to survive following transplantation, and that grafts in contact with unlike tissue (i.e. soft vs calcified tissues) were all replaced by fibrous tissue in 6-8 months. This occurred regardless of the presence or absence of periosteum on the grafts, or the thickness or thinness of the grafts.(84) Autogenous cancellous bone sets up new centers of osteogenesis, (3) inducing bone formation by metaplasia from fibroblasts (50,51) and the necessities for repair were good circulation and a high

blood level of antibiotics.(57) Fresh autogenous bone grafts were better tolerated by the host and were superior to preserved grafts, fresh homologous grafts or alloplastic materials. (24, 34,52,63)

2. DECALCIFIED HOMOLOGOUS GRAFTS:

The present controversy concerning the merits of decalcified bone matrix as a substitute for an autogenous bone graft began in the late 19th century. It was created by the use of decalcified bone for filling cavities by Deaver (35) in 1889. He decalcified bone in 15% solution of Hydrochloric acid for 2-4 weeks before transplantation. Miller (72) reported some successful cases and stated that decalcified bone was superior to fresh bone. He felt that the fresh bone not only was of no use but actually hindered the closure of the wound in large cavities of tibia.(72)

Bier (12) in 1892 reported complete failure and rejection of decalcified bone grafts. Barth (6) used decalcified matrix in dogs, rabbits and rats and reported that all grafts behaved alike. These experiments were repeated by many investigators, each employing a different solution for decalcification and the results did not resolve previous differences of opinion. As a consequence the use of decalcified matrix almost disappeared from bone surgery for sixty years.

Ray and Holloway (91) in 1957 described osteogenesis in implants in skull defects and suggested that, in rats, decalcified matrix was replaced more rapidly than undecalcified bone. All of the calcium incorporated into the callus came by way of the circulating blood from skeletal sources situated throughout the body rather than through diffusion from the graft.

Van de Putte and Urist (111,112) in 1965 reported that cortical bone matrix decalcified in hydrochloric acid, ethylene diamine tetra acetic acid, or formic citric acid provided the local conditions for histiotypic and organotypic formation of new bone. Undecalcified or recalcified matrix was resorbed more slowly and produced less new bone than decalcified matrix. Bone matrix, decalcified in nitric acid, did not induce bone formation but disintegrated in the extracellular fluid and incited a deleterious inflammatory reaction. Preparations of a complex prepared from decalcified matrix and Chondroitin sulfates A and C, did not enhance osteogenesis. Urist (106) described bone formation by autoinduction in 1965.

Bang and Urist (5) implanted decalcified dentin in the anterior chamber of the eye in rats and rabbits and stated that collagenous matrix of dentin similar to the bone matrix can induce bone formation. The new bone forms excavation chambers in the old dentin from a series of interactions of mesodermal cells in the aftermath of inflammation and ingrowth of capillary sprouts. The mechanism of bone induction is not known, the

possibility that the inducer is mobilized from old dentin matrix by collagenolytic cells and transferred to the undifferentiated perivascular connective tissue cells.

Yeomans and Urist (116) transplanted decalcified dentin and decalcified bone and there occured resorption by collagenolytic mesenchymal cells and sprouting capillaries. A consistently reproducible induction system was set up for osteogenesis. In the review of literature, decalcified grafts induce bone formation and are successful as grafts. (106)

3. HOMOLOGOUS GRAFTS:

Bush,(22) Wilson,(115) Reynolds and Oliver,(93,94) and Ramsey (95) recommend that homologous grafts can be used when the available supply of autogenous bone does not fulfill the particular requirements or if, in the course of an operation, a need arises which was not planned previously. Converse, Campbell and Inclan have stated that, clinically, autogenous and homologous grafts are equally successful as they form merely a framework and are entirely replaced by living bone from the host.(32,60) Preserved homocartilage,(18,101) and Ox cartilage (42) have been used in plastic and reconstructive surgery. Homografts of bone stimulate new bone formation by the host.(89) Shira (99) reported that cancellous homogenous chip grafts packed at the fracture site accelerate the healing process.

4. ALLOPLASTS:

Calhoun,(23) and Peltier (87) stated that plaster of

paris neither speeds nor slows the healing of defects in the alveolar process. Cole and Bubb in 1916 emphasized the role of prostheses in the jaws after surgery (29) and treated malunited fractures of the mandible with pedicle grafts.(30) Implants of bone, aorta or cartilage produced small deposits of new bone if the grafts were killed and fixed; this was reported by Nageotte, (77,78) and Polettini.(88) Albee and Morrison in 1920 reported that a single injection of triple calcium phosphate into the fracture site accelerated bone growth.(2)

Biological inert metals like Titanium,(8) Tantalum, (11,40) and Vitallium,(36,113) were used successfully as transplants. Healy and Sudbay,(53) and Penhale (86) used acrylic resin implants in immediate restoration of the surgically resected mandible except in cases of too much destruction of tissues.

Huggins,(58,59) Mc Carroll and Blocksom (59) and Bridges(16) state the osteogenesis occurs following transplantation of urinary epithelium. Thoma (103) recommends gelfoam as a substitute for autogenous grafts in bone cavities in absence of infection and if the wound can be closed. Charles,(27) Dresser, (38) Grindlay (48) recommend polyvinyl sponge in bone cavities. Synthetic sources of bone, calcium carbonate, calcium phosphate and magnesium phosphate have no influence on osteogenesis or ossification.(13,109) Silicones, Teflon, Supramyd, Methyl methacrylate, Polyethylene and Silastic have been used in plastic and reconstructive surgery with success.(19,20,25,66,83,90)

Polyurethane foam has been investigated in animals with experimentally produced fractures. The results demonstrated low tissue reactivity, the promotion, or at least lack of interference, with new bone formation. It was also demonstrated that the material possessed adhesiveness, strength, torsional stability, non toxicity, ease of handling and is absorbed slowly. (68,97) Orell (82) showed that fresh boiled bone is quite successful as compared to dried boiled bone.

Bell,(9) and Boyne (15) used anorganic heterogenous bone grafts in extraction sockets and bone cavities, none of these stimulated osteogenesis. Injection of alcohol and acid alcohol into soft tissues produced cartilage or bone in some (9-31%) of the cases in one to three months.(17,98) However, it is of interest that Kazanjian (62) reported spontaneous regeneration of bone following excision of part of the mandible in a ten year old patient.

MATERIALS AND METHODS

1. EXPERIMENTAL SUBJECTS:

Five mongrel dogs, approximately two years of age and weighing 14 to 15 Kgm., were used as the experimental animals. These were male dogs which were considered to be in good general health. Each dog was caged individually. Water was provided at all times and the dogs were fed a nutritionally sound diet.

2. ARMAMENTARIUM:

Electric hair clipper, Rubber tubing, Tincture of Zephrin, Syringes, Pentobarbital Sodium, Endotracheal tube, Towels, Towel clips, Knife with No. 15 Bard Parker blade, Tissue forceps, Periosteal elevators, Dissection scissors, Hemostats, Dental engine and straight hand piece, Tapered fissure burs number 701, Round burs No. 1-2, Sponges, Gauze, Needle holder, Needle $\frac{1}{2}$ circle taper number 12, Black silk suture 000, Plain catgut suture 000, 0.6N HCl and Normal saline.

3. PREPARATION OF 0.6N HCl.: (47)

Concentrated HCl. (15 ml.) was placed in a sterile bottle. This solution was made up to 300 ml. by adding 285 ml. of sterile distilled water, resulting in 0.6N HCl.

4. DECALCIFICATION AND PRESERVATION OF HOMOLOGOUS BONE: (116)

One dog was killed by adminstrating an overdosage of intravenous Pentobarbital Sodium. Under aseptic conditions the mandible was excised completely. The bone was sectioned from the lower border of the mandible in a standard size of 6mm. X 5mm. X 3mm. The standard size grafts were made by using a 701 tapered

fissure and round burs in an electric drill. Normal, sterile, saline was used as a coolant to prevent burning of the bone. Twenty standard grafts weighing approximately 3gms. were decalcified by storing them (without stirring) in 300 ml. of 0.6N HCl for twenty hours at room temperature. The acid was removed by repeated washing with 70% ethyl alcohol, and the samples were stored in 70% ethyl alcohol before transplantation.

5. ANAESTHESIA:

Each dog was weighed prior to administeration of the anaesthetic solution. The anaesthesia (Pentobarbital Sodium, 16mg. in 1ml./5 pounds of body weight) was administered intravenously into the cephalic vein. The tongue was then pulled forward and out between the jaws to insure a patent airway. The submandibular area was shaved and cleansed with soap and water. The dog was placed on the operating table and 5% Dextrose solution in normal saline was used as an intravenous drip. An endotracheal tube was placed. The submandibular area was prepared with several applications of tincture of Zephrin (1:1,000). Sterile drapes were placed around the head of the dog, keeping the submandibular area exposed. Additional anaesthesia, of one to two ml., was given at ninety minutes inorder to maintain the desired depth of anaesthesia throughout the surgical procedures ($2\frac{1}{2}$ to 3 hours).

6. SURGICAL PROCEDURE:

Aseptic technic was observed. A three inch incision was made along the inferior border of the mandible extending from the canine region posteriorly to the angle of the mandible. Submandibular dissection was carried out exposing the external surface of the mandible. The vessels were ligated and cut. An incision was made into the periosteum and the external surface of the mandible was exposed by detaching and reflecting the periosteum upwards. Five surgical defects, rectangular in shape, measuring 6mm. X 5mm. X 3mm. were outlined by creating several holes, using a No. 1 round bur in an electric drill. Normal saline was used as a coolant to prevent burning of the bone. The bur holes outlining the defects were then connected by a No. 701 fissure bur thus making the defects mobile. These surgical defects were made with care to avoid any injury to the roots of the teeth, inferior alveolar nerve or blood vessels. The mobilized bone was then removed and placed in normal saline. All the defects were shaped properly and sprayed with normal saline. Two decalcified homologous grafts were selected and placed into two bony defects fitting as tightly as possible. Two autogenous grafts were placed into the bone defects but not in the same defect from which they were removed. The fifth defect was left as a control. Sponges soaked in normal saline were placed over the flaps and bone to prevent dehydration during the surgical procedure. The soft tissues were approximated and the

incision closed in layers with several 000 silk sutures. The area was again washed with tincture of Zephrin 1:1,000. The endotracheal tube and the intravenous drip were removed. During this surgical procedure, each dog received 250ml. of 5% Dextrose solution in normal saline by intravenous drip. The dog was returned to his cage and placed in a comfortable position. The tongue was placed between the jaws to prevent any obstruction to the airways until conciousness was regained. Each surgical procedure lasted about three hours. After two weeks, a similar surgical procedure was carried out on the other side of the mandible in each dog. During the second procedure, the sutures were removed from previous operative site.

7. POSTOPERATIVE PHASE:

No special postoperative precautions were taken except that each dog was made comfortable and his airway maintained until he regained conciousness. Adequate food and water were provided at all times.

8. SACRIFICING PROCEDURE:

To study the comparative healing in the surgically prepared bony defects, the dogs were sacrificed according to the following schedule:

ANIMAL NUMBER	SACRIFICED
A and D	after 4 weeks
B	died after 4 weeks
C	after 8 weeks

Each dog was sacrificed by an overdosage of intravenous Pentobarbital Sodium (approximately three times the anaesthetic dose). One dog died unexpectedly and of an unknown cause after four weeks. Each mandible was surgically excised within an hour after death except in the case of dog B, where it was excised 4-18 hours after death. X-rays were taken and the specimens obtained were as follows:

DISTRIBUTION OF GRAFTS PER SIDE

DOG#	SIDE	HEALING TIME IN WEEKS	DECALCIFIED	AUTOGENOUS	CONTROL
A	LEFT	2	2	2	1
A	RIGHT	4	2	2	1
B	RIGHT	4	2	2	1
C	LEFT	6	2	2	1
C	RIGHT	8	2	2	1
D	LEFT	2	2	2	1
D	RIGHT	4	2	2	1
			14	14	7

The specimens obtained were fourteen decalcified grafts, fourteen autogenous grafts and seven controls for a total of thirty-five bony defects in four dogs. In dog B, four grafts and a control from the right side were included in the study.

9. HISTOLOGICAL PREPARATION:

Each mandible was placed in 10% neutral formalin. After one week of fixation each half of the mandible, containing four grafts and a control, was divided into five individual sections. The specimens were decalcified in 10% nitric acid for five days, and washed for 24 hours in running water. The specimens were serially sectioned at a thickness of 6-8 microns, and stained with Hematoxylin-Eosin and Goldman-Bloom (connective tissue stain) stains.(45) Photographs of these sections were taken.

RESULTS

1. CLINICAL OBSERVATIONS:

A total of five dogs were used in the experimental study, with one dog being used only as a source of homologous graft tissue. One dog died of infection. There were no obvious anaesthetic complications. The oozing of blood was continous from the mandible when the periosteum was incised, reflected and retracted. Although no vasoconstrictor was used, the pressure of autogenous and decalcified grafts controlled the bleeding from the bony defects. All grafts remained in proper position without any fixation. This was achieved because of the shape of the grafts and the close approximation of the overlying periosteum.

The animals were observed daily and there were no signs of local infection in, or around, the grafts. The soft tissues healed in approximately 7-10 days. By tapping the mandible, after removing the periosteum, it was observed that all twenty-eight grafts were accepted by the tissues, and were firm in the mandible after two weeks. In the control group (eight weeks post-operatively) the mandibular defect was filled with new bone of 2mm. thickness in the center. The gross appearance of autogenous and decalcified grafts (figure 6) demonstrated a near perfect fit of the grafts to the outer surface of the mandible at six weeks post-operatively. It was assumed on clinical basis that all teeth remained vital (without testing the vitality) as care was taken while making the mandibular defects not to interfere with the apical areas of the teeth and the contents of the mandibular canal.

2. HISTOLOGICAL STUDIES:

CONTROL GROUP:

Microscopic examination of unfilled mandibular defects, in which blood clots had been allowed to form, revealed the following. The two week specimens showed fibrous connective tissue, fibroblasts, capillaries, inflammatory cells and red blood cells (figures 16,17,18 and 19). Some new bone formation was observed. In the four, six and eight week specimens there was a gradual increase in osteogenic activity and new bone formation (figures 27,28,29,30,39,40,41,42,52,53,54 and 55). In the eight week specimen (figures 52,53) new bone formation was absent in the superficial central portion and the defect was not completely filled with new bone. In general these bone defects did not fill in to any great extent.

AUTOGENOUS GRAFTS:

The two week specimen (figures 8,9,10 and 11) showed dense fibrous connective tissue containing the calcified bone graft. Viable cells were observed in the lacunae. Capillaries and chronic inflammatory cells, particularly lymphocytes, were seen in the fibrous connective tissue. Osteoblastic activity and the formation of osteoid tissue was seen in a few areas on the host side of the defects. Notice the presence of fibrous tissue and empty space (an artifact) separating the graft from the host bone in figure 8.

The four week specimens revealed a greater degree of osteoblastic activity on the surface of the host bone (figures 20,21 and 22). New centers of bone formation were seen in the connective tissue between the host bone and the graft. Note the bony union of the graft to the host bone in one area in the above figures. Osteoclastic activity was not seen.

The six weeks specimens (figures 31,32,33 and 34) revealed osteoblastic activity and new bone (bony union) formation between the graft and the host bone. There was less connective tissue apparent in these than in the previous sections. Bony and fibrous union between the graft and host bone can be seen in figures 31 and 32.

The eight week specimens revealed extensive bone formation on the graft surfaces, on the host bone, and in the connective tissue. The bony and fibrous union of the graft to the host bone (figures 43,44,45 and 46) is especially clear.

DECALCIFIED HOMOLOGOUS GRAFTS:

The two week specimens demonstrated fibrous connective tissue containing chronic inflammatory cells and capillaries engorged with red blood corpuscles. Osteoblastic activity and formation of osteoid tissue were seen on the host bone. Notice the empty space and fibrous stroma separating the nonviable acellular decalcified graft from the host bone (figures 12,13 14 and 15).

The four week specimens revealed osteoclastic activity on the acellular grafts as shown in figures 23,24,25 and 26. New bone formation was seen in the fibrous connective tissue and on the host bone.

The six week specimens (figures 35,36,37 and 38) revealed new bone formation which was separated from the host bone by fibroblastic stroma. Notice the amount of vascularity of new bone and fibrous connective tissue and also the formation of Haversian canals. Bone formation was also noticed along the mandibular defects.

In the eight week specimens the grafts were almost completely replaced by new bone (figures 47,48,49,50 and 51). The new bone possessed a Haversian system and the lamellae were arranged in concentric circles around the Haversian canals. The sections stained with connective tissue stain, revealed new bone and fibrous connective tissue (blue in color) and calcified bone (golden in color). In general, the degree of new bone formation appeared to be in somewhat greater in the decalcified grafts and very rapid than in the autogenous grafts. The fibrous connective tissue response to decalcified grafts was less dense than that produced in response to autogenous grafts.

DISCUSSION

AUTOGENOUS GRAFTS:

All fourteen of the autogenous cortical bone grafts were accepted by the tissues. New bone bridging the graft to the host bone was apparent at the end of four weeks. It was noted that the amount of new bone bridging the graft to the host bone was increased in amount at the end of eight weeks. Autogenous grafts showed no evidence of osteolysis, which was marked in decalcified homologous grafts. Also, the autogenous grafts were partially surrounded and separated from the host bone by dense fibrous connective tissue. This phenomenon of fibrous connective tissue, could be a result of discrepancy in size between the autogenous graft and the bony defect, a discrepancy which did not exist in the case of homologous decalcified grafts. The results indicated that the osteocytes in the autogenous grafts maintain their viability following transplantation.

DECALCIFIED HOMOLOGOUS GRAFTS:

Decalcified bone grafts induce new bone formation and do not appear to be rejected. The new bone formation is accomplished by osteolysis of the graft by means of osteoclastic resorption. This is followed by osteoblastic proliferation and deposition of new bone in the area of the graft. During this study, a total of fourteen homologous decalcified grafts were accepted by the tissues. In eight weeks the grafts were almost totally resorbed and replaced by new bone. The new bone formed was characterized by trabaculae of the same size and shape as

the decalcified grafts. There is no sufficient evidence that the homologous decalcified grafts act as a matrix for new bone formation. The new bone formed had the appearance of dense compact bone similar to that which was removed from the buccal cortical plate of the mandible.

COMPARISON:

The present results suggest that autogenous grafts of bone are more readily accepted. The graft appears to remain viable and is not subjected to osteolytic destruction. New bone bridging the graft to the host bone is apparent within four weeks after implantation. In contrast, the site of the decalcified homologous graft shows osteolytic activity with new bone formation occuring around the grafts. It is possible that, if the autogenous grafts conformed more closely to size of the bony defects into which they were placed, there would have been fewer areas of separation of the graft from the host by fibrous connective tissue. Thus, correction of a bony defect by an autogenous graft should probably require less time. The main disadvantages of autogenous grafting are that it necessitates a second operative site, and that the supply is limited. The decalcified homologous grafts, although not accepted perfectly by the host, appear to provide an excellent means of correcting bone defects. Decalcified homologous grafts can be stored indefinitely and there is no need of a second operation in the same subject. Finally, decalcified homologous grafts are very soft and can be shaped in any form

by a surgical knife. This is difficult to achieve with the much harder autogenous grafts.

Since there was no evidence that the decalcified homologous grafts elicited a transplantation response, the main disadvantage of homologous grafts as reported by Urist,(105) it would be of some interest to investigate further the use of decalcified bone in the management of bony defects and its use for ridge extension, genioplasty, repair of orbital plate in blow out fractures, for management of bony defect in cleft palate cases and in management of infrabony pockets.

SUMMARY

Standardized surgical defects were made on the buccal surface of canine mandibles. Autogenous and decalcified homologous grafts of canine bone were placed in these defects and allowed to heal for periods of from 2-8 weeks.

Histological study revealed that the decalcified homologous bone grafts underwent complete resorption which was followed by new bone formation. The autogenous grafts maintained their viability, were not resorbed, and were accepted by the host tissues. Bone regeneration appeared to be somewhat more rapid in decalcified homologous bone grafts as compared with autogenous grafts.

These studies suggest that decalcified homologous grafts should be studied in more detail, for they could be of use in the treatment of bony defects.

BIBLIOGRAPHY

1. Abbott, L.C. et al.: The Evaluation of Cortical and Cancellous Bone as Grafting Material, J. Bone & Joint Surg. 29:381-414, 1947.

2. Albee, F.H. and Morrison, H.F.: Triple calcium phosphate as stimulation to osteogenesis, Ann. of Surg. 71:32, 1920.

3. Archer, W.H.: Oral Surgery, 809: 1961 W.B. Saunders & Co.

4. Axhausen, G.: Cited in Groves, E.W.: Methods and results of transplantation of bone in the repair of defects caused by injury and disease, Brit. J. Surg. 5:185, 1917.

5. Bang, G. and Urist, M.R.: Induction in excavation chambers in matrix of decalcified dentin, A.M.A. Arch. Surg. 94:781-789, 1967.

6. Barth, A.: Histologische Unter suchungen uber Knochenimplantationen Beitr. Path. Anat. 17:65, 1895.

7. Basset, C.A.L.: Current concepts of bone formation, J. Bone and Joint Surg. 44A:1217-1244, 1962.

8. Beder, O.E. and Eade, G.: An Investigation of Tissue Tolerance to Titanium metal Implants in dogs, Surg. 39:470-473, 1956.

9. Bell, W.H.: Histologic study of heterogenous bone implants in human beings, J. Oral Surg. 17:2, 1959.

10. Bell, W.H.: Resorption characteristics of bone and bone subtitutes, J. of O.S., O.M. and O.P. 17:650-657, 1964.

11. Bellinger, D.H.: Preliminary report on the use of Tantalum in Maxillo-facial and Oral Surgery, J. Oral Surg. 5:108-122, 1947.

12. Bier, A.: Osteoplastische Nekrotomie nebst Bemerkungen uber die an der Kieler Chirurgischen Kliniek Ausgenfuhrten Methoden der Nekrotomie, Arch. Klin. Chir. 43:121, 1892.

13. Bisgard, J.D.: Ossification, The influences of the mineral constituents of bone, Arch. Surg. 33:926, 1936.

14. Blocker, T.G. and Weiss, L.R.: Use of cancellous bone in the repair of defects about the jaws, Ann. Surg. 123:622, 1946.

15. Boyne, P.J.: Treatment of oral bony defects in man with anorganic heterogenous bone, J. of O.S., O.M. and O.P. 11:322, 1958.

16. Bridges, J.B.: Heterotopic ossification in the ischemic kidney of the rabbit, rat and guinea pig, J. Urol. 79:903-910, 1958.

17. Bridges, J.B. and Prichard, J.J.: Bone and cartilage induction, J. Anatomy 92:28-38, 1958.

18. Brown, J.B. and Demere, M.: Establishing a preserved Cartilage bank, Plast. & Recon. Surg. 3:283-293, 1948.

19. Brown, J.B. et al.: Study and use of synthetic materials such as silicone and teflon as subcutaneous prosthesis, Plast. & Recon. Surg. 26:264-279, 1960.

20. Browning, C.W.: Alloplast materials in orbital repair, Am. J. of Opthalmology, V63# 5pt 1:955-962, 1967.

21. Buring, K. and Urist, M.R.: Transfilter bone induction, Clinical Orthopedics 54:235-242, 1967.

22. Bush, L.F.: Use of homogenous bone grafts, J. Bone & Joint Surg. 29:620-628, 1947.

23. Calhoun, N.R. et al.: Effects of Plaster of Paris Implants in surgical defects of mandibular alveolar process of dogs, J. of Oral Surg. 25:122-128, 1967.

24. Campbell, C.J. et al: Experimental study of the fate of bone grafts, J. Bone & Joint Surg. 35A:332-346, 1953.

25. Campbell, H.H.: Surgery of lesions of the Upper Face, Am. J. of Surg. 87:676-687, 1954.

26. Carter, W.W.: Ultimate fate of bone when transplanted into nose for purpose of correcting deformity, Arch. Otol. 15:563, 1932.

27. Charles, B.E. et al.: Osteogenic activity following bone and sponge implantation, J. of Dental Research 43:26-34, 1964.

28. Cohen, B.M.: Antibiotics and intraoral bone grafts, J. Oral Surg. 13:34-43, 1955.

29. Cole, P.P. and Bubb, C.H.: Deformities of the jaws resulting from operation or injury, Brit. Med. J. 1:268-271, 1916.

30. Cole, P.P. and Bubb, C.H.: Bone grafting in ununited fractures of the mandible with special reference to the pedicled graft, Brit. Med. J. 1:67, 1919.

31. Converse, J.M.: Early and late treatment of gunshot wounds of the jaw in French battle casualties in North Africa and Italy, J. of Oral Surg. 3:112, 1945.

32. Converse, J.M. and Campbell, R.M.: Experiences with a bone bank in plastic surgery, Plastic & Recon. Surg. 5:258-260, 1950.

33. Converse, J.M.: Restoration of facial contour by bone grafts introduced through the oral cavity, Plast. & Recon. Surg. 6:295, 1950.

34. Converse, J.M. and Campbell, R.M.: Bone grafts in Surgery of the Face, Surg. Clin. N. Am. 34:375-401, 1954.

35. Deaver, J.B.: Secondary bone implantation by a modification of Senn's method, Medical News V55:714-715, 1889.

36. Dewey, A.R. and Moore, J.W.: Mandibular repair after radical resection, J. Oral Surg. 20:34-40, 1962.

37. Dick, I.L.: Iliac bone transplantation, Preliminary observations, J. Bone & Joint Surg. 28:1-13, 1946.

38. Dresser, W.J. and Clark, B.H.: Study of tissue response to Polyvinyl resin sponge implants in the jaws of dogs, J. of Oral Surgery 17:3-13, 1959.

39. Du Bouchet, C.W.: New method of bone grafting for pseudoarthrosis of the mandible, Bull. et. mem. Soc. Chir. de Paris 43:1328, 1917.

40. Gerry, R.C. and Giotta, P.J.: Role of Tantalum in reconstruction of orbitomalar and microgenic deformities, J. of O.S. 15:11-23, 1957.

41. Ghormley, R.K. and Stuck, W.G.: Experimental bone transplantation with special reference to the effect of decalcification, Arch. Surgery 28:742-770, 1934.

42. Gillies, H. and Kristensen, H.K.: Ox cartilage in Plastic Surgery, Brit. J. Plast. Surg. 4:63-73, 1951.

43. Goldhaber, P.: Osteogenetic induction across millipore filters in vivo, Science 133:2065-2067, 1961.

44. Goldhaber, P: Calcification within diffusion chambers containing bone isografts, Clin. Orthopedics 25:204-211, 1962.

45. Goldman, H. and Bloom, A.: Personal communication.

46. Gordon, S.: The role of cancellous bone in plastic surgery, Surg. 20:202, 1946.

47. Gould, B.: Via personal communication.

48. Grindlay, J.H. and Waugh, J.M.: Plastic sponge which acts as a framwork for living tissue, Arch. Surg. 63:288-297, 1951.

49. Groves, E.W.: Methods and results of transplantation of bone in the repair of defects caused by injury and disease, Brit. J. of Surgery 5:185, 1917.

50. Ham, A and Gordon, S.: The origin of bone that forms in association with cancellous chips transplanted into muscle, Brit. J. Plastic Surgery 5:154, 1952.

51. Ham, A.W.: Some histophysiological problems peculiar to calcified tissues, J. Bone & Joint Surg. 34A:701, 1952.

52. Hayward, J.R. and Roffinella, J.P.: Iliac autoplasty for repair of mandibular defects, J. Oral Surg 13:44, 1955.

53. Healy, M.J. et al.: The use of acrylic implants in one stage of reconstruction of the mandible, Surg., Gynec. and Obst. 98:395-406, 1954.

54. Herring, G.M.: Chemistry of bone matrix, Clin. Orthopedics 36:169-183, 1964.

55. Hinds, E.C.: Kruger's Oral Surgery, 467-503, 2nd edition, The C.V. Mosby Co., St. Louis, Mo., 1964.

56. Hirakawa, M. and Uji, T.: A new concept of bone defect treatment in surgical procedures on jaw bone, J. of O.S., O.M. and O.P. 18:149-159, 1964.

57. Huebsch, R.F. and Wickstrom, O.W.: The repair of orally contaminated bone defects with cancellous bone chips, J. of O.S., O.M. and O.P. 4:1127-1131, 1951.

58. Huggins, C.B.: The formation of bone under the influence of epithelium of the urinary tract, Arch. Surg. 22:377, 1931.

59. Huggins, C.B. et al.: Experiments on the theory of osteogenesis: The influence of local calcium deposits on ossification: The osteogenic stimulus of epithelium, Archives of Surgery 32:915-931, 1936.

60. Inclan, A.: The use of preserved bone graft in Orthopedic Surgery, J. Bone & Joint Surg. 24:81-96, 1942.

61. Ivy, R.H.: Bone grafting for restoration of defects of the mandible, Plast. & Recon. Surg. 7:333-341, 1951.

62. Kazanjian, V.H.: Spontaneous regeneration of bone following excision of section of the mandible, Am. J. Orth. & Oral Surgery 32:242, 1946.

63. Kiehn, C.L. and Grino, A.: Iliac bone grafts replacing Tatalum plates for gunshot wounds of skull, Am. J. Surg. 85:395-400, 1953.

64. Kushner, A.: Evaluation of Wolff's law of bone formation, J. Bone and Joint Surg. 22:589-596, 1940.

65. Leriche, R. and Policard, A.: Fundamental principles in pathology of bone, Surg., Gynec, and Obst. 43:308, 1926.

66. Le Veen, H.H. and Barberio, J.R.: Tissue reaction to Plastic used in Surgery with special reference to Teflon, Annals of Surg. 129:74-84, 1949.

67. Macewen, W.: Observations concerning transplantation of bone, Proc. Roy. Soc. 32:232-247, 1881.

68. Macomb, R.K. et al.: Polyurethane foam (Ostamer), its use in experimental animals and the investigation of tissue reactions, Surgical Forum II:454-456, 1960.

69. Marino, H. et al.: Immediate reconstruction of the lower jaw following surgical excision of large tumors, Plast. & Recon. Surg. 4:36, 1949.

70. Mc Indoe, A.H.: Surgical and dental treatment of fracture of upper and lower jaws in wartime, Proc. Roy. Soc. Med. 34:267, 1941.

71. Mc Williams, C.A.: The treatment of bony defects of the lower jaw, Ann. Surg. 65:283, 1917.

72. Miller, A.G.: A case of bone grafting with decalcified bone chips, Lancet 2:618, 1890.

73. Moss, M.L.: Extraction of osteogenic induction factor from bone, Science 127:755, 1958.

74. Mowlem, R.: Bone and cartilage transplants, their use and behavior, Brit. J. Surg. 29:182-193, 1941.

75. Mowlem, R.: Cancellous chip bone graft, Lancet 2:746, 1944.

76. Murray, G. et al.: Experimental and clinical study of new growth of bone in a cavity, Am. J. Surg. 93:385-387, 1957.

77. Nageotte, J.M.: Osteogenese dans les greffes dos mort, C.R. Acad. Sci. 171:280, 1920.

78. Nageotte, J.: Osteogenese dans les greffes de cartilage mort, C.R. Acad. Sci. 169:737-740, 1919.

79. New, G.B. and Erich, J.B.: Bone grafts to the mandible, Am. J. of Surg. 63:153, 1944.

80. Oldfield, M.C.: Iliac hernia after bone grafting, Lancet 1:810, 1945.

81. Ollier, L.: Traite experimental et clinique de la regeneration des os et de la production artificielle du tissu osseux, Paris 1867, Victor Mason et Fils.

82. Orell, S.: Surgical bone grafting with Os Purum, Os Novum and Boiled bone, J. Bone & Joint Surg. 19:873, 1937.

83. Parkes, M.L.: Chin implants with a newer plastic compound, Arch. Otolarying. 75:429-436, 1962.

84. Peer, L.: The fate of autogenous human bone grafts, Brit. J. Plastic. Surg. 3:233, 1950-1951.

85. Peer, L.A. and Walker, J.C.: The behavior of autogenous human tissue grafts, Plact. & Recon. Surg. 7:73-84, 1951.

86. Penhale, K.W.: Acrylic resens as an implant for correction of facial deformities, Arch. Surg. 50:233-239, 1945.

87. Pettier, L.F.: The use of Plaster of Paris to fill defects in bone, Clinical Orthopedics 21:1-29, 1961.

88. Polettini, B.: Su neoformazioni cartilaginee ed osee determinate da innesti di farmmenti di cartilagine e dosso fissati, Arch. Ital. Chir. 6:179, 1922.

89. Post, R.H. et al.: Bone grafts in diffusion chambers, Clinical Orthopedics 44:265-270, 1966.

90. Quereau, J.V.D. and Souder, B.F.: Teflon implant to elevate the eye in depressed fracture of the orbit, Arch. Ophthal. 55:685-691, 1956.

91. Ray, R.D. and Holloway, A.: Bone implants, preliminary report of an experimental study, J. Bone & Joint Surg. 39A:1119, 1957.

92. Ray, R.D. and Sabet, T.Y.: Bone grafts: Cellular survival versus induction, J. Bone & Joint Surg. 45A:337, 1963.

93. Reynolds, F.C. and Oliver, D.R.: Experimental evaluation of homogenous bone grafts, J. Bone & Joint Surg. 32A:283, 1950.

94. Reynolds, F.C. et al.: Clinical evaluation of merthiolate bone bank and homogenous bone grafts, J. Bone & Joint Surg. 33A:873, 1951.

95. Rosenberg, N. et al.: The use of bone milled in kitchen blender, Surg., Cynec. and Obst. 101:545-557, 1955.

96. Rowe, M.L. and Killey, H.C.: Fractures of the facial skeleton, Baltimore, Md., Williams & Wilkins Co., 1955.

97. Salvatore, J.E. and Mandarino, M.P.: Polyurethane polymer, Ann. Surg. 149:107, 1959.

98. Selle, R. Urist, M.R.: Calcium deposits and new bone formation in muscle in rabbits, J. Surg. Res. 1:132-142, 1961.

99. Shira, R.B.: Treatment of non-union of mandibular fractures by intra-oral insertion of homogenous bone chips, J. Oral Surg. 13:306-316, 1955.

100. Speer, D.P. and Urist, M.R.: Experimental intracellular calcification of muscle, Clin. Orthopedics 39:213, 1965.

101. Straith, C.L. and Slaughter, W.B.: Grafts of preserved cartilage in restorations of facial contour, J.A.M.A. 116:2008-2013, 1941.

102. Stuteville, O.H. and Lanfranchi, R.P.: Surgical Reconstruction of the Temporomandibular Joint, Am. J. Surg. 90:940-950, 1955.

103. Thoma, K.H.: Oral Surgery, 4th edition 1196-1223, St. Louis, Mo., The C.V. Mosby Co., 1963.

104. Urist, M.R. and Mclean, F.C.: Osteogenetic potency and new bone formation by induction in transplants to the anterior of the eye, J. Bone & Joint Surg. 34A:443-470, 1952.

105. Urist, M.R. et al.: The function of the donor tissue in experimental operations with radioactive bone grafts, Ann. Surgery 147:129-145, 1958.

106. Urist, M.R.: Bone formation by autoinduction, Science 150:893-898, 1965.

107. Urist, M.R.: Origins of current ideas about calcification, Clinical Orthopedics 44:13-39, 1966.

108. Urist, M.R. and Dowell, T.: The newly deposited mineral in cartilage and bone matrix, Clin. Orthopedics 50:291-308, 1967.

109. Urist, M.R. and Abernethy, J.: Effects of calcium ion upon structure and calcifiability of tendon, Clinical Orthopedics 51:255-274, 1967.

110. Urist, M.R. et al.: The bone induction principle, Clinical Orthopedics 53:243-283, 1967.

111. Van de Putte, K.A. and Urist, M.R.: Experimental mineralization of collagen sponge and decalcified bone, Clinical Orthopedics 40:48-56, 1965.

112. Van de Putte, K.A. and Urist, M.R.: Osteogenesis in the interior of intramuscular implants of decalcified bone matrix, Clinical Orthopedics 43:257-270, 1965.

113. Venable, C.S. et al.: The effect on bone of the presence of metals based upon electrolysis, Ann. Surg. 105:917-938, 1937.

114. Weinstein, I. et al.: Resection and reconstruction of mandible for central hemangioma, Oral Surgery, Oral Medicine and Oral Pathology 16:2, 1963.

115. Wilson, P.D.: Experiences with a bone bank, Ann. Surgery 126:932, 1947.

116. Yeomans, J.D. and Urist, M.R.: Bone induction by decalcified dentin implanted into oral, osseous and muscle tissues, Arch. Oral Biology 12:999-1006, 1967.

APPENDIX

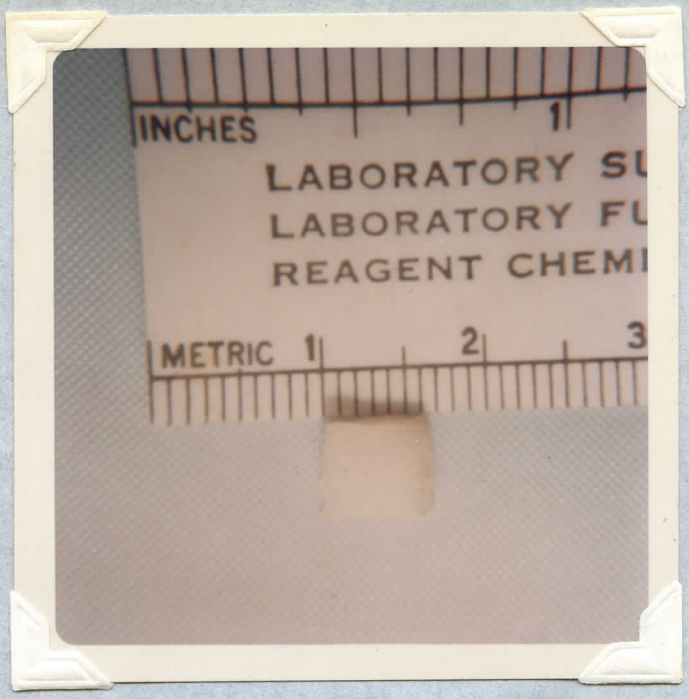

Figure 1: Standard bone graft of 6x5x3mm. size.

Figure 2: Injection of Pentobarbital Sodium demonstrating anaesthetic technic.

Figure 3: Five bone defects on the buccal surface of the mandible of 6x5x3mm. size.

Figure 4: Two autogenous, two decalcified homologous grafts are in position and the fifth defect left as a control. D.G. - Decalcified Grafts; A.G. - Autogenous Grafts.

Figure 5: Postoperative, demonstrating sutures in position. E - Endotracheal tube.

Figure:3

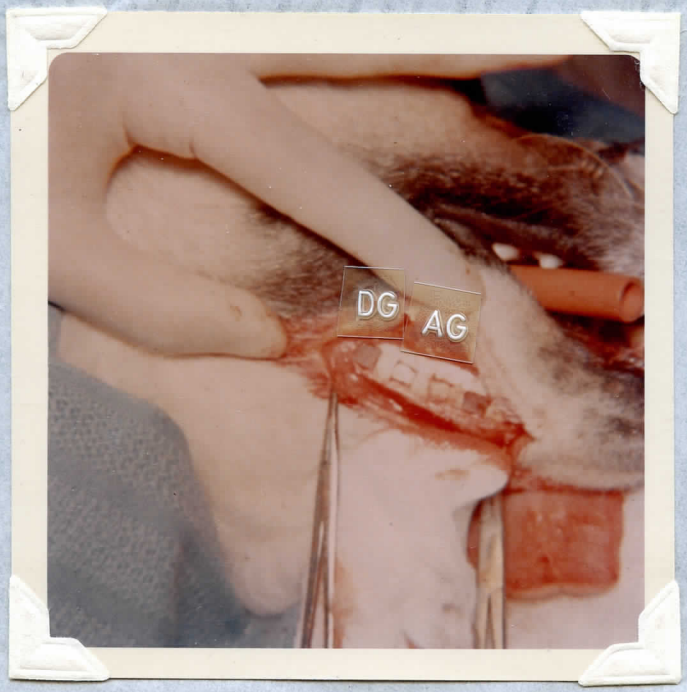

Figure:4

Figure:5

Figure 6: Specimen six weeks postoperatively, demonstrating grafts in position.

Figure 7: Postoperative radiograph of six weeks specimen, showing autogenous grafts radiopaque, decalcified grafts and control radiolucent in appearance.

C - Control; D - Decalcified grafts; A- Autogenous grafts.

Figure: 6

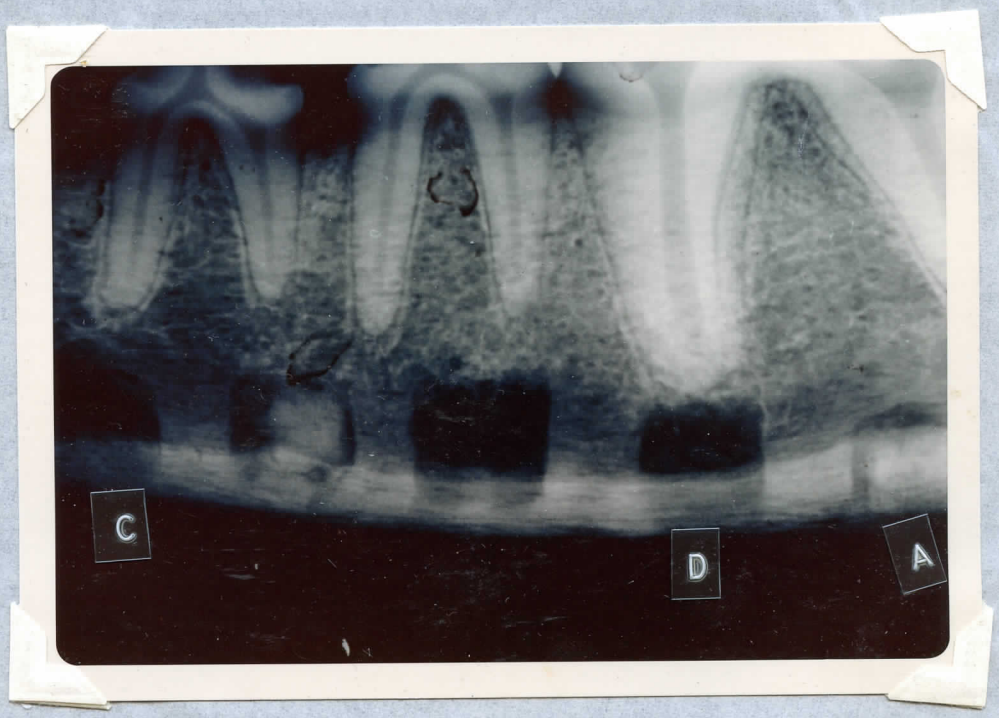

Figure: 7

Figure 8: Autogenous graft two weeks specimen.
Hematoxylin and Eosin stain, magnification 10X
Photomicrograph demonstrating graft surrounded by fibrous connective tissue. H.B. - Host bone; F.C.T. - Fibrous connective tissue; A.G. - Autogenous graft.

Figure 9: Autogenous graft two weeks specimen.
Hematoxylin and Eosin stain, magnification 50X
Photomicrograph showing capillaries in the fibrous matrix, which is present between the graft and bone defect. H.B. - Host bone; A.G. - Autogenous graft.

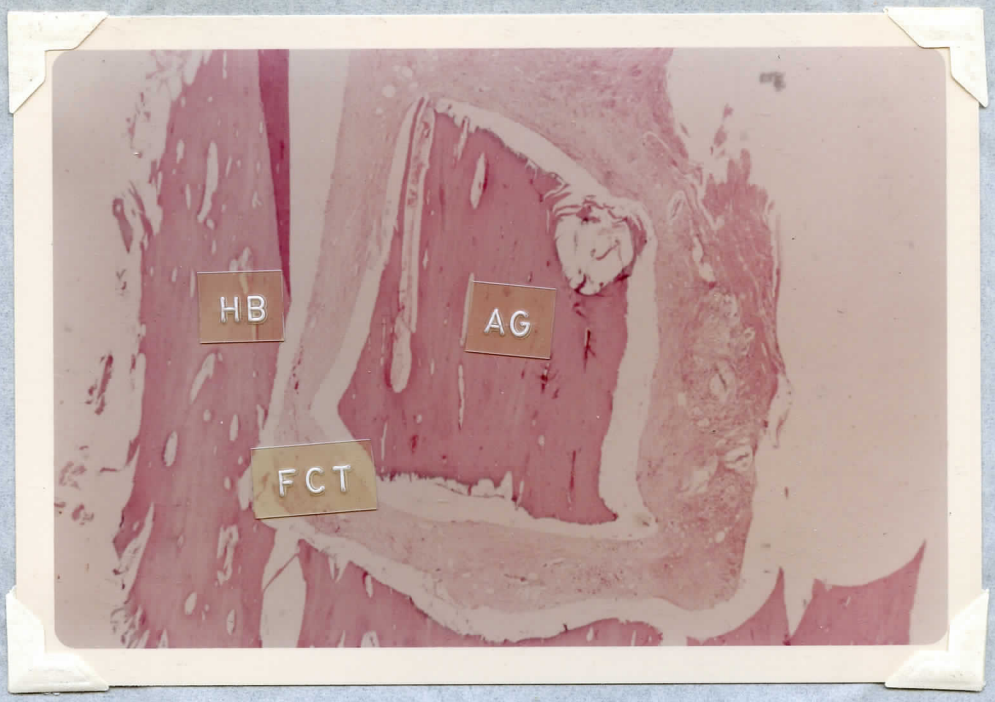

Figure: 8

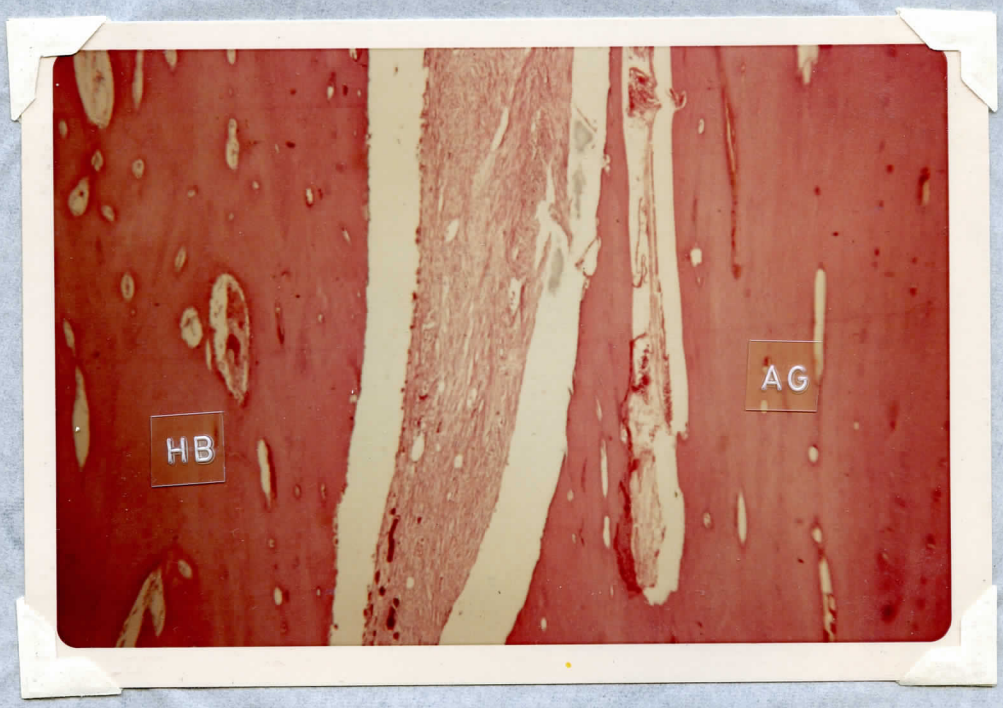

Figure: 9

Figure 10: Autogenous graft two weeks specimen.
Hematoxylin and Eosin stain, magnification 100X
Photomicrograph depicting viability of the graft, however empty space is present between the graft and fibrous matrix. A.G. - Autogenous graft; E.S. - Empty space; F.C.T. - Fibrous connective tissue.

Figure 11: Autogenous graft two weeks specimen.
Hematoxylin and Eosin stain, magnification 435X
Photomicrograph showing viability of the graft by presence of numerous osteocytes and a blood vessel. O.C. - Osteocyte; B.V. - Bloodvessel; H.C. - Haversian canal.

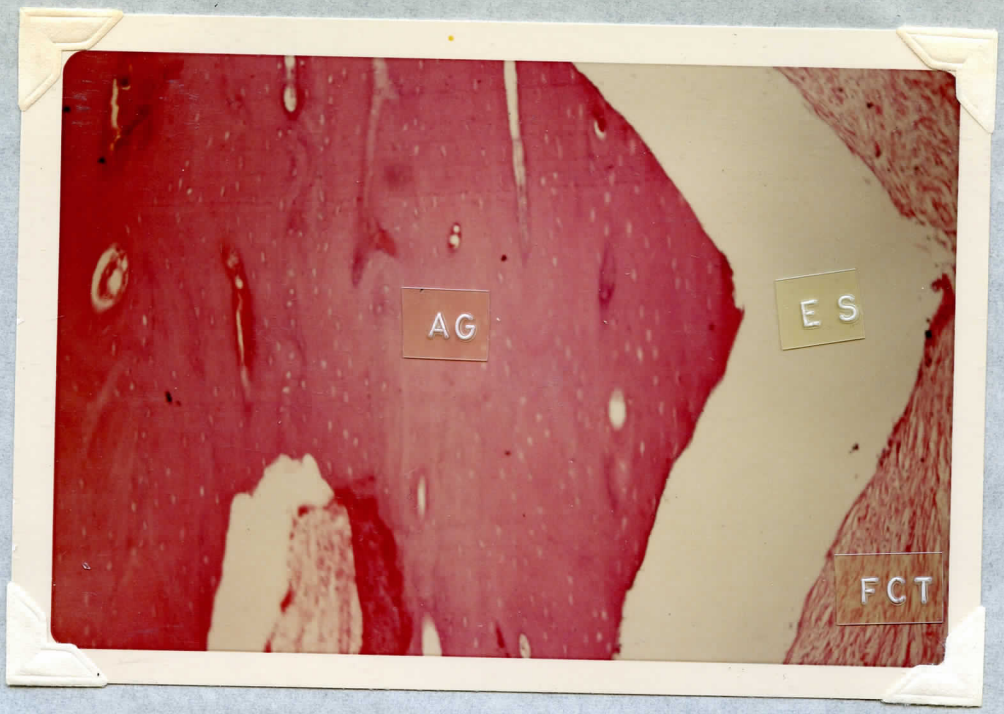

Figure: 10

Figure: 11

Figure 12: Decalcified Homologous graft two weeks specimen. Hematoxylin and Eosin stain, magnification 10X Photomicrograph showing the graft separated from the host bone by fibrous tissue. H.B. - Host bone; D.G. - Decalcified graft; F.C.T. - Fibrous connective tissue.

Figure 13: Decalcified Homologous graft two weeks specimen. Hematoxylin and Eosin stain, magnification 50X Photomicrograph showing a non viable decalcified graft; notice the formation of thick trabeculae on the surface of the host bone.

D.G. - Decalcified graft; E.S. - Empty space; H.B. - Host bone; F.C.T. - Fibrous connective tissue.

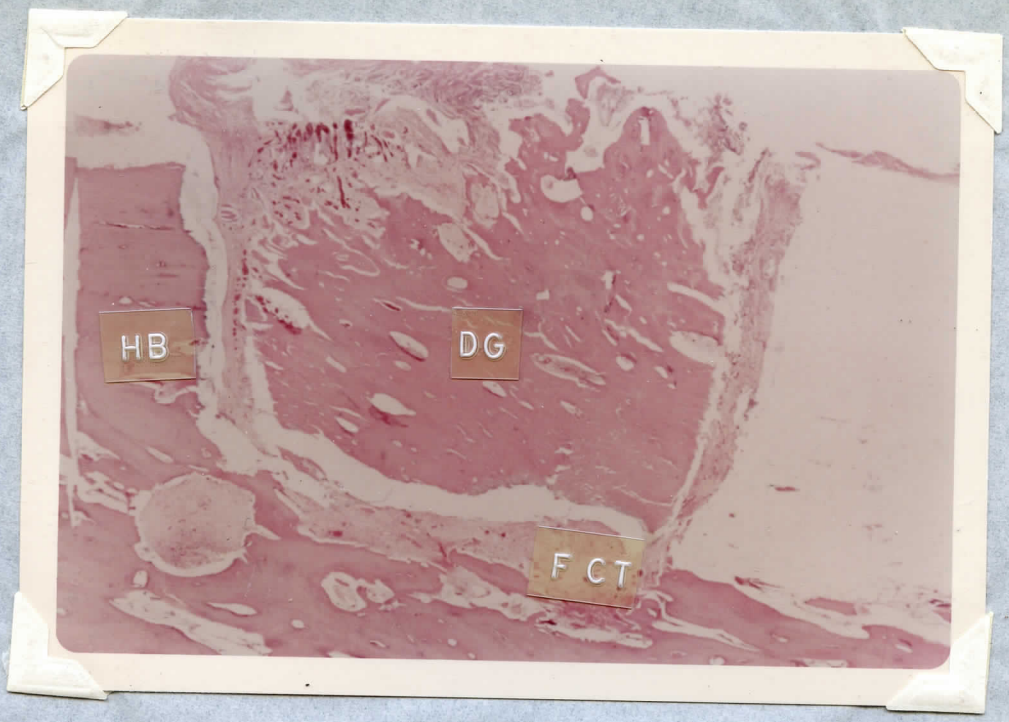

Figure: 12

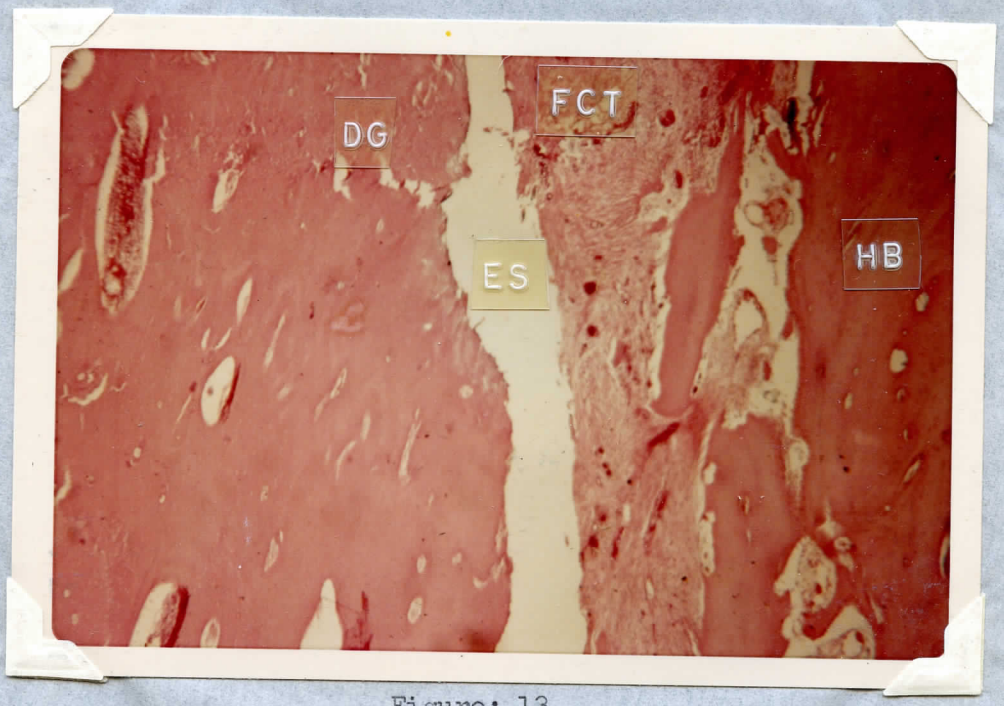

Figure: 13

Figure 14: Decalcified Homologous graft two weeks specimen. Hematoxylin and Eosin stain, magnification 100X Photomicrograph showing empty space between the graft and fibrous connective tissue which is rich with new blood vessels. D.G. - Decalcified graft; E.S. - Empty space; F.C.T. - Fibrous connective tissue; B.V. - Blood vessel.

Figure 15: Decalcified Homologous graft two weeks specimen. Hematoxylin and Eosin stain, magnification 435X Photomicrograph showing an empty lacunae in a non viable graft. E.L. - Empty lacunae.

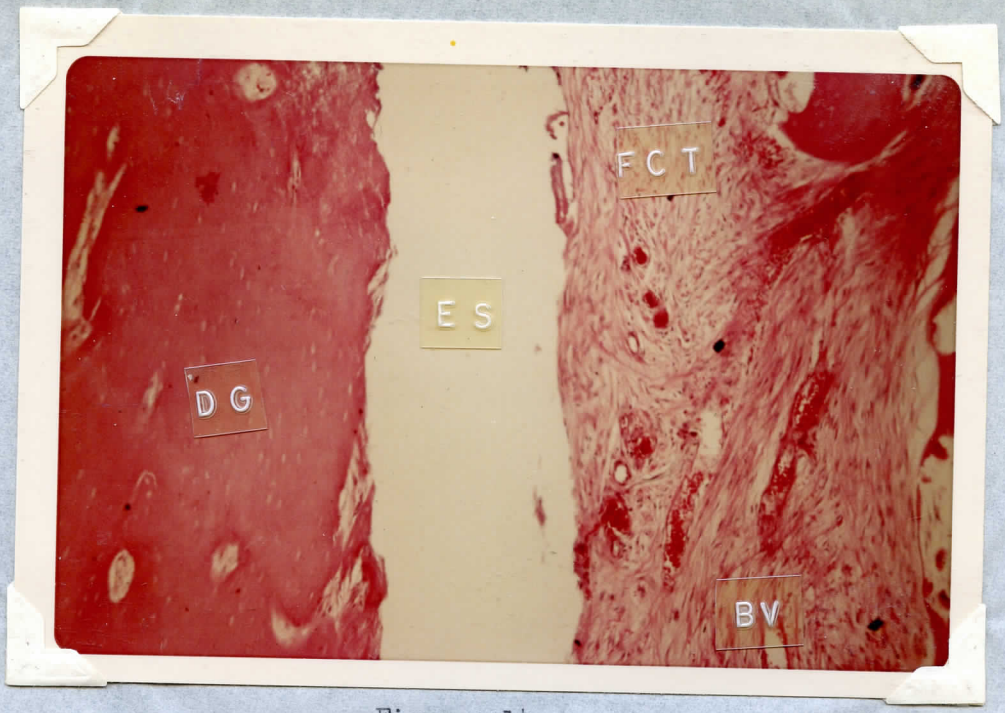

Figure: 14

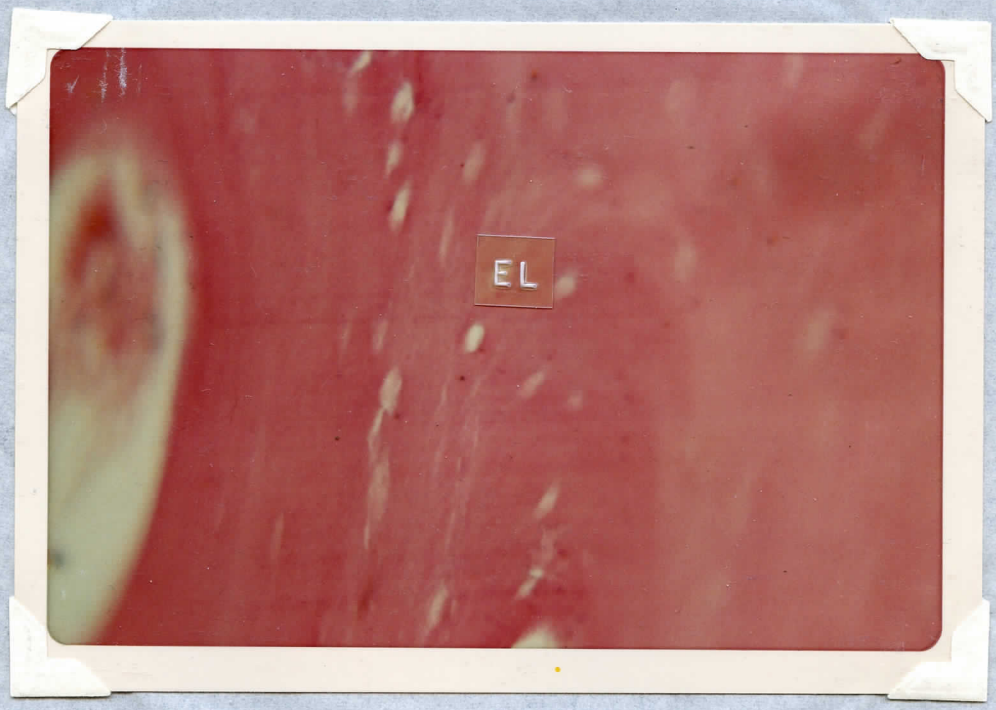

Figure: 15

Figure 16: Control group two weeks specimen.

Hematoxylin and Eosin stain, magnification 10X

Photomicrograph demonstrating formation of osteoid tissue along the bony defect, however fibrous stroma is filling the bone defect. H.B. - Host bone; N.B. - New bone.

Figure 17: Control group two weeks specimen.

Hematoxylin and Eosin stain, magnification 50X

Photomicrograph showing formation of osteoid tissue, new blood vessels and fibrous connective tissue.

H.B. - Host bone; N.B. - New bone; F.S. Fibrous stroma.

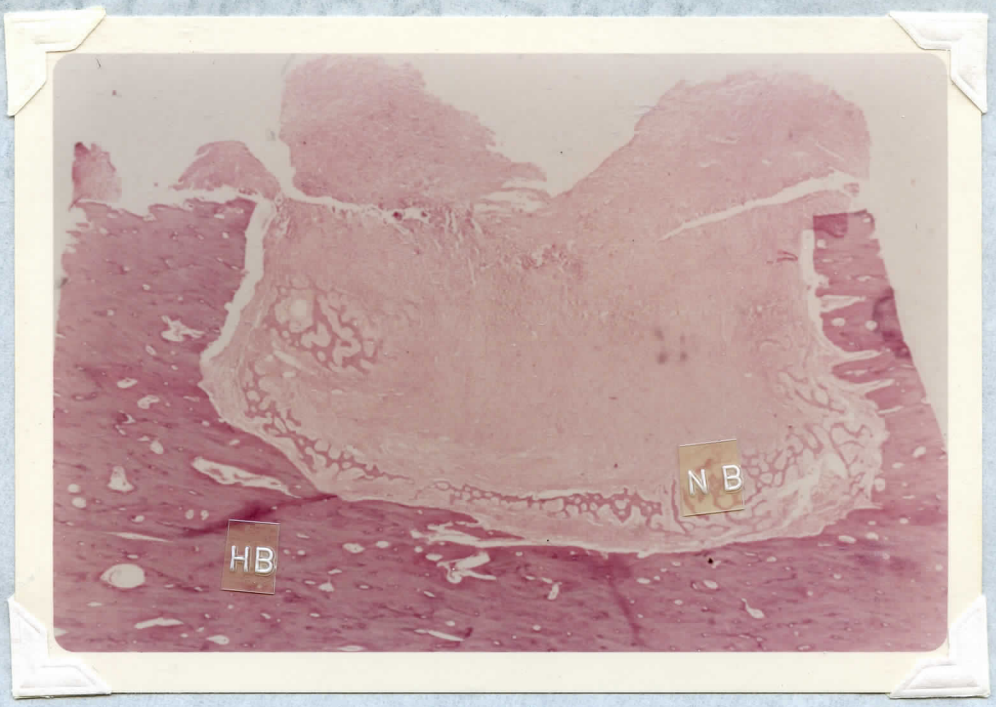

Figure: 16

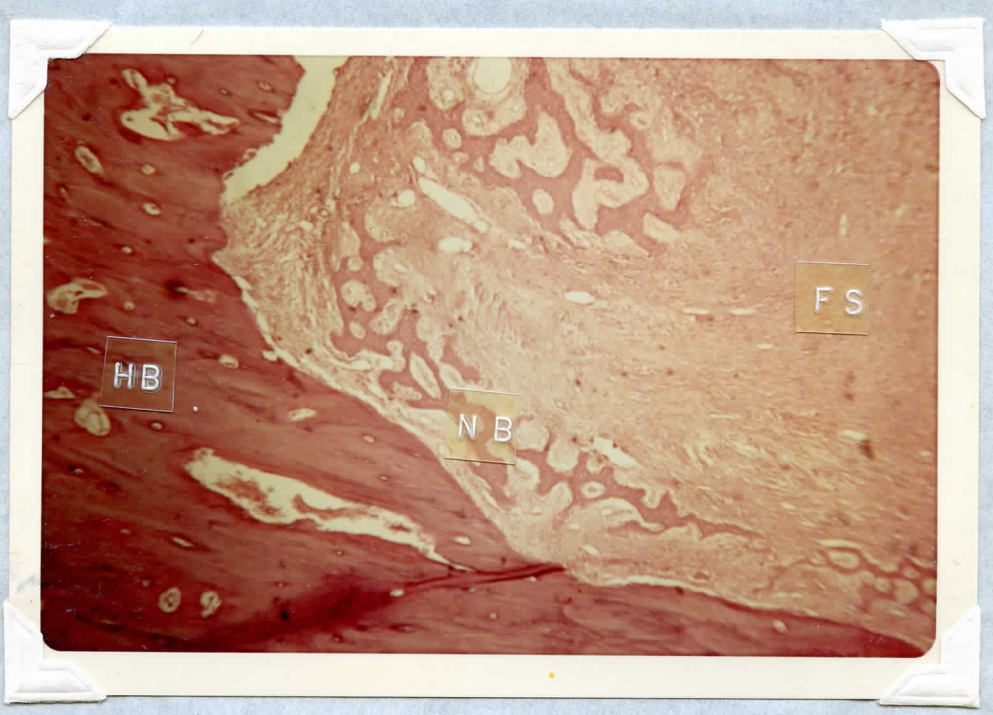

Figure: 17

Figure 18: Control group two weeks specimen.

Hematoxylin and Eosin stain, magnification 100X

Photomicrograph demonstrating osteoblasts lining the new bony spicules and the base of the bone defect. New blood vessels are seen in the fibrous connective tissue.

H.B. - Host bone; N.B.- New bone; B.V. - Blood vessel; C.T. - Connective tissue.

Figure 19: Control group two weeks specimens.

Hematoxylin and Eosin stain, magnification 435X

Photomicrograph demonstrating new capillaries and fibroblasts in fibrous stroma.

B.V. - Blood vessel

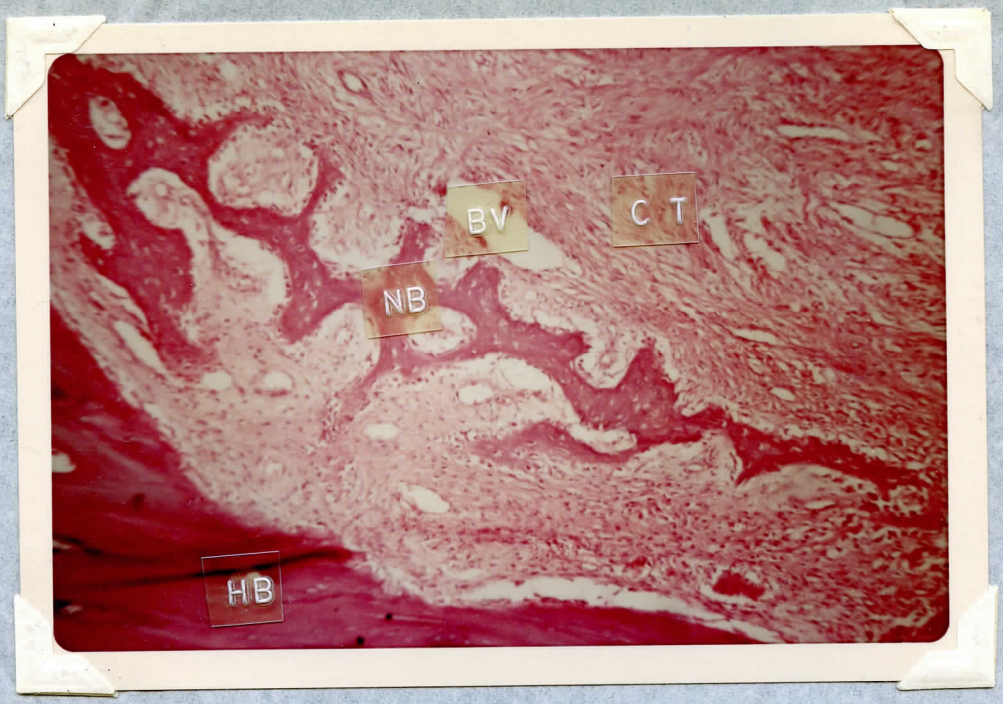

Figure: 18

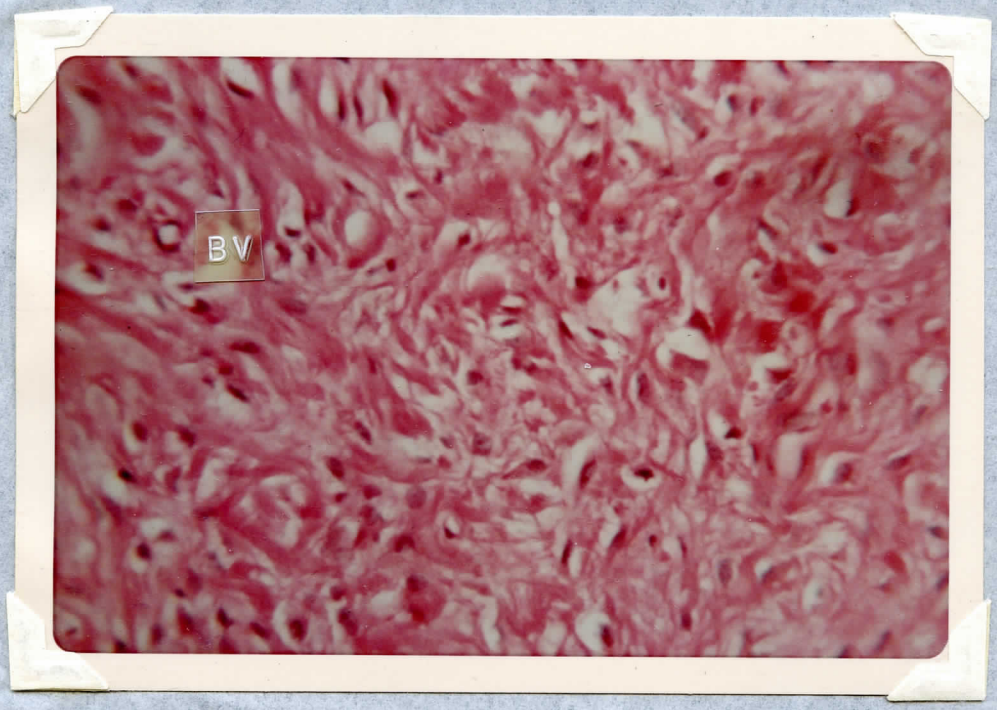

Figure: 19

Figure 20: Autogenous graft four weeks specimen.
Hematoxylin and Eosin stain, magnification 50X
Photomicrograph demonstrates early union of graft to the host bone in one area. Notice the amount of fibrous tissue and blood vessels between the graft and the host bone. H.B. - Host bone; A.G. - Autogenous graft; F.C.T. - Fibrous connective tissue.

Figure 21: Autogenous graft four weeks specimen.
Hematoxylin and Eosin stain, magnification 100X
Photomicrograph showing union of graft to the host bone by thick trabeculae and notice loose areolar tissue containing blood vessels. B.V. - Blood vessel; P. - Periosteum; A.G. - Autogenous graft; H.B. - Host bone.

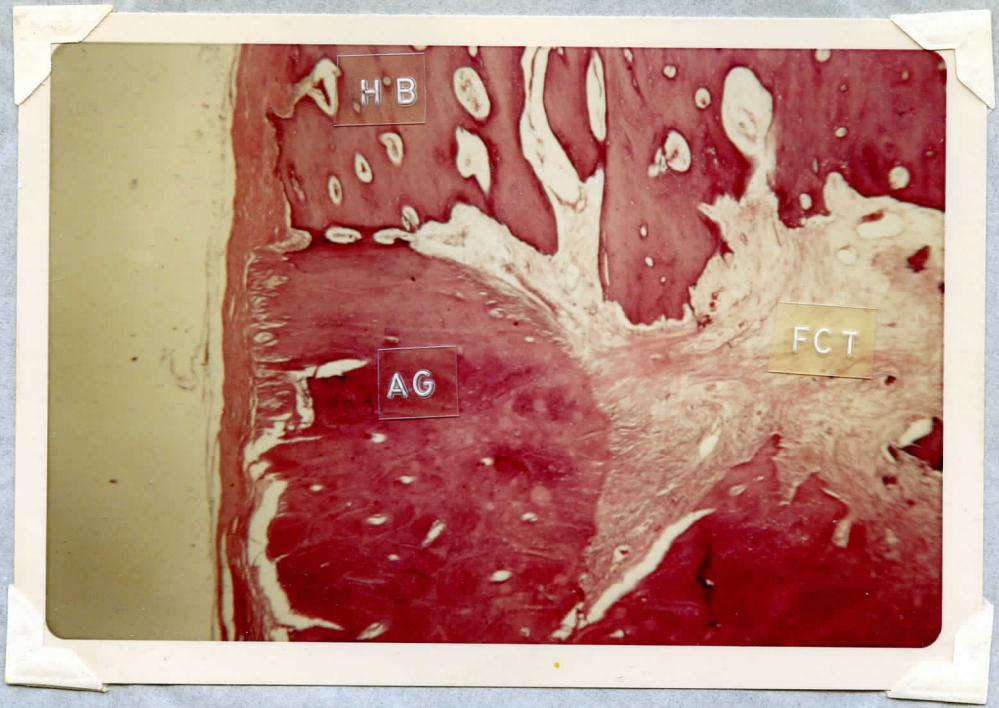

Figure: 20

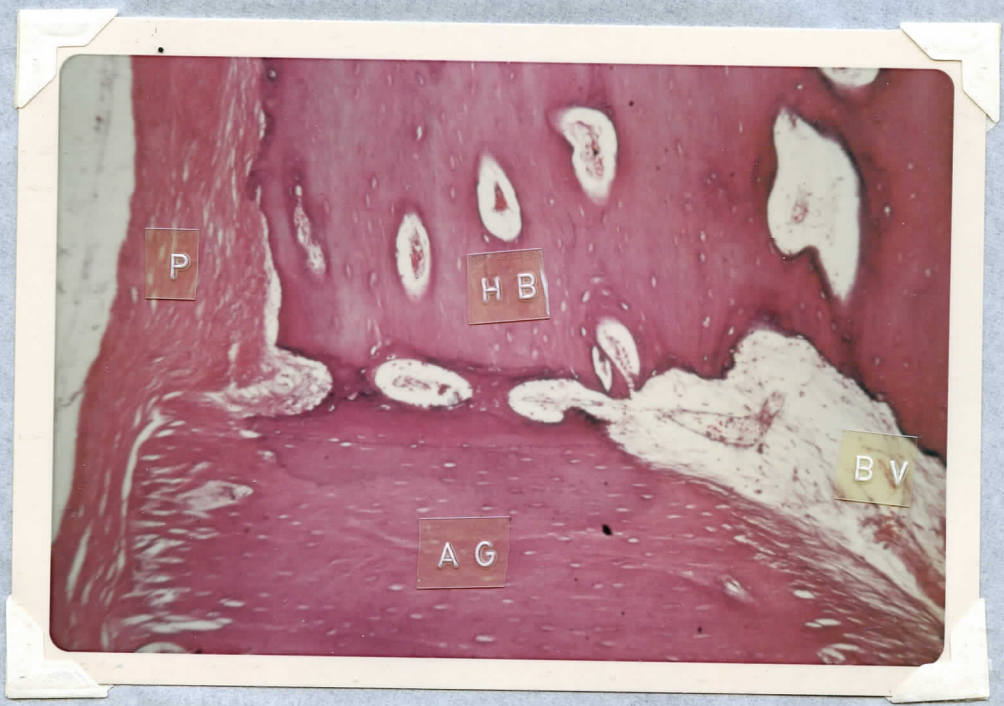

Figure: 21

Figure 22: Autogenous graft four weeks specimen.
Hematoxylin and Eosin stain, magnification 435X
Photomicrograph demonstrating osteocytes in the new bone which connects the graft to the host bone. Notice osteoblasts lining the surface of new bone.
A.G. - Autogenous graft; O.C. - Osteocyte; B.U. - Bony union.

Figure 23: Decalcified Homologous graft four weeks specimen.
Hematoxylin and Eosin stain, magnification 10X
Photomicrograph depicting new bone spicules and fibrous stroma between the graft and the host bone.
D.G. - Decalcified graft; F.S. - Fibrous stroma; N.B. - New bone; H.B. - Host bone.

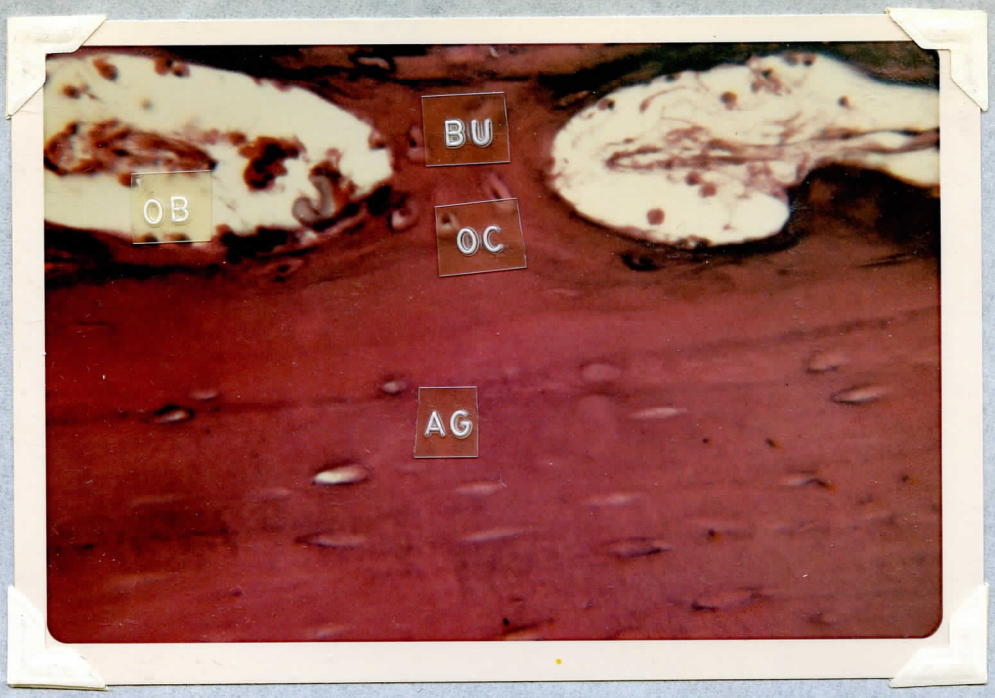

Figure: 22

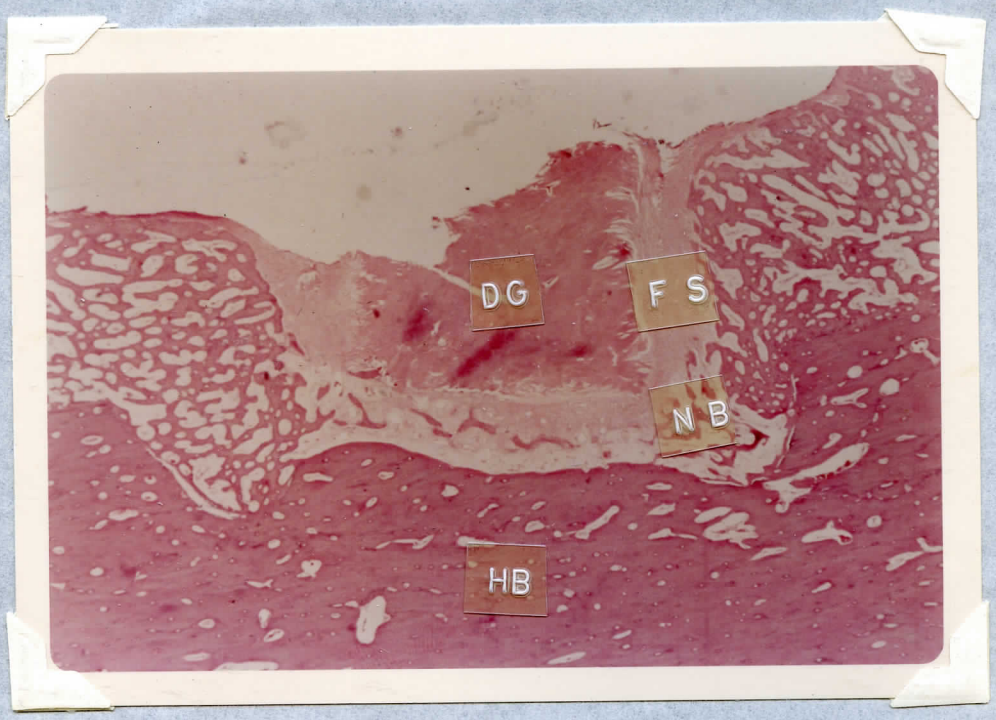

Figure: 23

Figure 24: Decalcified Homologous graft four weeks specimen. Hematoxylin and Eosin stain, magnification 50X Photomicrograph shows bone spicules and capillaries in the fibrous stroma. Notice the presence of giant cells along the margin of decalcified bone graft. D.G. - Decalcified graft; F.S. - Fibrous stroma; N.B. - New bone; H.B. - Host bone.

Figure 25: Decalcified Homologous graft four weeks specimen. Hematoxylin and Eosin stain, magnification 100X Photomicrograph demonstrating presence of numerous capillaries and trabeculae in fibroblastic connective tissue. Notice the presence of giant cells along the margins of acellular graft. G.C. - Giant cell; D.G. - Decalcified graft; B.V. - Blood vessel; F.S. - Fibrous stroma; N.B. - New bone.

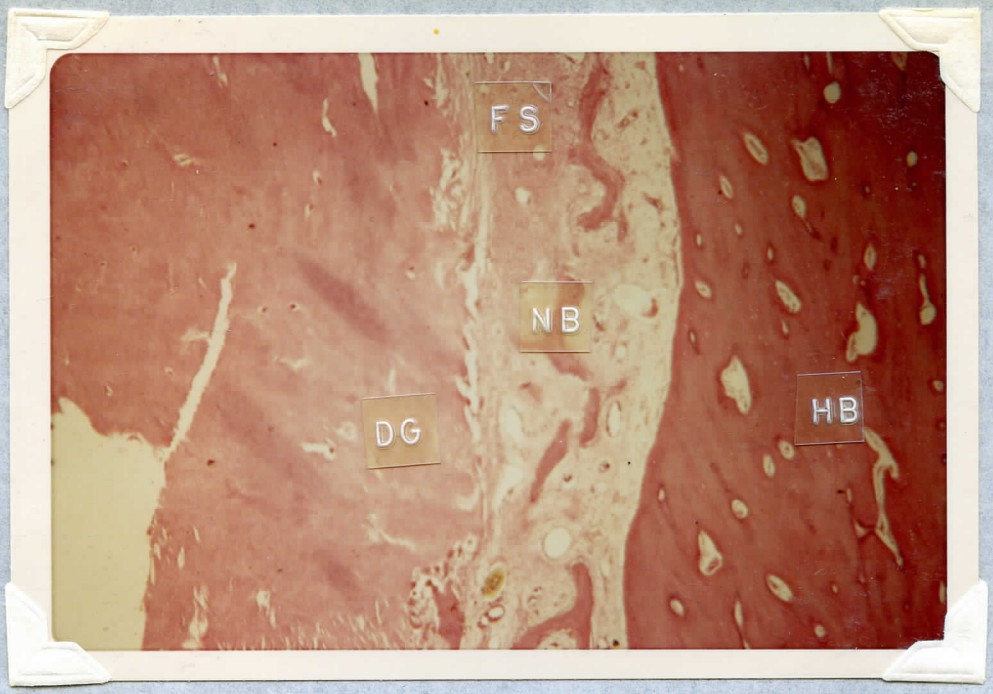

Figure: 24

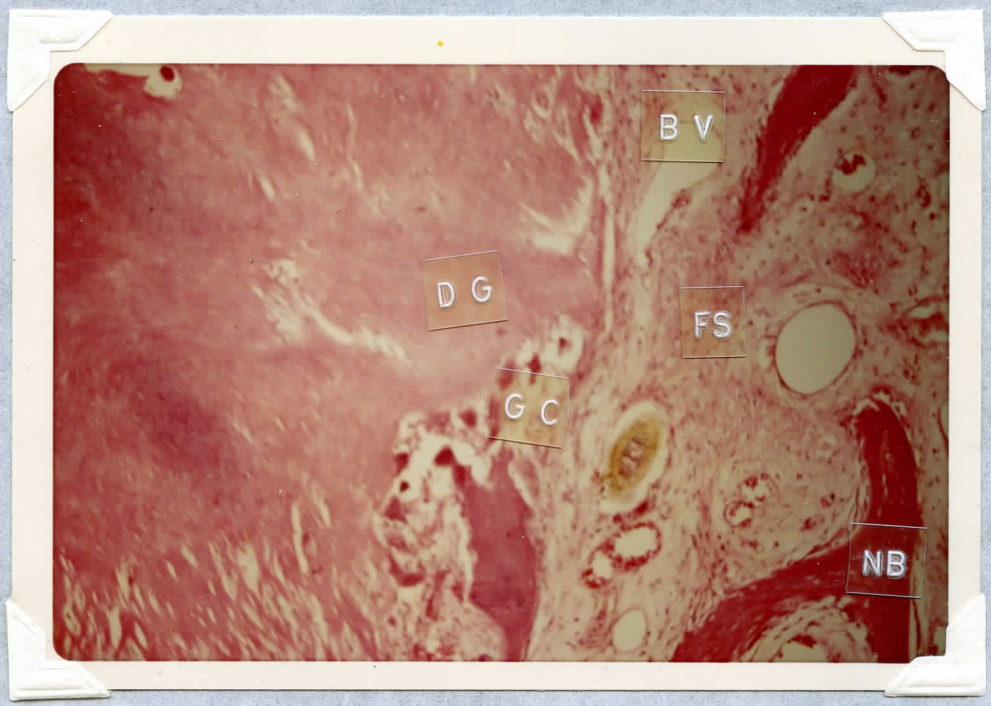

Figure: 25

Figure 26: Decalcified Homologous graft four weeks specimen. Hematoxylin and Eosin stain, magnification 435X Photomicrograph demonstrates the presence of numerous multinucleated giant cells along the margins of acellular bone graft. D.G. - Decalcified graft; G.C. - Giant cell.

Figure 27: Control group four weeks specimen. Hematoxylin and Eosin stain, magnification 10X Photomicrograph shows obliteration of bony defect by new bone, blood vessels and fibrous stroma. H.B. - Host bone; N.B. - New bone; F.S. - Fibrous stroma.

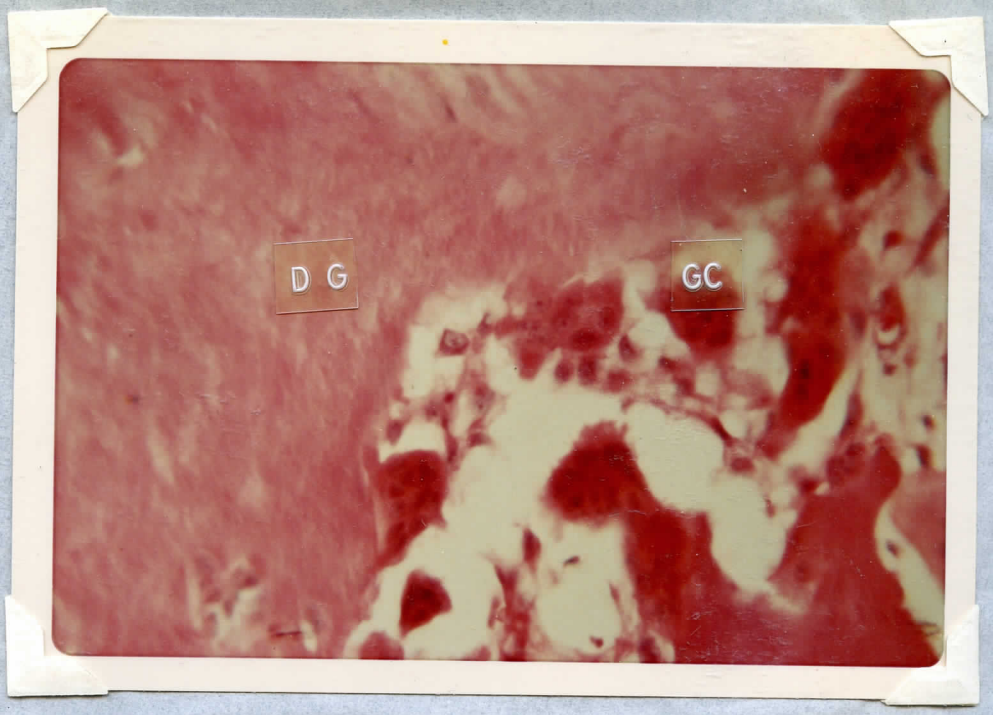

Figure: 26

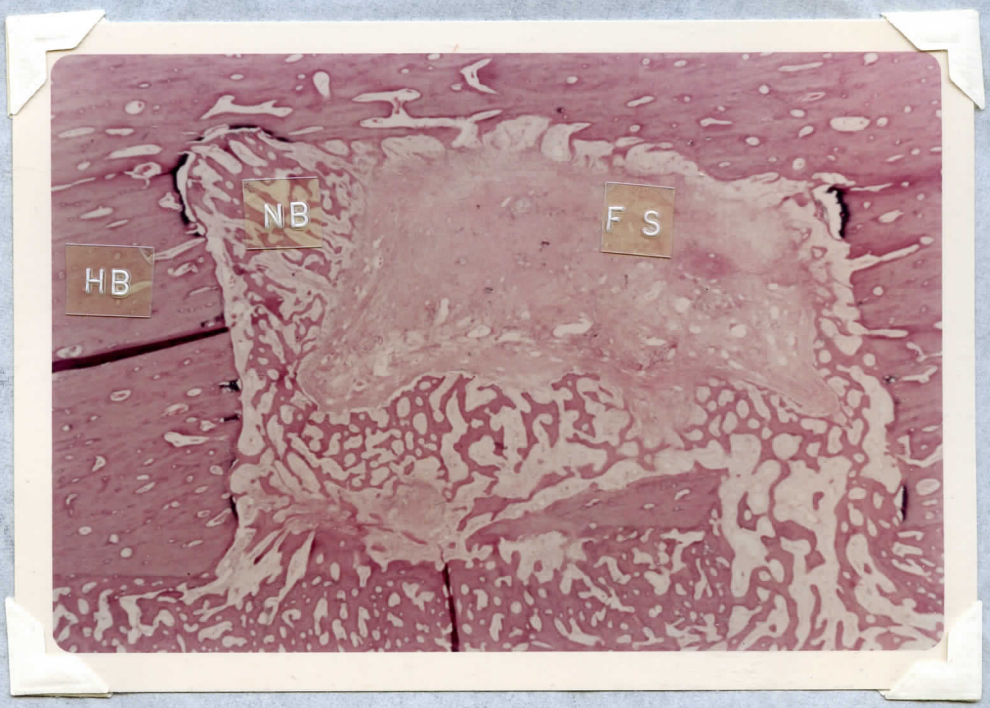

Figure: 27

Figure 28: Control group four weeks specimen.
Hematoxylin and Eosin stain, magnification 50X
Photomicrograph demonstrating trabecular pattern along the host bone. Notice numerous blood vessels in the fibrous connective tissue. H.B. - Host bone; N.B. - New bone; F.S. - Fibrous stroma.

Figure 29: Control group four weeks specimen.
Hematoxylin and Eosin stain, magnification 100X
Photomicrograph showing new bone formation on the host bone as well as in the bone defect. Notice the amount of new capillaries in the dense fibroblastic stroma. H.B. - Host bone; N.B.- New bone; F.S. - Fibrous stroma.

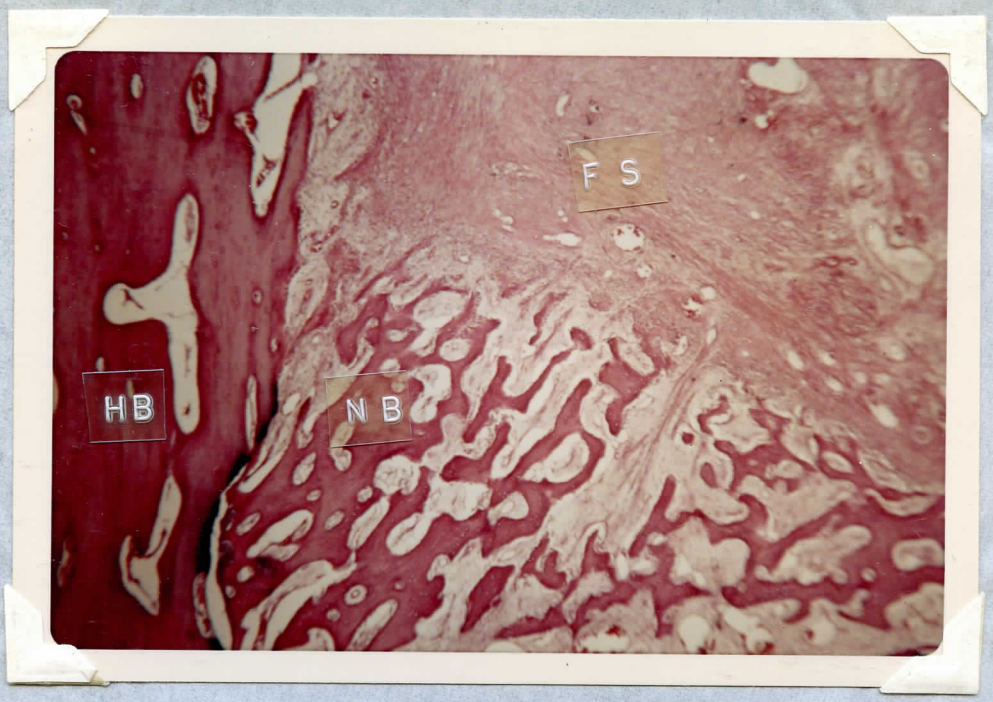

Figure: 28

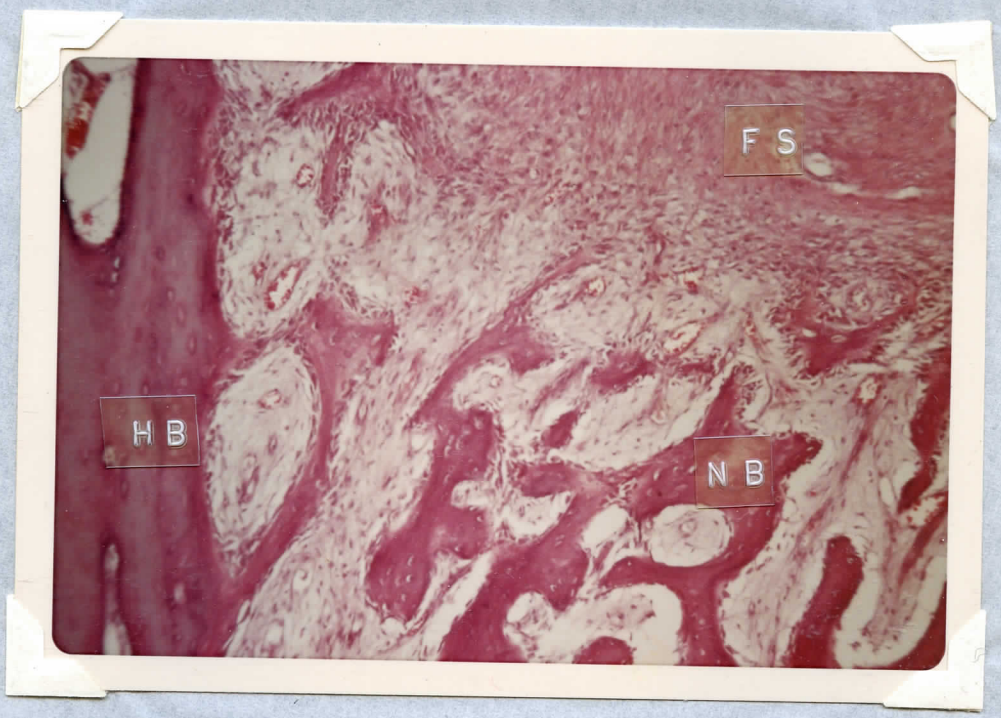

Figure: 29

Figure 30: Control group four weeks specimen.
Hematoxylin and Eosin stain, magnification 435X
Photomicrograph showing the presence of osteocytes in the new bone and notice osteoblasts lining the periphery of new bone. New capillaries are present in the fibrous stroma. N.B. - New bone; O.B. - Osteoblasts; O.C. - Osteocytes; C.T. - Connective tissue; B.V. - Blood vessels.

Figure 31: Autogenous graft six weeks specimen.
Hematoxylin and Eosin stain, magnification 10X
Photomicrograph depicting union of the graft to the host bone by new bone and fibrous tissue.
B.U. - Bony union; A.G. - Autogenous graft; F.U. - Fibrous union; H.B. - Host bone.

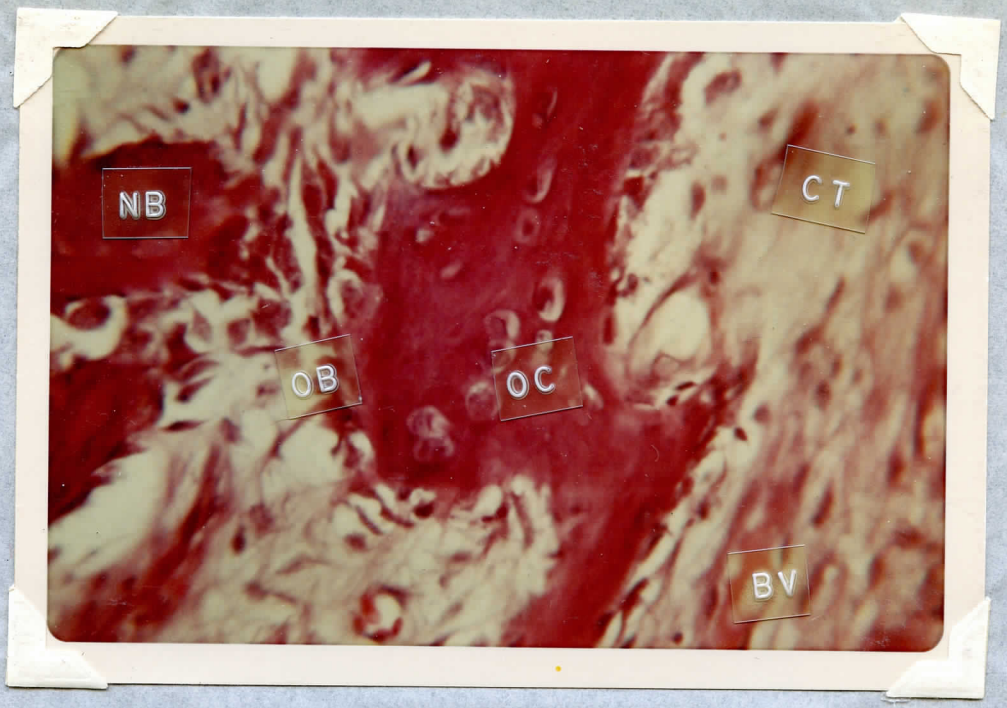

Figure: 30

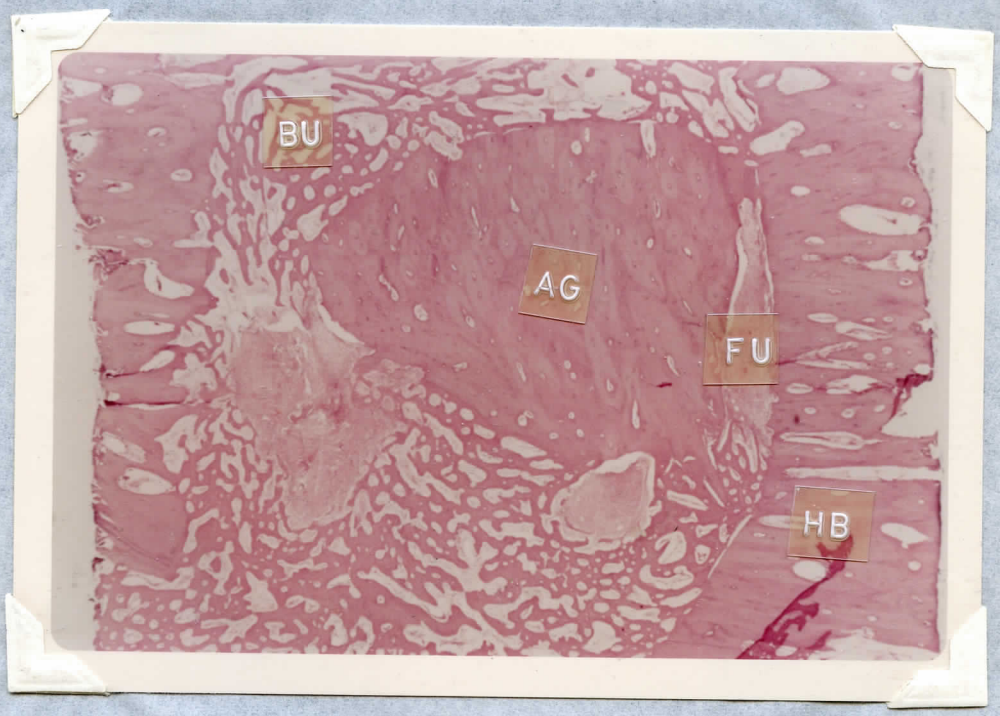

Figure: 31

Figure 32: Autogenous graft six weeks specimen.
Hematoxylin and Eosin stain, magnification 50X
Photomicrograph shows loose trabeculae uniting the graft to the host bone. Notice the presence of fibrous tissue in the right lower quadrant.
H.B. - Host bone; A.G. - Autogenous graft; F.T. - Fibrous tissue.

Figure 33: Autogenous graft six weeks. specimen.
Hematoxylin and Eosin stain, magnification 100X
Photomicrograph showing new bone formation on the graft and notice the complete enclavement of osteoblasts and blood vessels in the new bone.
A.G. - Autogenous graft; N.B. - New bone.

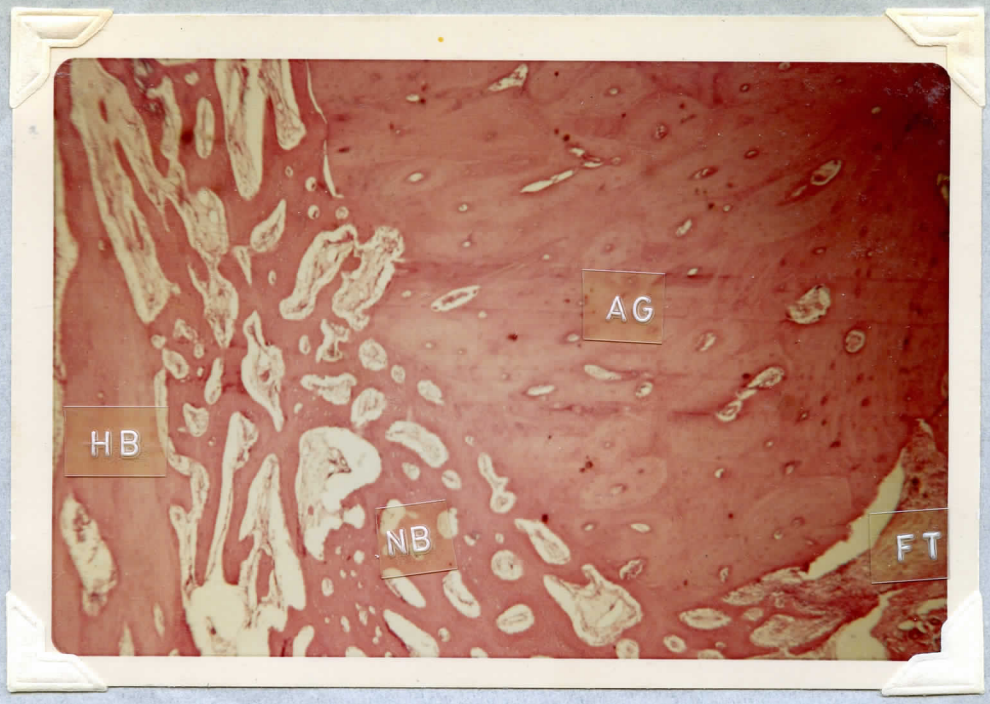

Figure: 32

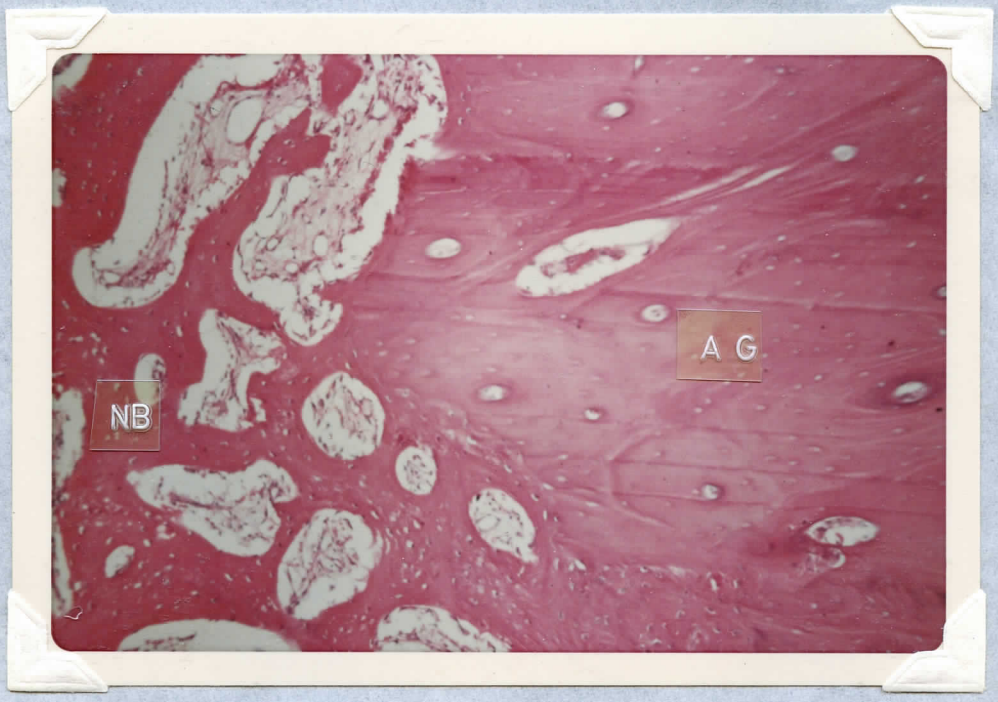

Figure: 33

Figure 34: Autogenous graft six weeks specimen.
Hematoxylin and Eosin stain, magnification 435X
Photomicrograph demonstrating viability of the graft by the presence of osteocytes.
E.L. - Empty lacunae; O.C. - Osteocytes; H.C. - Haversian canal.

Figure 35: Decalcified Homologous graft six weeks specimen.
Hematoxylin and Eosin stain, magnification 10X
Photomicrograph showing the presence of fibrous tissue between the graft and the host bone.
H.B. - Host bone; N.B. - New bone; F.T. - Fibrous tissue.

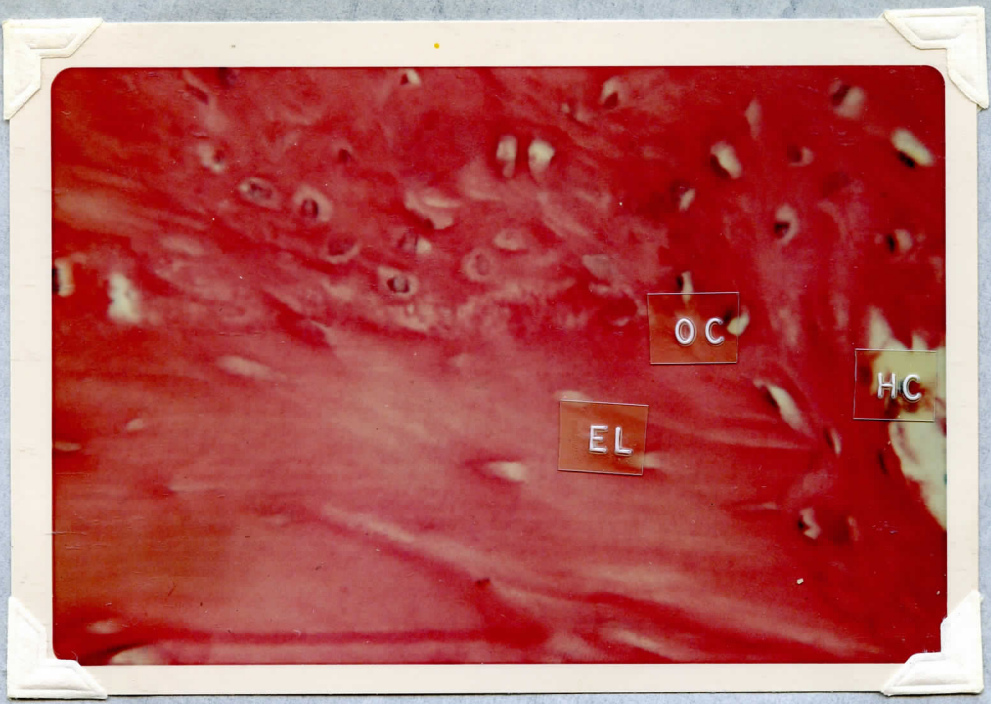

Figure: 34

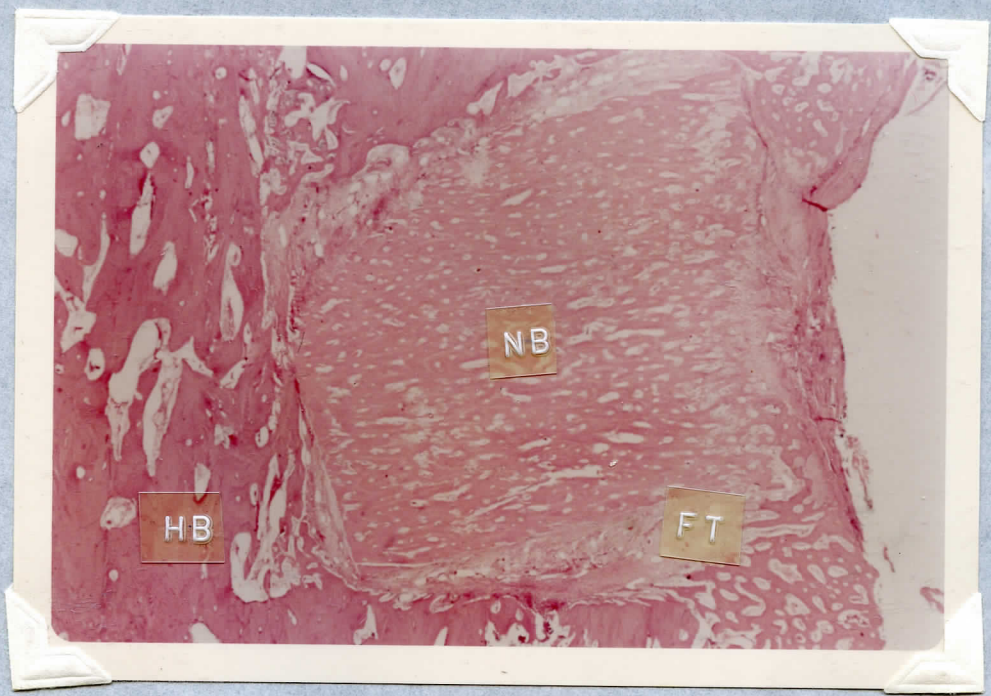

Figure: 35

Figure 36: Decalcified Homologous graft six weeks specimen. Hematoxylin and Eosin stain, magnification 50X Photomicrograph showing the graft separated from the host bone by a thin layer of fibrous tissue. Notice the increased vascularity of the new bone and fibrous stroma. H.B. - Host bone; F.T. - Fibrous tissue; N.B. - New bone.

Figure 37: Decalcified Homologous graft six weeks specimen. Hematoxylin and Eosin stain, magnification 100X Photomicrograph demonstrating the enclavement of blood vessels in the new bone. Notice budding of the new bone from the host bone, also the amount of new blood vessels in the fibroblastic tissue. H.B. - Host bone; B.V. - Blood vessel; N.B. - New bone; F.S. - Fibroblastic stroma.

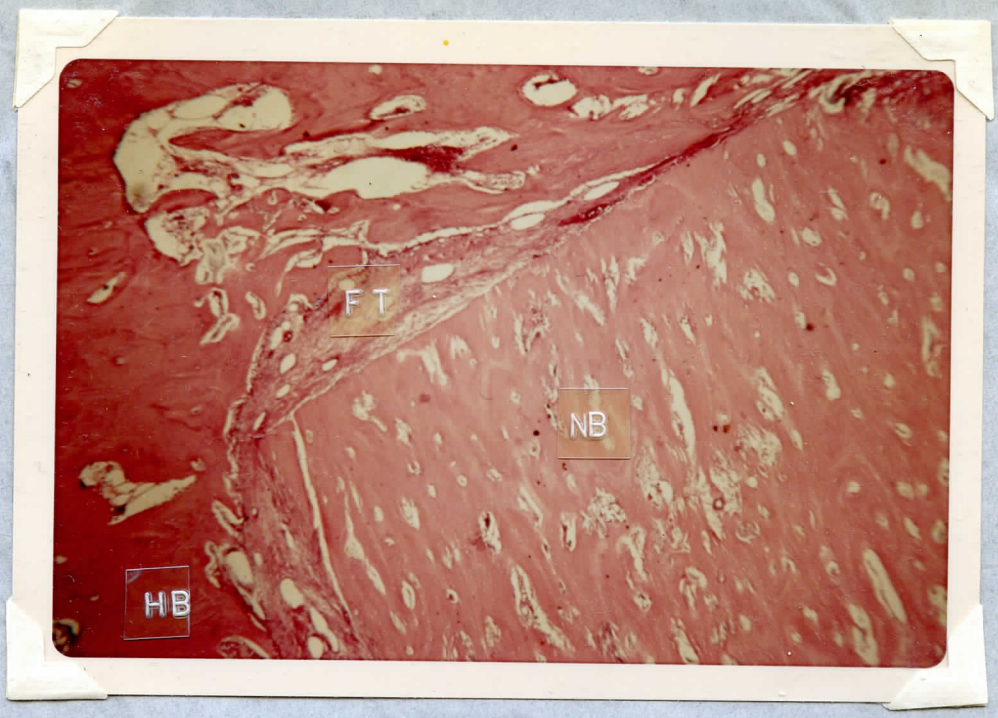

Figure: 36

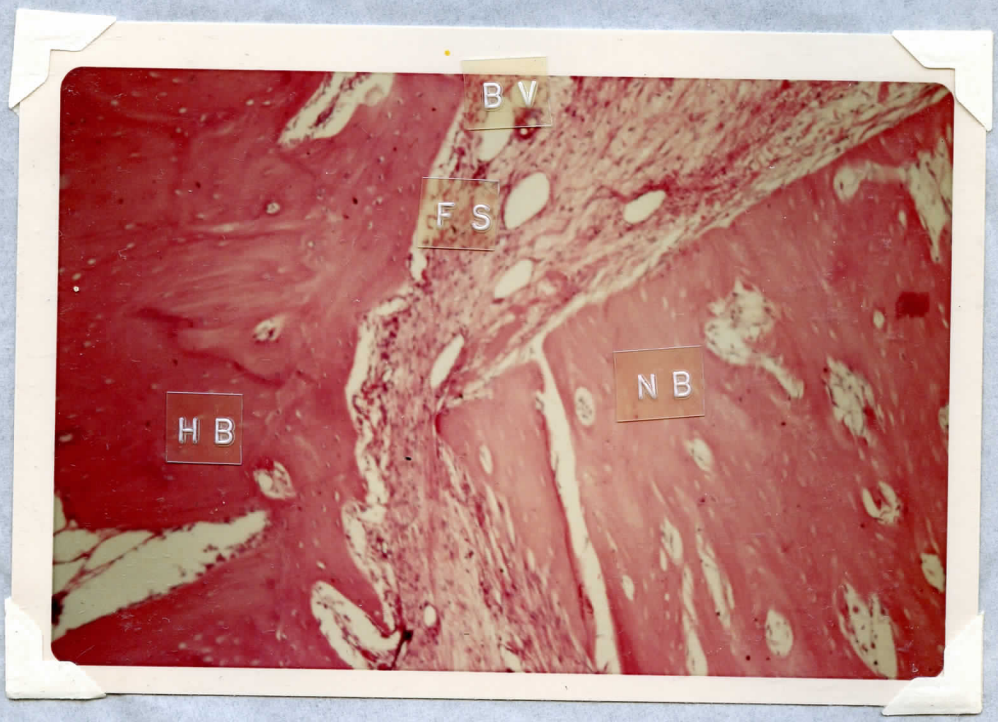

Figure: 37

Figure 38: Decalcified Homologous graft six weeks specimen. Hematoxylin and Eosin stain, magnification 435X Photomicrograph showing the vascularity of new bone and notice the amount of fibroblastic tissue. F - Fibroblasts; B.V. - Blood vessels; L - Lacunae; F.H.C. - Formation of Haversian canal.

Figure 39: Control group six weeks specimen. Hematoxylin and Eosin stain, magnification 10X Photomicrograph showing new bone formation which is obliterating the bony defect incompletely as demonstrated by empty space. H.B. - Host bone; E.S. - Empty space; N.B. - New bone; F.T.-Fibrous tissue.

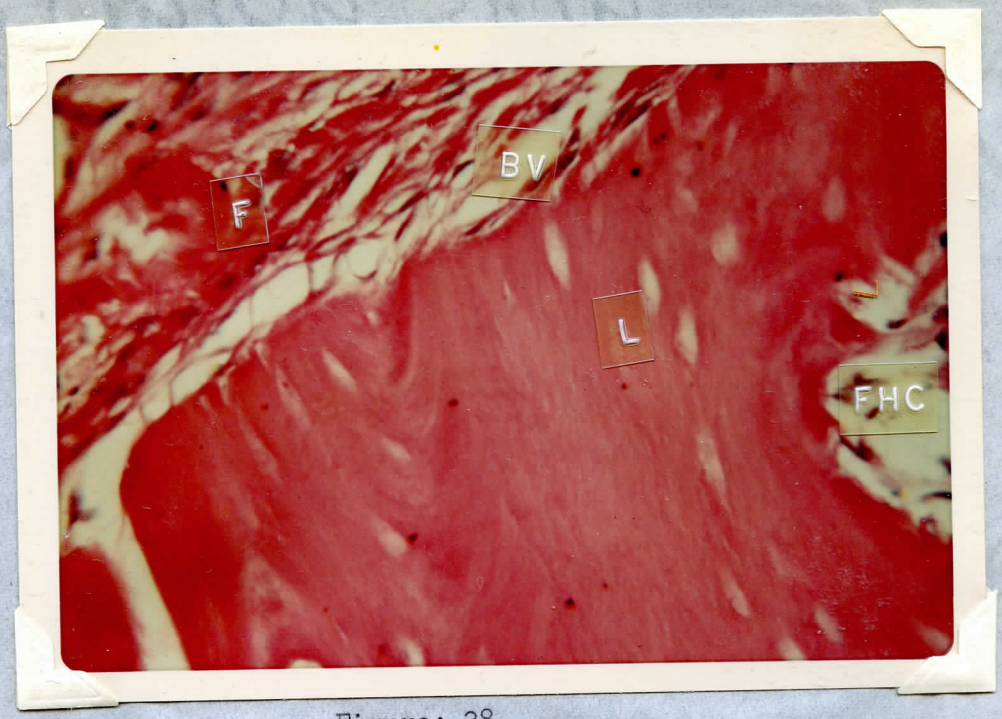

Figure: 38

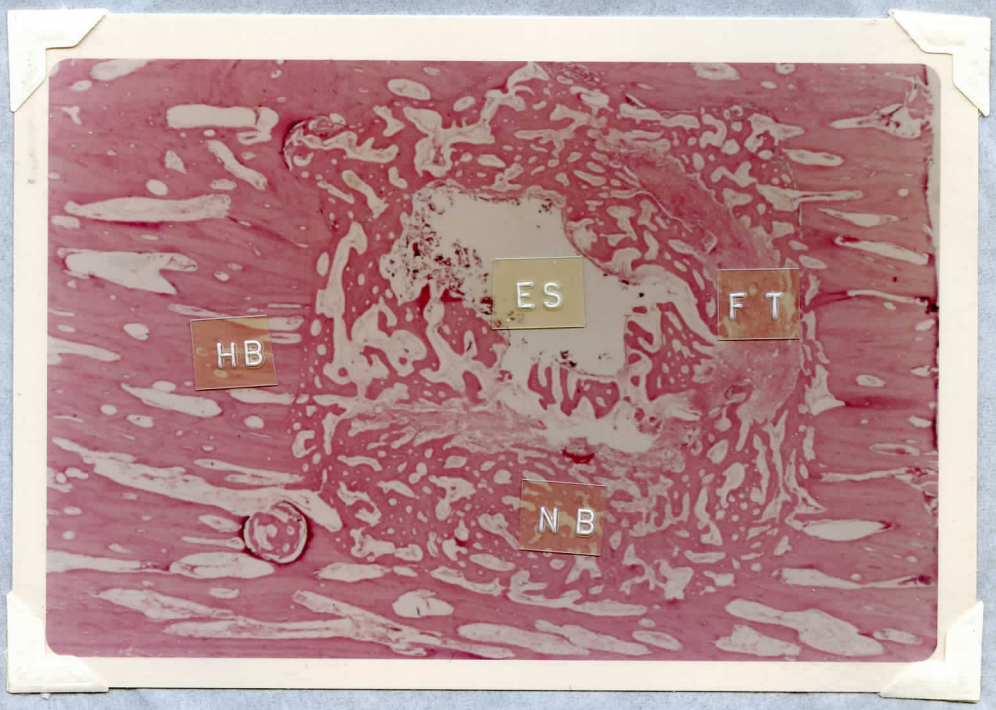

Figure: 39

Figure 40: Control group six weeks specimen.
Hematoxylin and Eosin stain, magnification 50X
Photomicrograph depicting necrotic tissue in the empty space and notice new bone formation from the host bone. N.T. - Necrotic tissue; E.S. - Empty space; N.B. - New bone.

Figure 41: Control group six weeks specimen.
Hematoxylin and Eosin stain, magnification 100X
Photomicrograph demonstrating the enclavement of blood vessels and osteoblasts in the new bone.
H.B. - Host bone; N.B. - New bone; B.V. - Blood vessel; O.C. - Osteocyte; H.C. - Haversian canal; O.S. - Osteoblast.

Figure: 40

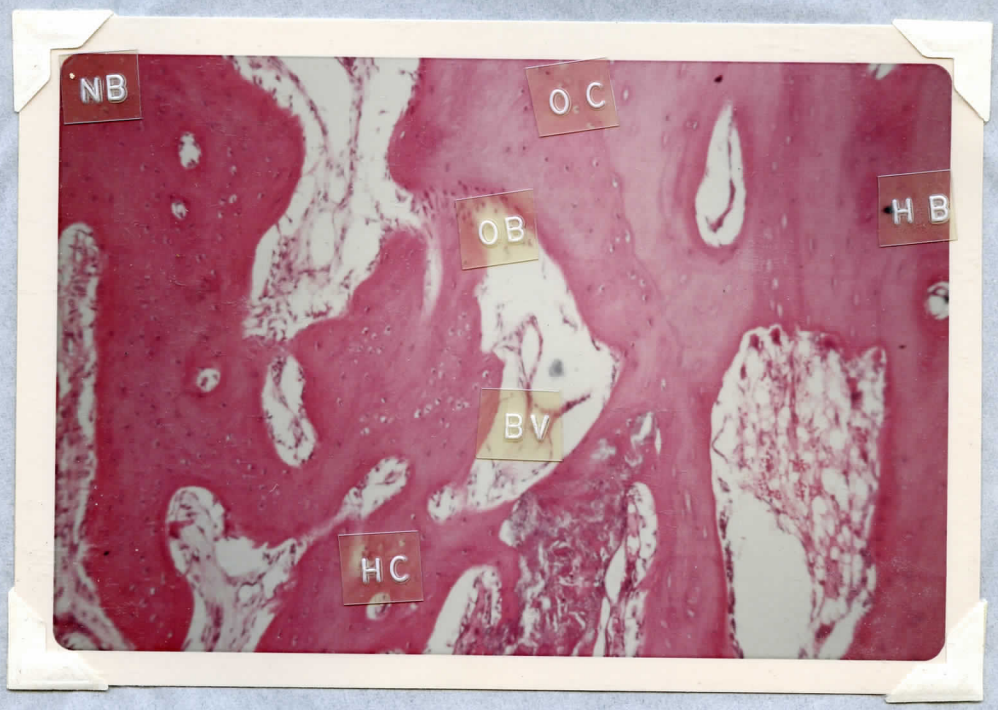

Figure: 41

Figure 42: Control group six weeks specimen.
Hematoxylin and Eosin stain, magnification 435X
Photomicrograph showing enclavement of a blood vessel in the new bone in the left upper quadrant and notice the difference in maturity of the host bone to the new bone. N.B. - New bone; H.B. - Host bone; O.C. - Osteocytes; H.C. - Haversian canal.

Figure 43: Autogenous graft eight weeks specimen.
Hematoxylin and Eosin stain, magnification 10X
Photomicrograph showing fibrous and bony union of the graft to the host bone. H.B. - Host bone; A.G. - Autogenous graft; B.U. - Bony union; F.U.- Fibrous union.

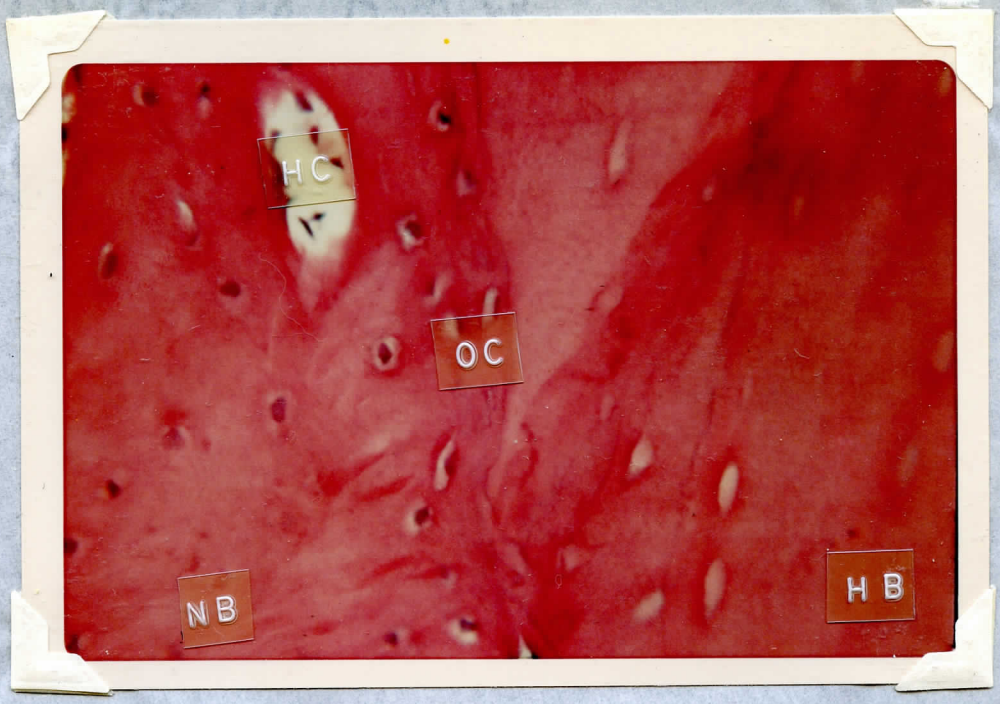

Figure: 42

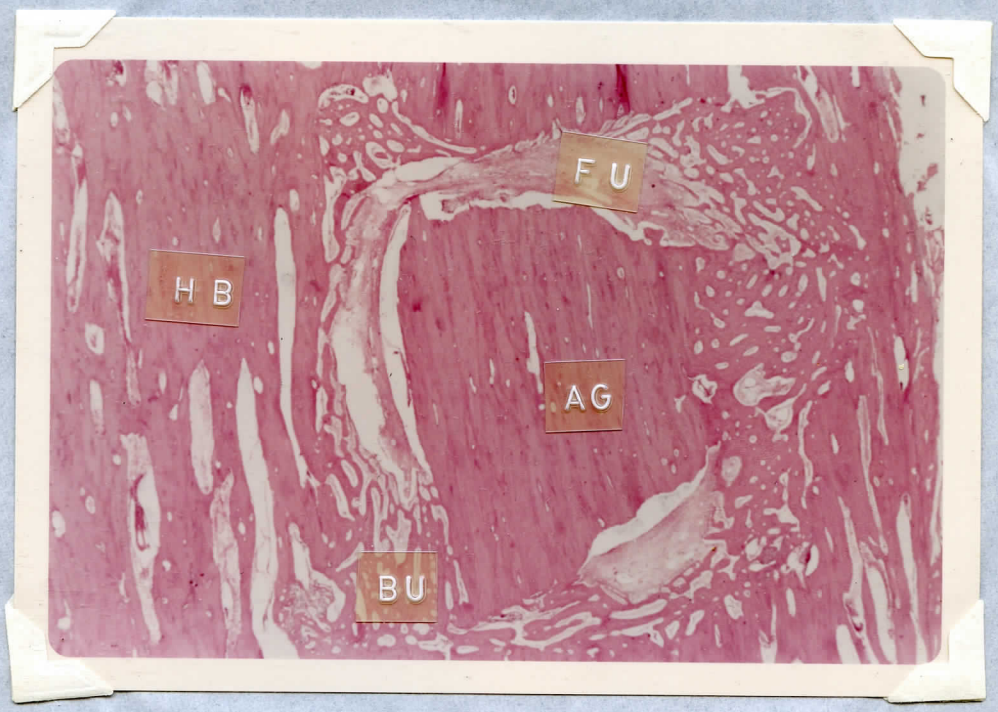

Figure: 43

Figure 44: Autogenous graft eight weeks specimen. Hematoxylin and Eosin stain, magnification 50X Photomicrograph demonstrating the enclavement of blood vessels and fibrous marrow in the new bone, which is uniting the graft to the host bone. Notice the presence of fibrous tissue on the right side of the photomicrograph. N.B. - New bone; H.B. - Host bone; A.G. - Autogenous graft; F.T. - Fibrous tissue.

Figure 45: Autogenous graft eight weeks specimen. Hematoxylin and Eosin stain, magnification 100X Photomicrograph showing remodelling of new bone which is uniting the graft to the host bone. A.G. - Autogenous graft; N.B. - New bone; F. - Fibrous stroma.

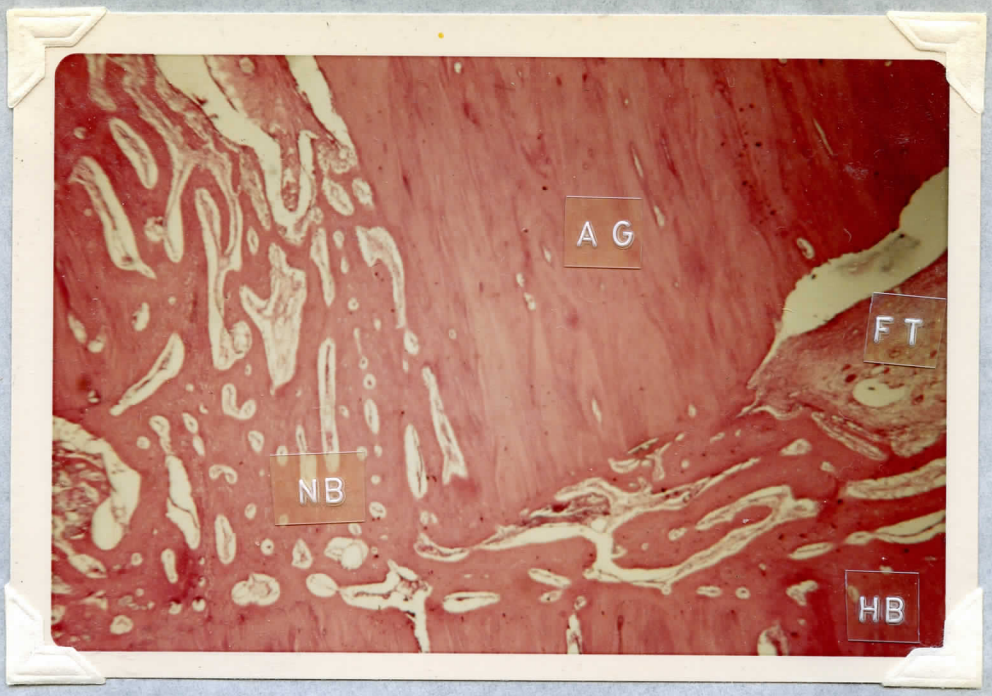

Figure: 44

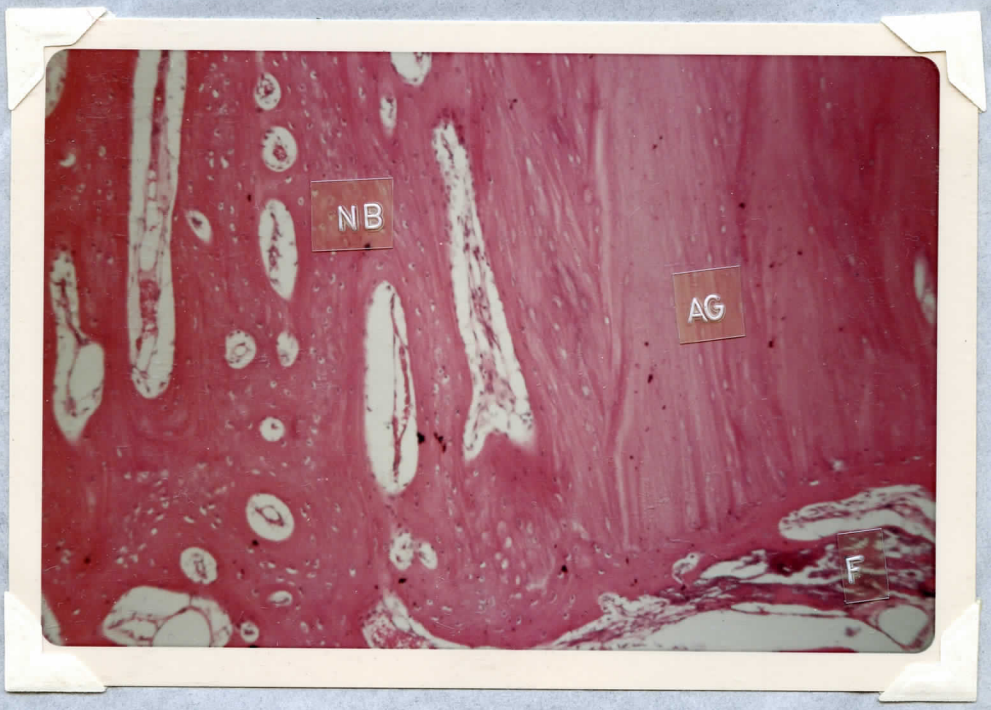

Figure: 45

Figure 46: Autogenous graft eight weeks specimen. Hematoxylin and Eosin stain, magnification 435X Photomicrograph demonstrating viability of the graft and notice the presence of numerous blood vessels and fibrous tissue. O.C. - Osteocyte; F. - Fibroblasts; B.V. - Blood vessels.

Figure 47: Decalcified Homologous graft eight weeks specimen. Hematoxylin and Eosin stain, magnification 10X Photomicrograph depicting very thin fibrous tissue separating the new bone from the host bone. H.B. - Host bone; N.B. - New bone; F.T. - Fibrous tissue.

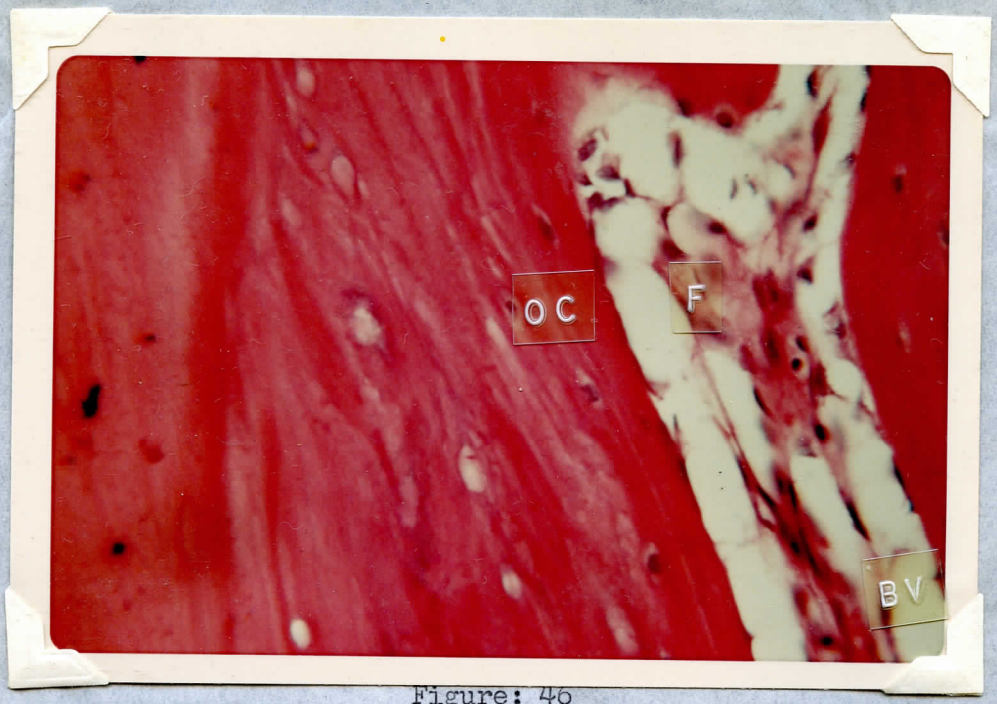

Figure: 46

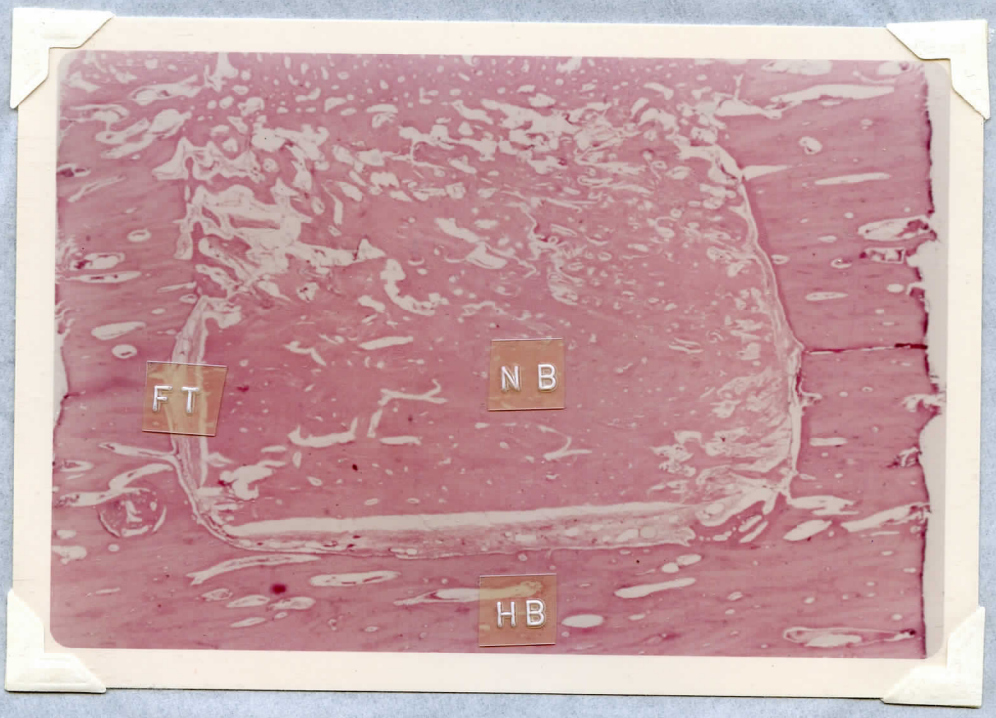

Figure: 47

Figure 48: Decalcified Homologous graft eight weeks specimen. Hematoxylin and Eosin stain, magnification 50X Photomicrograph demonstrating almost complete replacement of the graft by new bone, however necrotic bone is seen in few areas. Notice the vascularity and maturity of the new bone. H.B. - Host bone; F.T. - Fibrous tissue; V.C. - Volkmann's canal; N.B. - New bone.

Figure 49: Decalcified Homologous graft eight weeks specimen. Hematoxylin and Eosin stain, magnification 100X Photomicrograph showing the necrotic bone in the right upper quadrant and the fibrous tissue formation in the lower border. Notice the vascularity and remodelling of the new bone. F.T. - Fibrous tissue; N.B. - New bone; H.C. - Haversian canal.

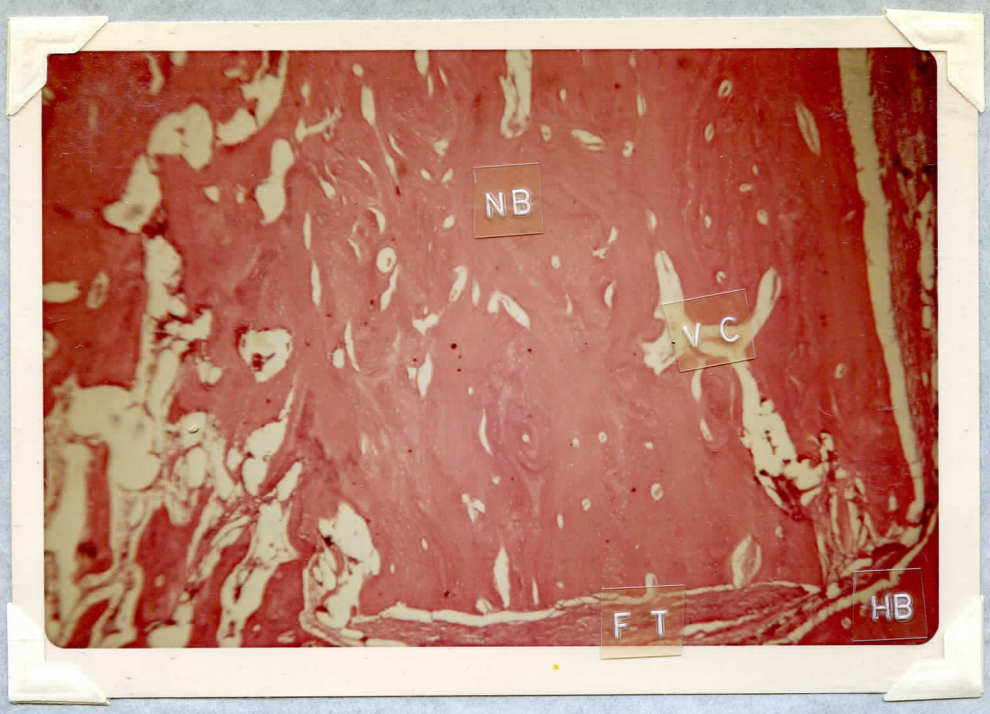

Figure: 48

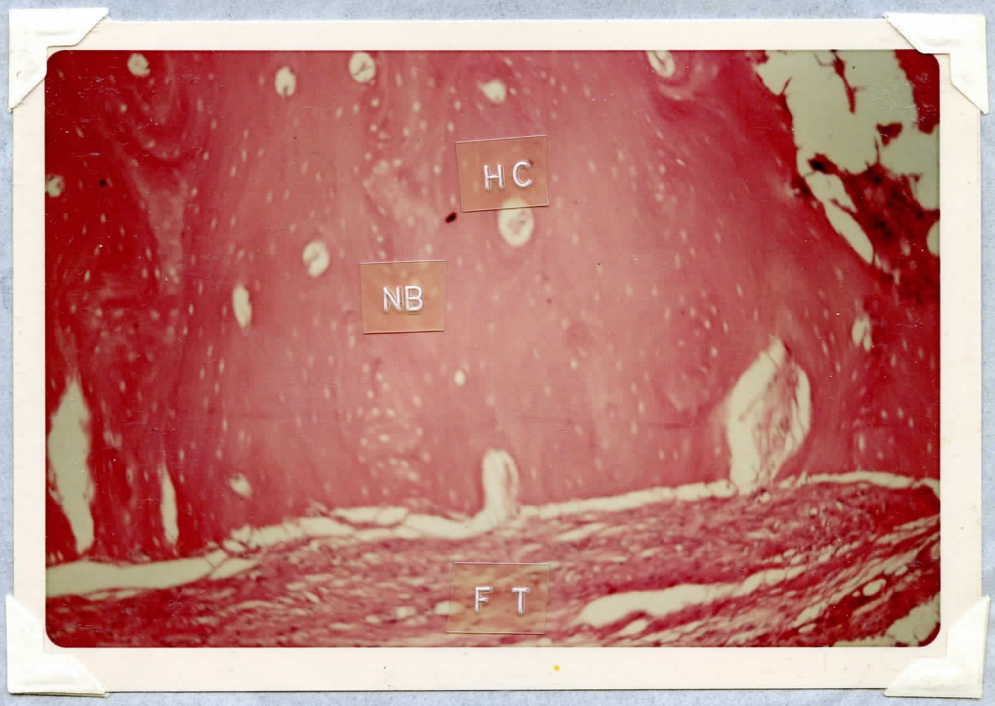

Figure: 49

Figure 50: Declacified Homologous graft eight weeks specimen. Hematoxylin and Eosin stain, magnification 435X Photomicrograph showing the viability of new bone and notice the maturity of the new bone. H.C. - Haversian canal; L. - Lammellae; N.B. - New bone.

Figure 51: Decalcified Homologous graft eight weeks specimen. Hematoxylin and Eosin stain, magnification 435X Photomicrograph demonstrating viability of the new bone. Notice the presence of osteocytes in the new bone. O.C. - Osteocytes; N.B. - New bone.

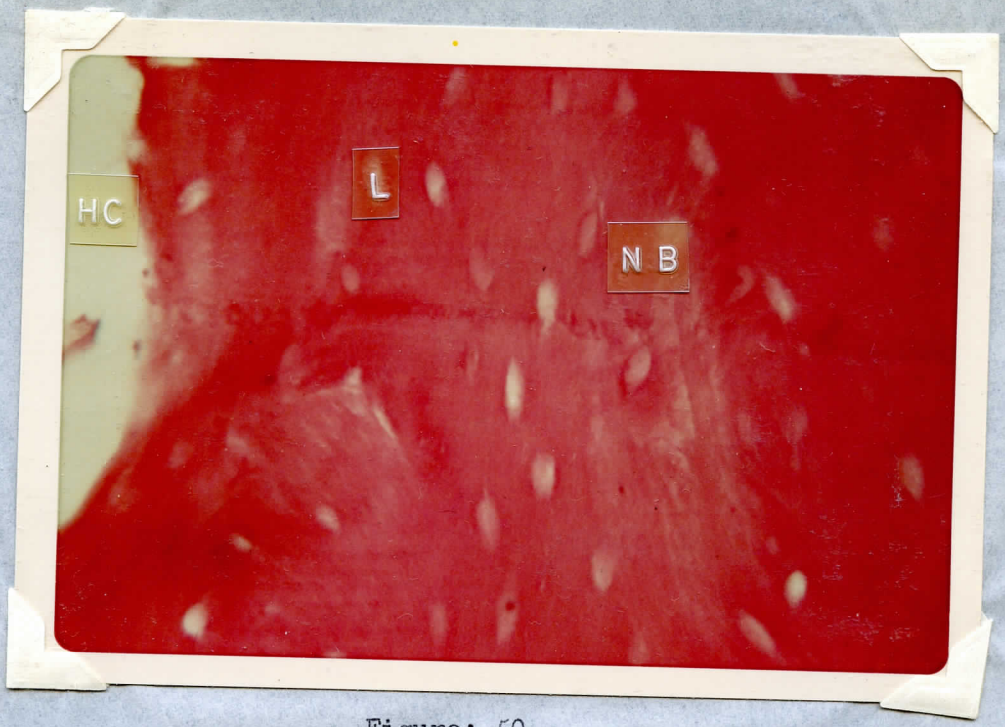

Figure: 50

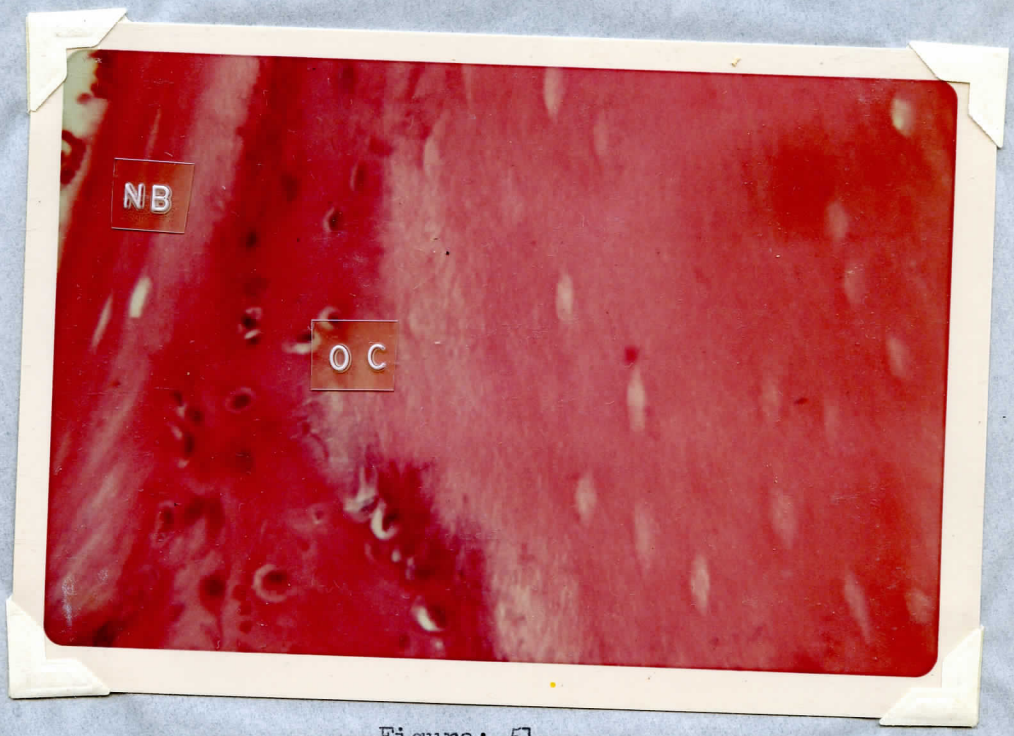

Figure: 51

Figure 52: Control group eight weeks specimen.
Goldman-Bloom stain, magnification 10X
Photomicrograph showing new bone formed along the bony defect and notice the central area devoid of any bone as the regeneration of new bone was very slow in the control group. H.B. - Host bone; E.S. - Empty space; N.B. - New bone.

Figure 53: Control group eight weeks specimen.
Hematoxylin and Eosin stain, magnification 50X
Photomicrograph demonstrating necrotic tissue in the empty space, and notice the new bone formation from the host bone. N.T. - Necrotic tissue; N.B. - New bone; E.S. - Empty space; H.B. - Host bone.

Figure: 52

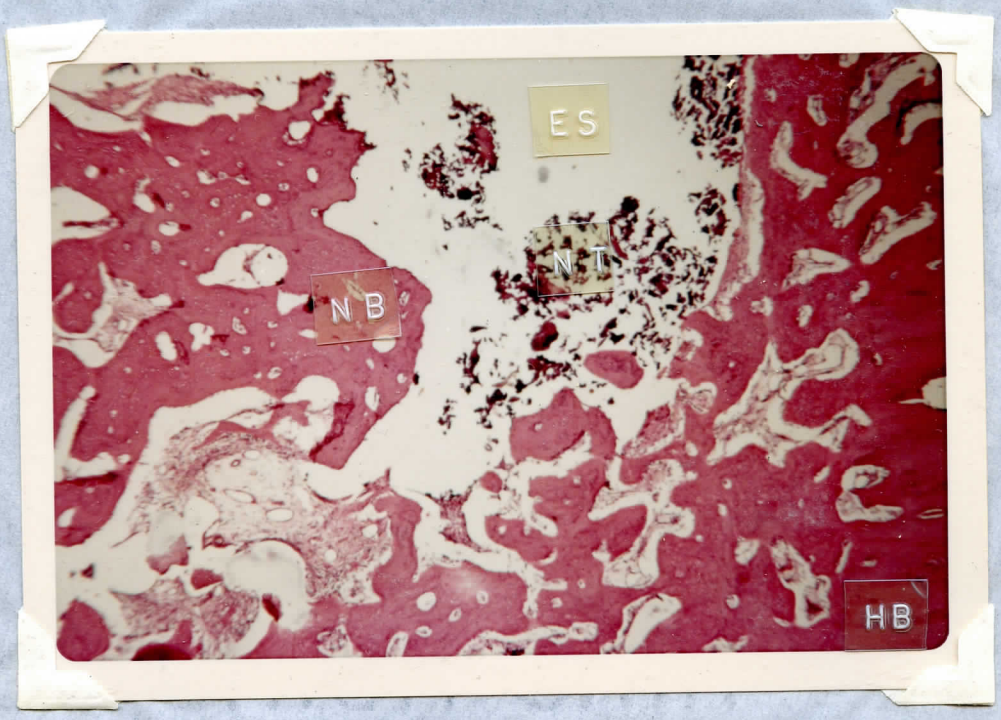

Figure: 53

Figure 54: Control group eight weeks specimen.
Hematoxylin and Eosin stain, magnification 100X
Photomicrograph showing enclavement of blood vessels and osteoblasts in the new bone. Notice the presence of necrotic tissue in the left upper quadrant.
H.B. - Host bone; N.B. - New bone; N.T. - Necrotic tissue.

Figure 55: Control group eight weeks specimen.
Hematoxylin and Eosin stain, magnification 435X
Photomicrograph demonstrating the presence of osteocytes in the new bone which is lined by osteoblasts. Notice necrotic tissue is present in the left upper quadrant.
N.T. - Necrotic tissue; O.B. - Osteoblasts; O.C. - Osteocytes.

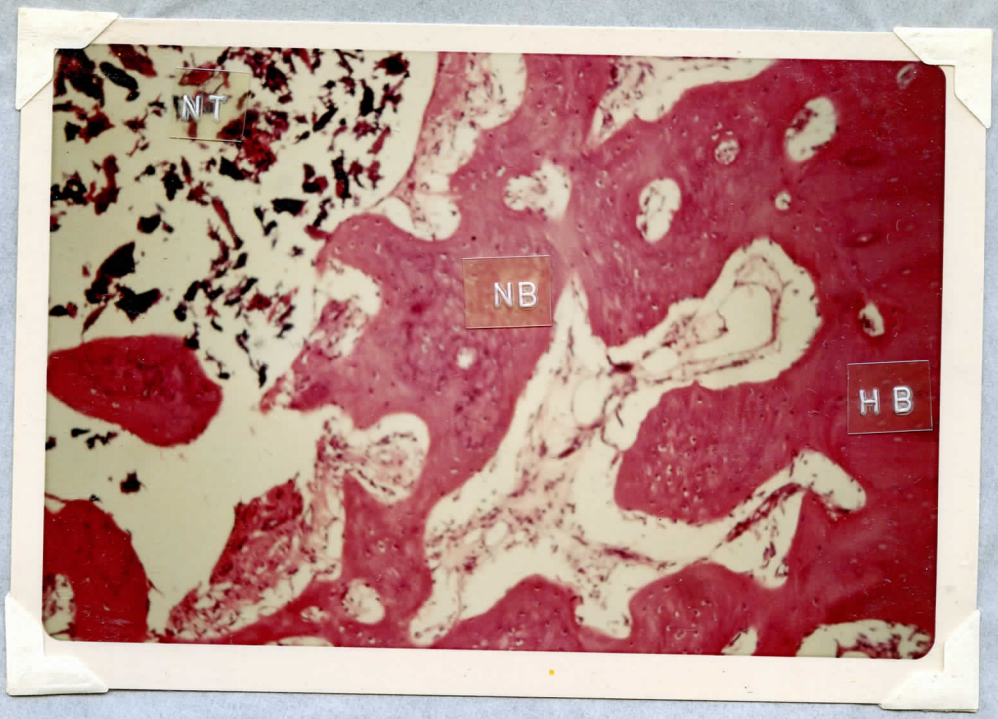

Figure: 54

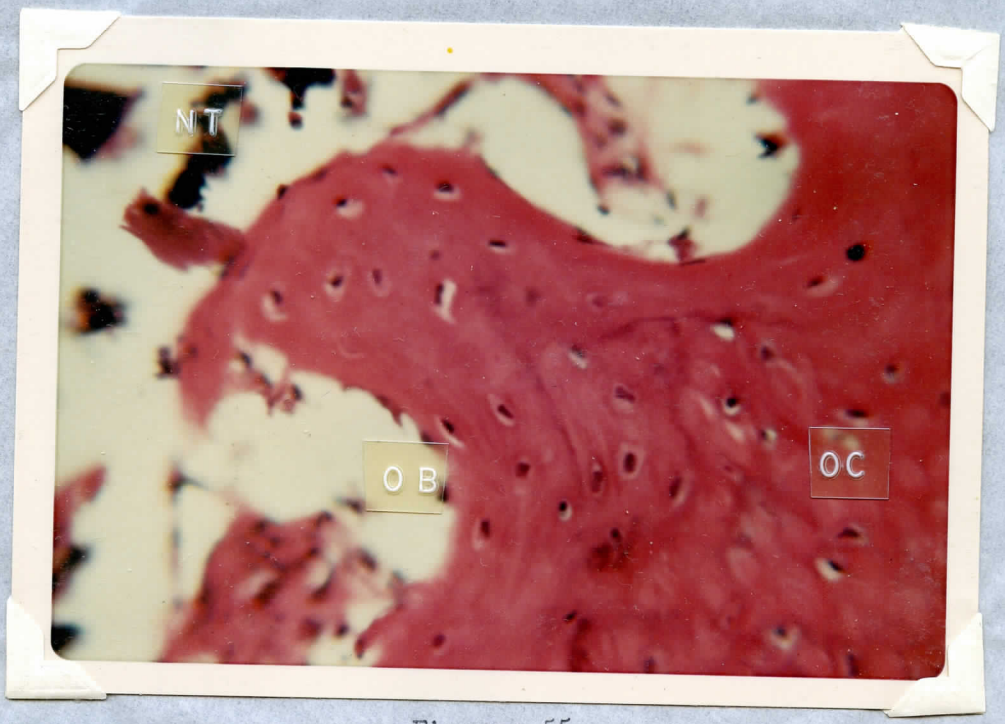

Figure: 55