

**Boston University**

**OpenBU**

<http://open.bu.edu>

---

Department of Anatomy and Neurobiology

Infographics

---

2024

# Spondylolysis

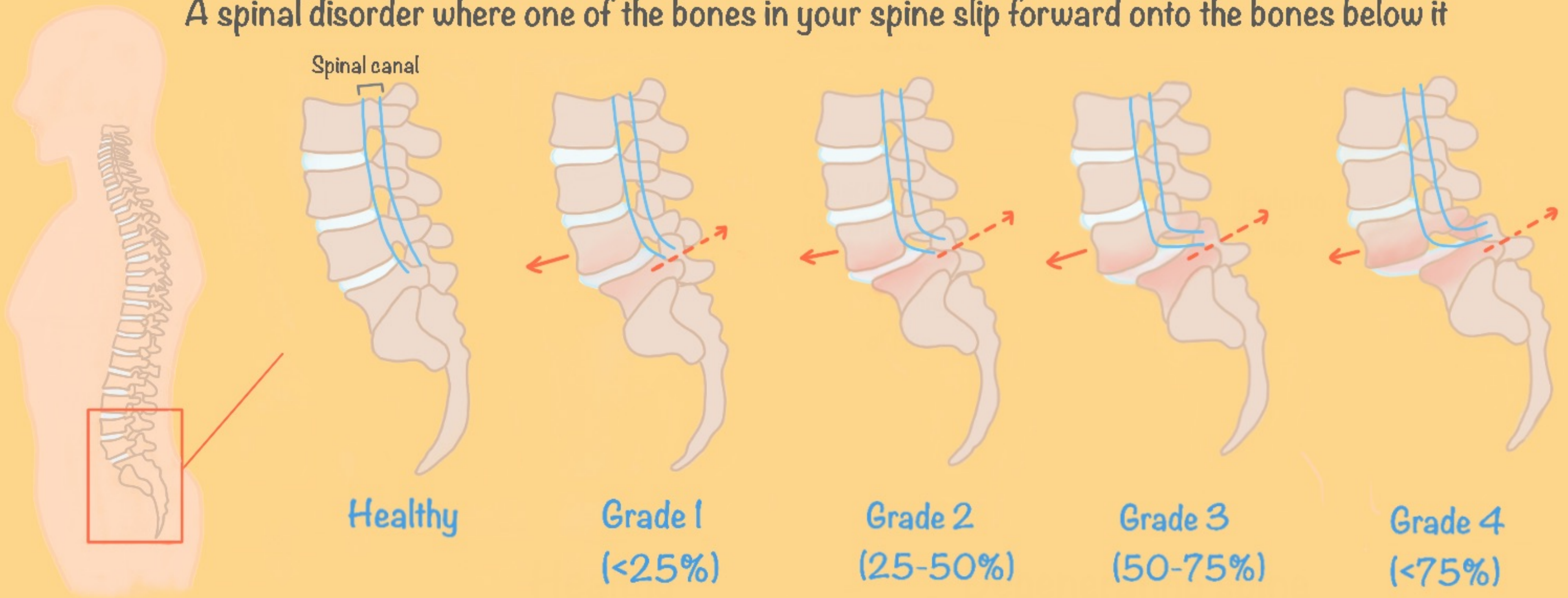
---

<https://hdl.handle.net/2144/49026>

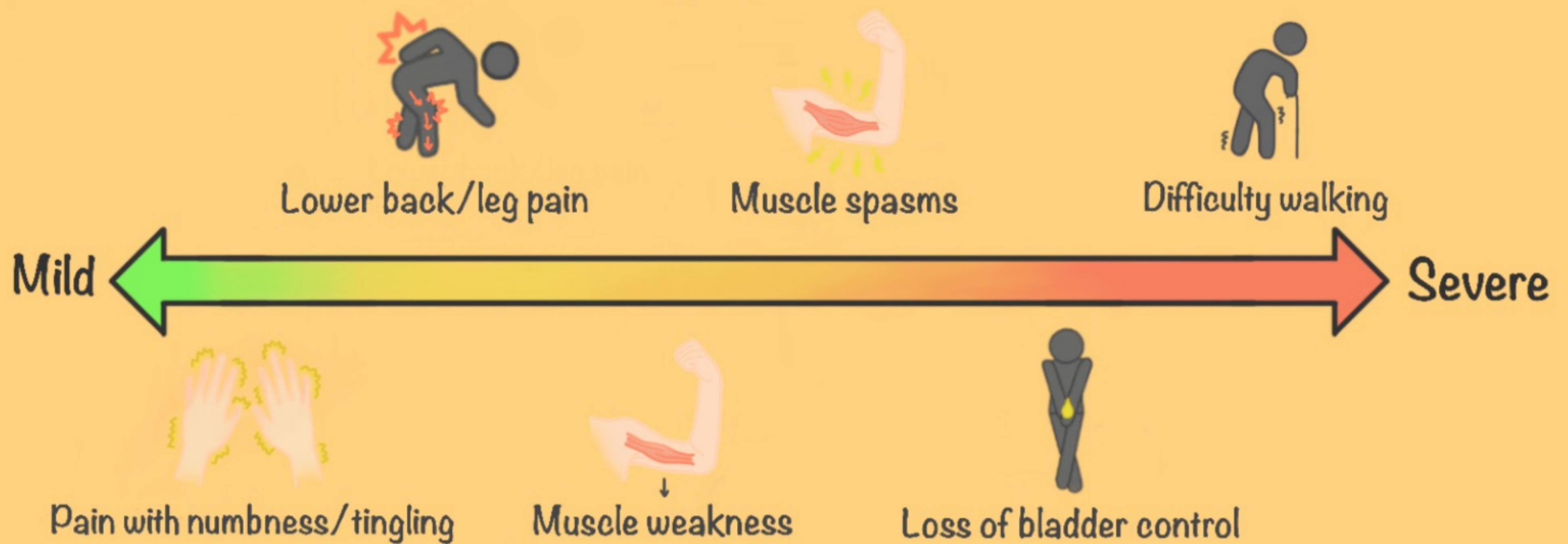
*"Downloaded from OpenBU. Boston University's institutional repository."*

# Spondylolisthesis

A spinal disorder where one of the bones in your spine slip forward onto the bones below it

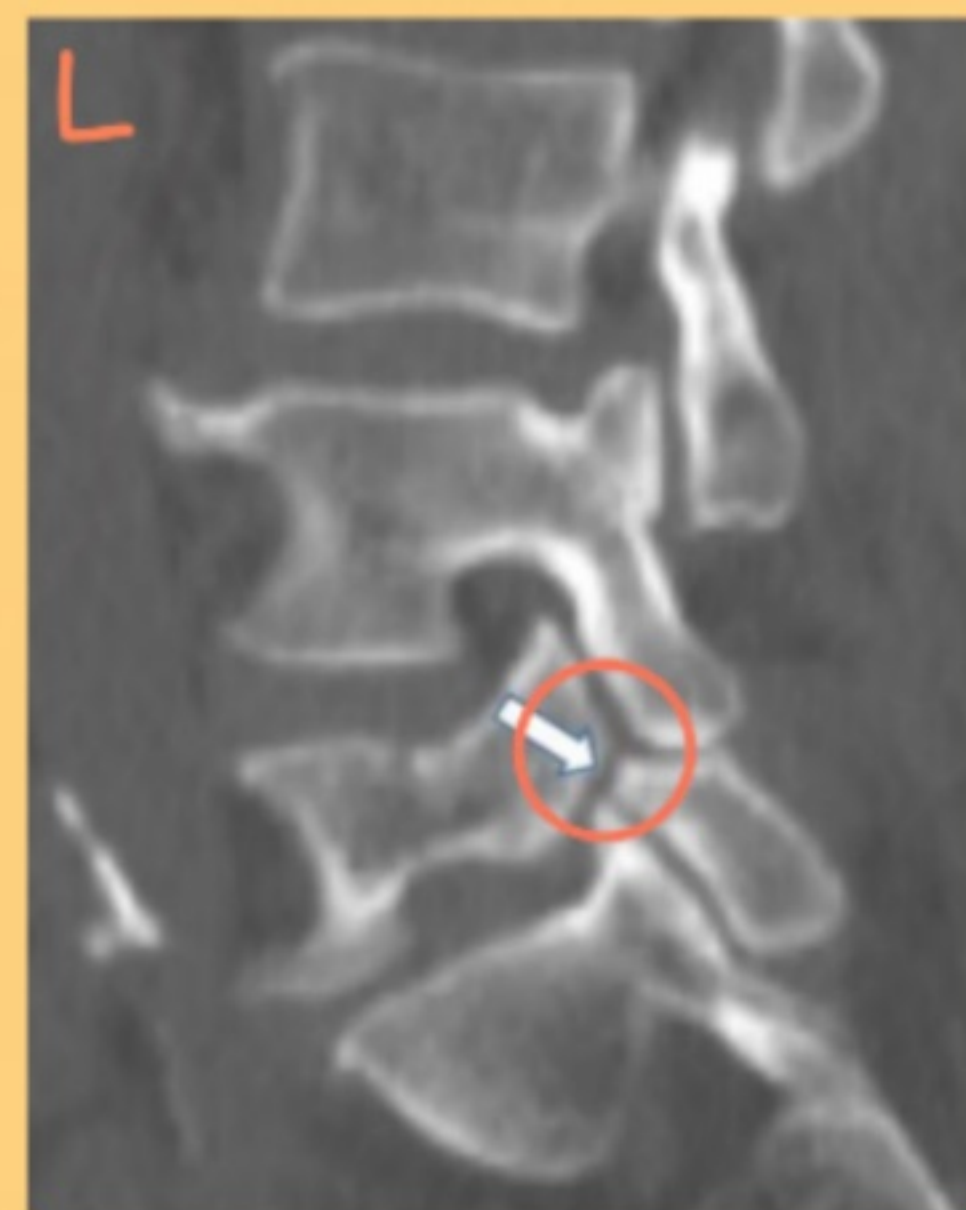
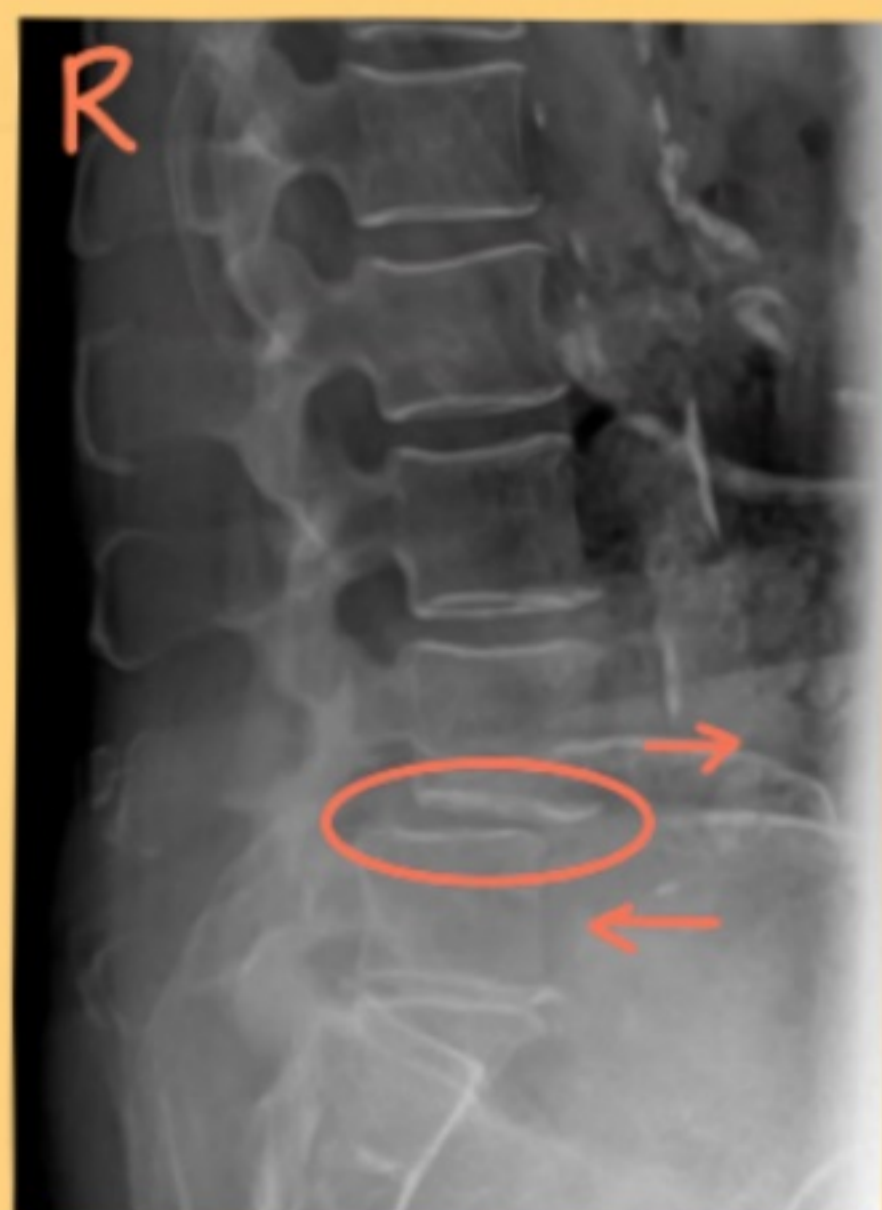
## Symptoms



## Diagnostic tests

x-ray  
(side view)

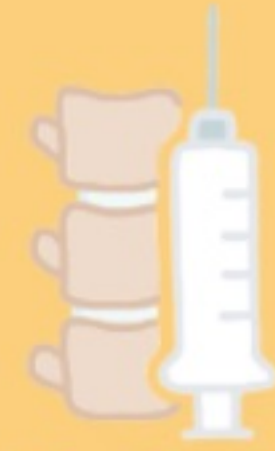

CT  
(side view)

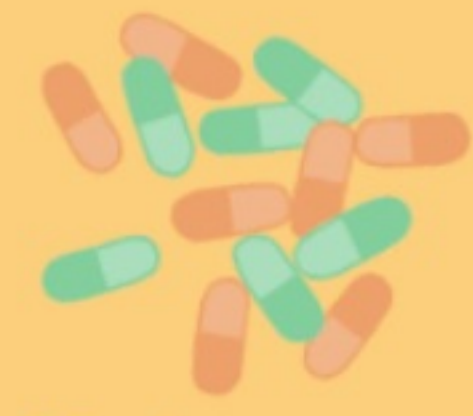# Non-Surgical Interventions



Physical therapy



Epidural

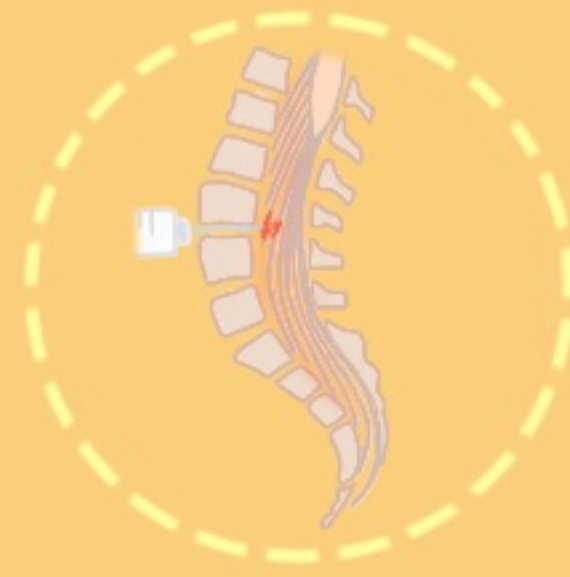

Medications

Risks

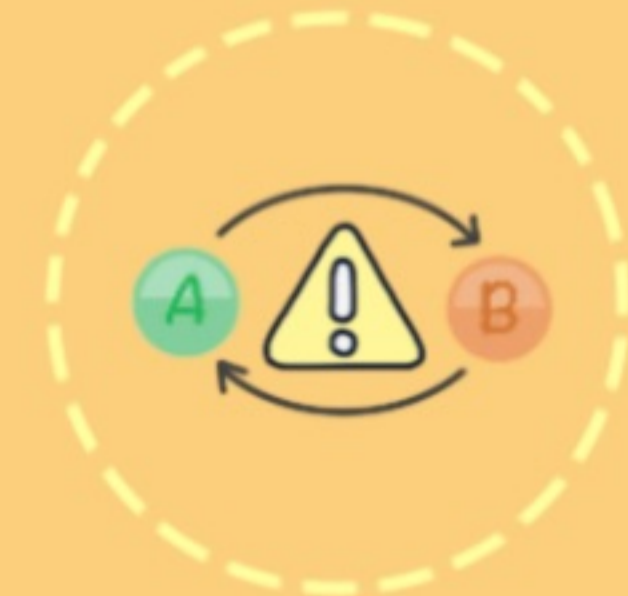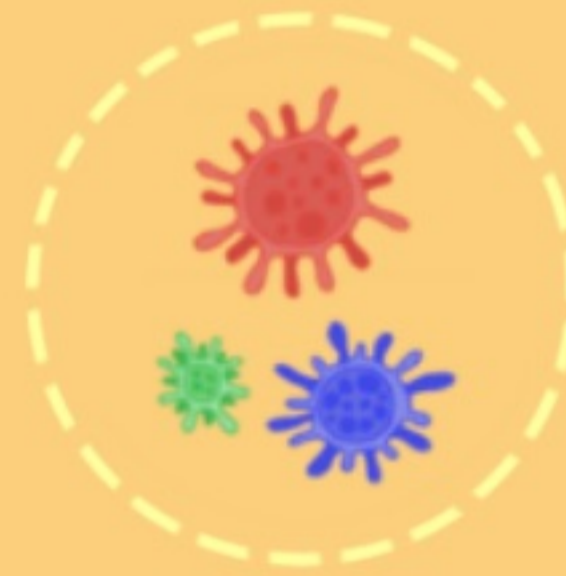


Falls



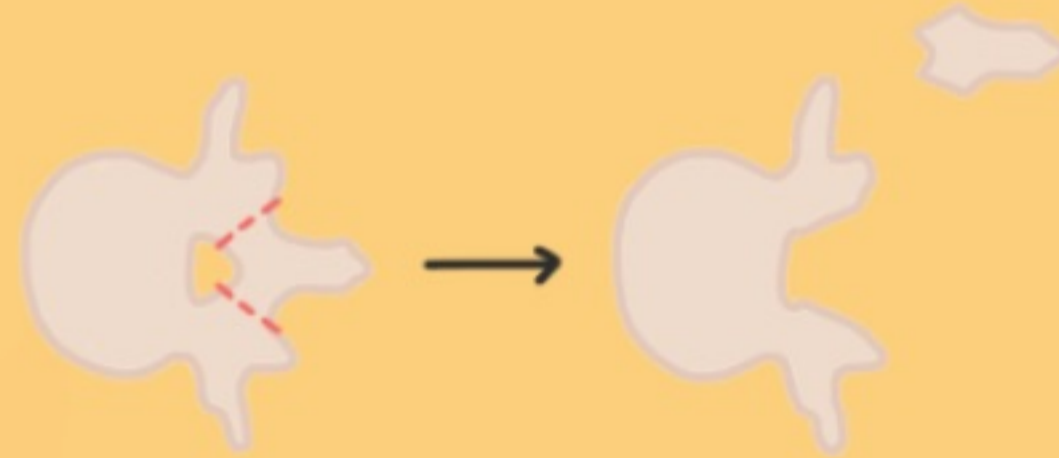
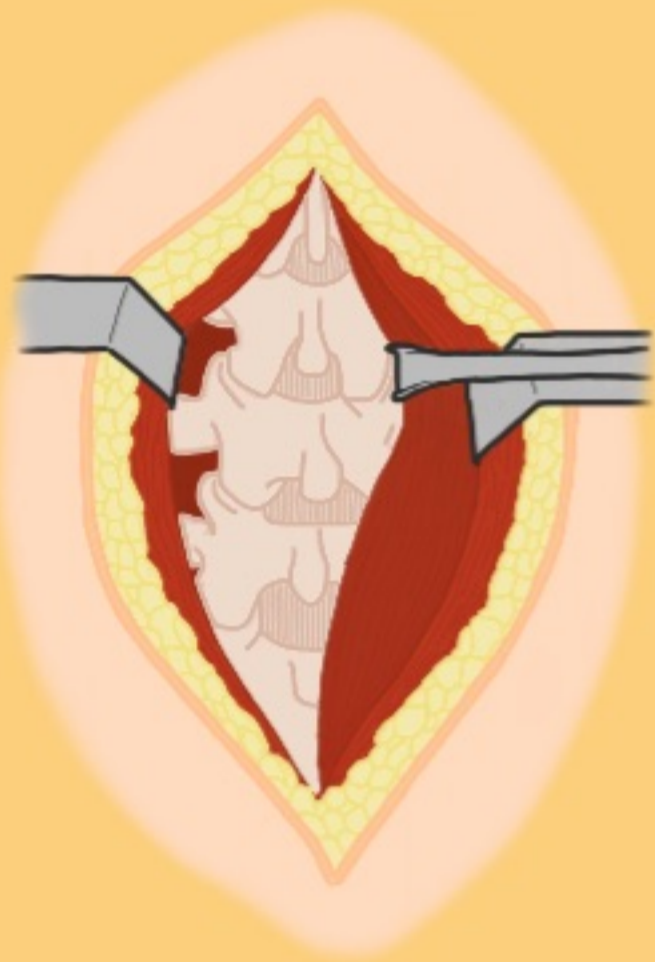
Damage to nerve root

Infection

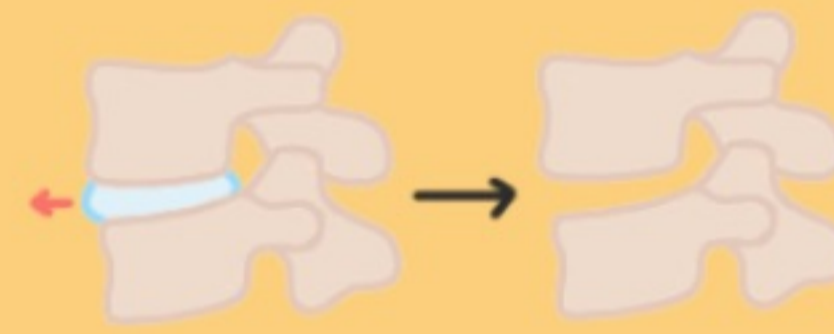

Adverse drug reactions and/or negative drug interactions

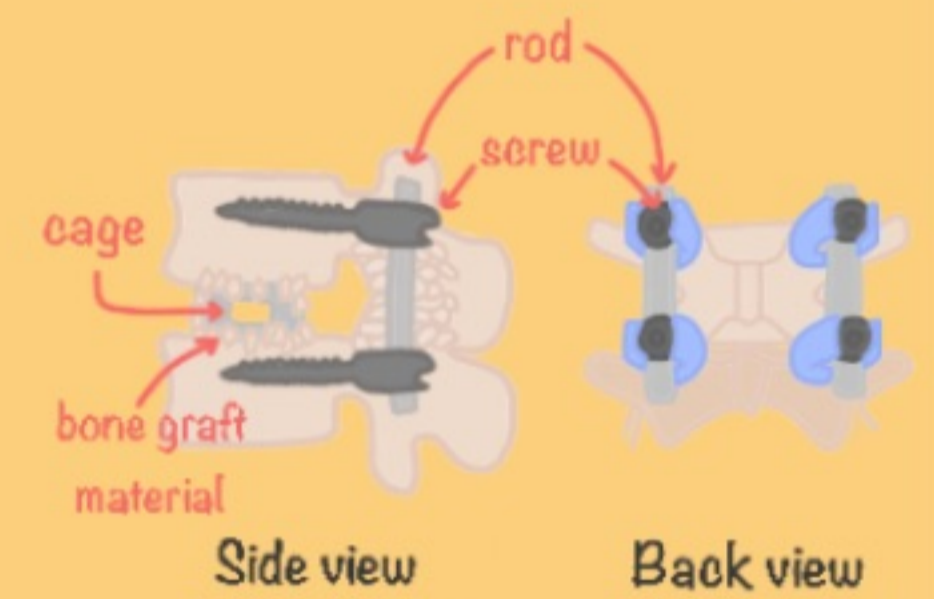
# Surgical Procedures



Laminectomy

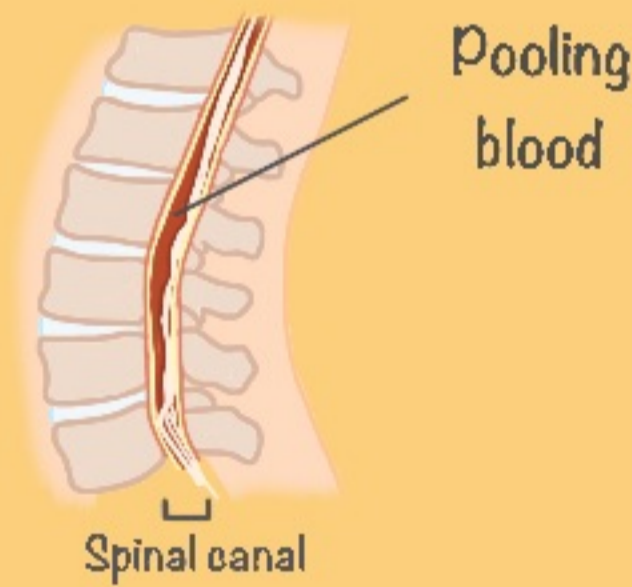


Discectomy

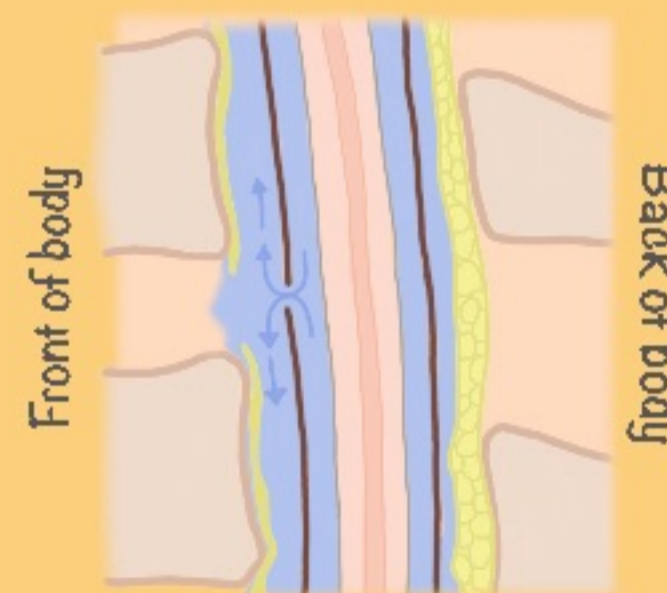


Fusion

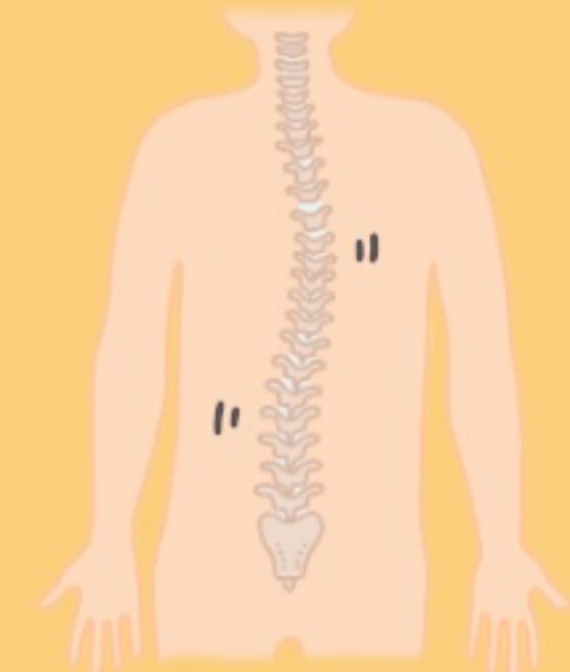
Risks



Post-operation hematoma



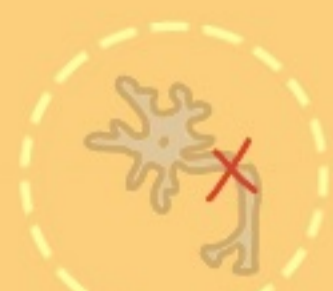Cerebrospinal fluid (CSF) leak



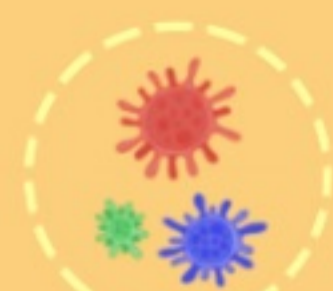Unstable spine



Blood loss



Nerve damage



Infection



Paralysis



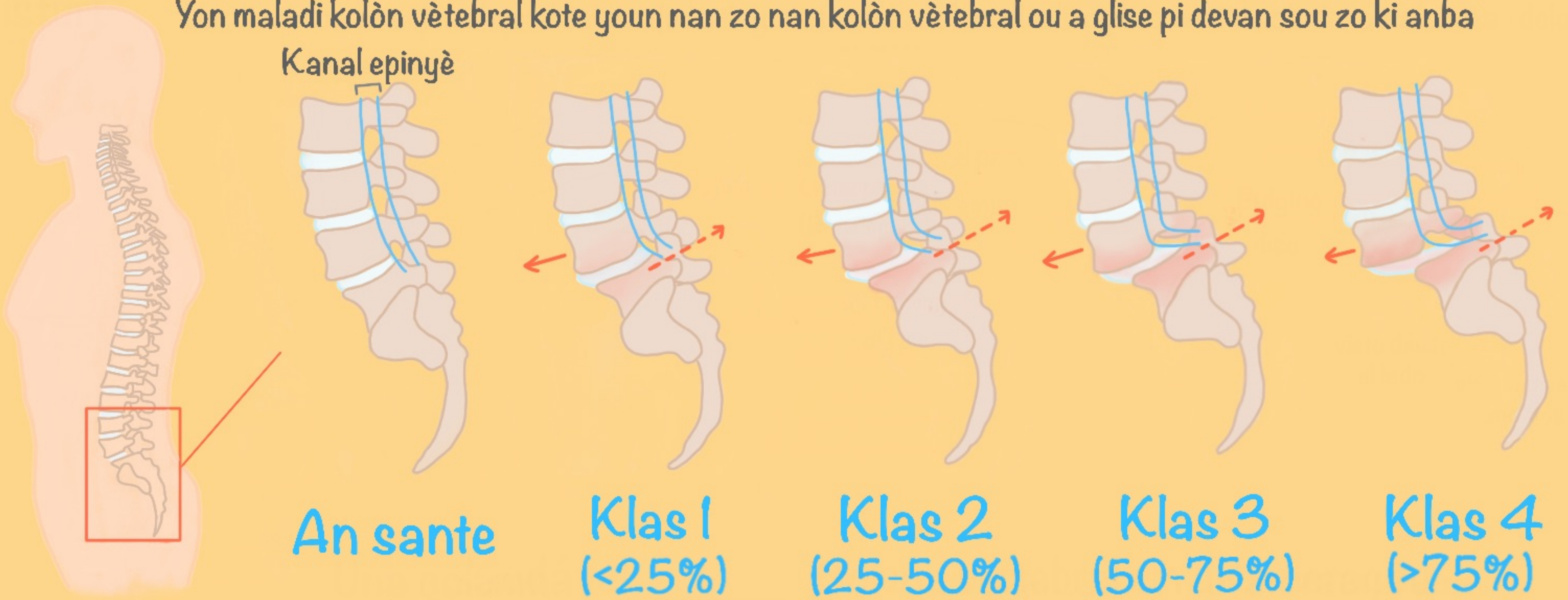
Death

Recovery ⌚ :

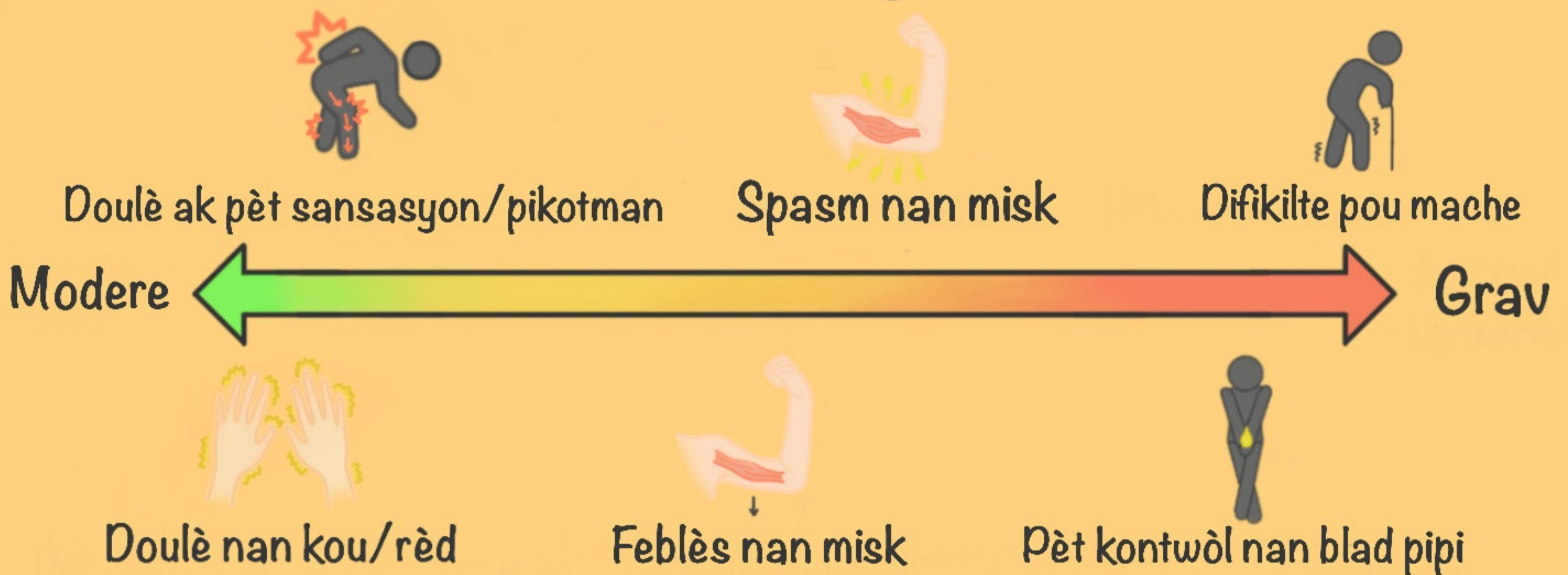

# Spondylolisthesis

Yon maladi kolòn vètebral kote youn nan zo nan kolòn vètebral ou a glise pi devan sou zo ki anba

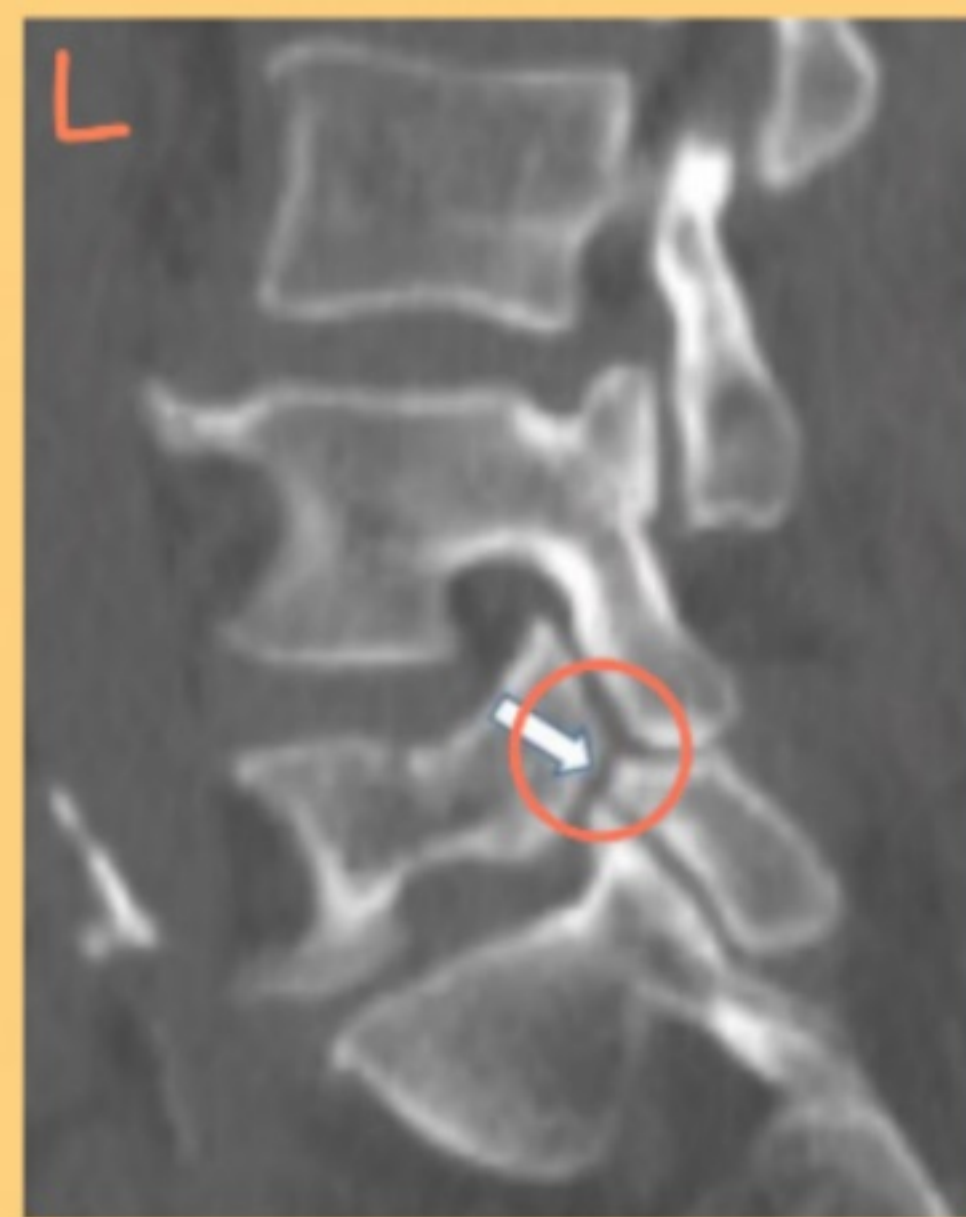
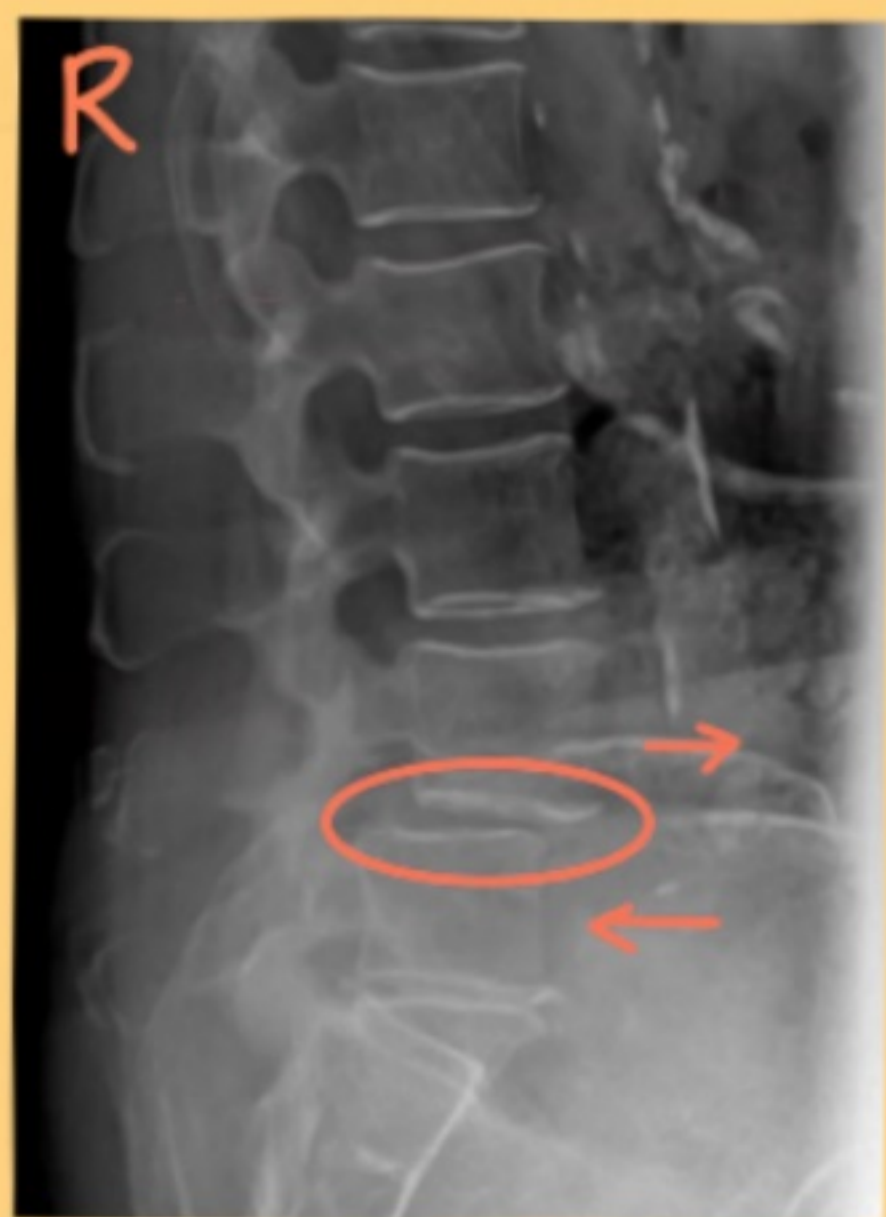
## Sentòm yo



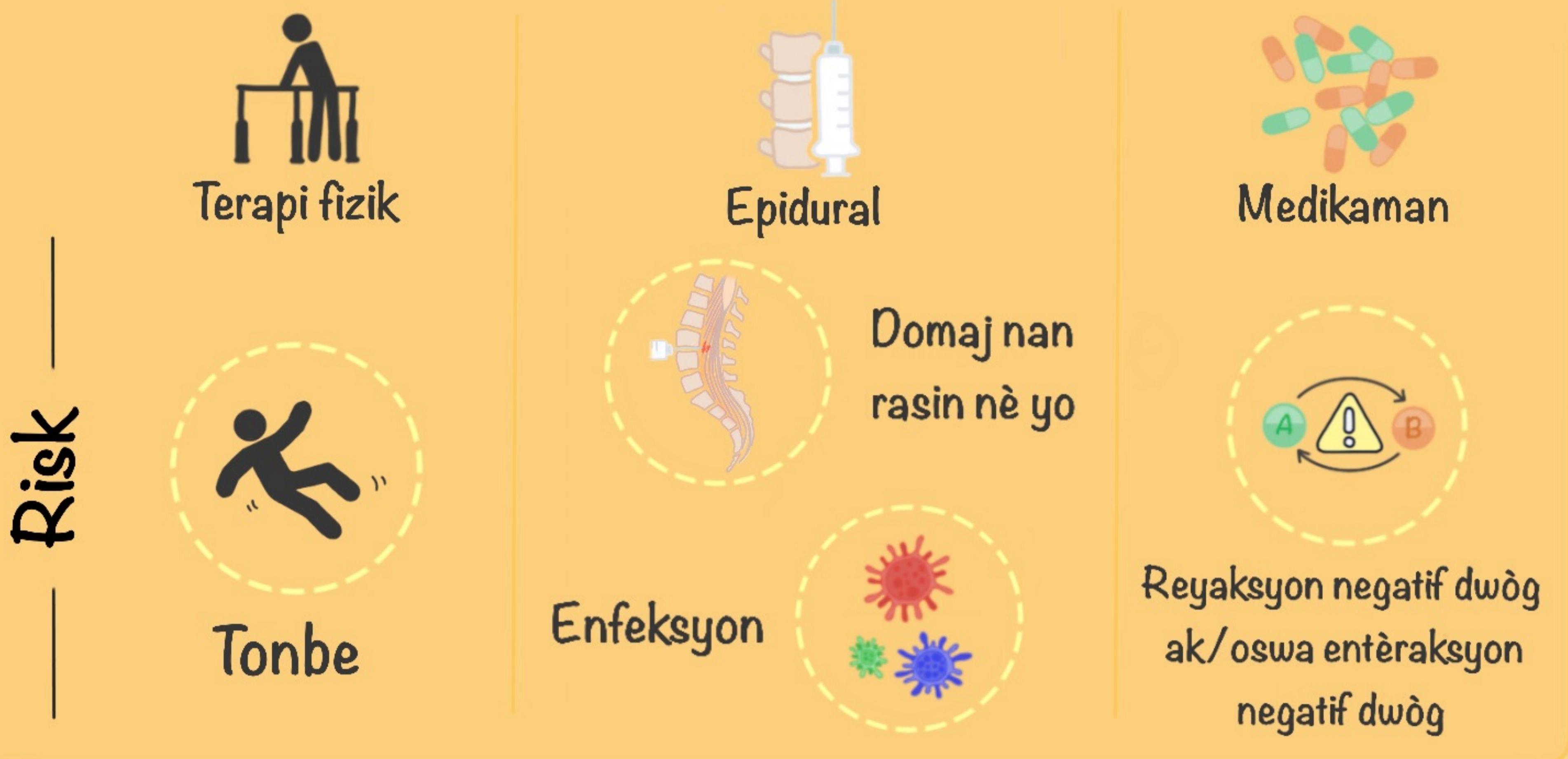
## Tès dyagnostik

Radyografi  
(gade sou bó)

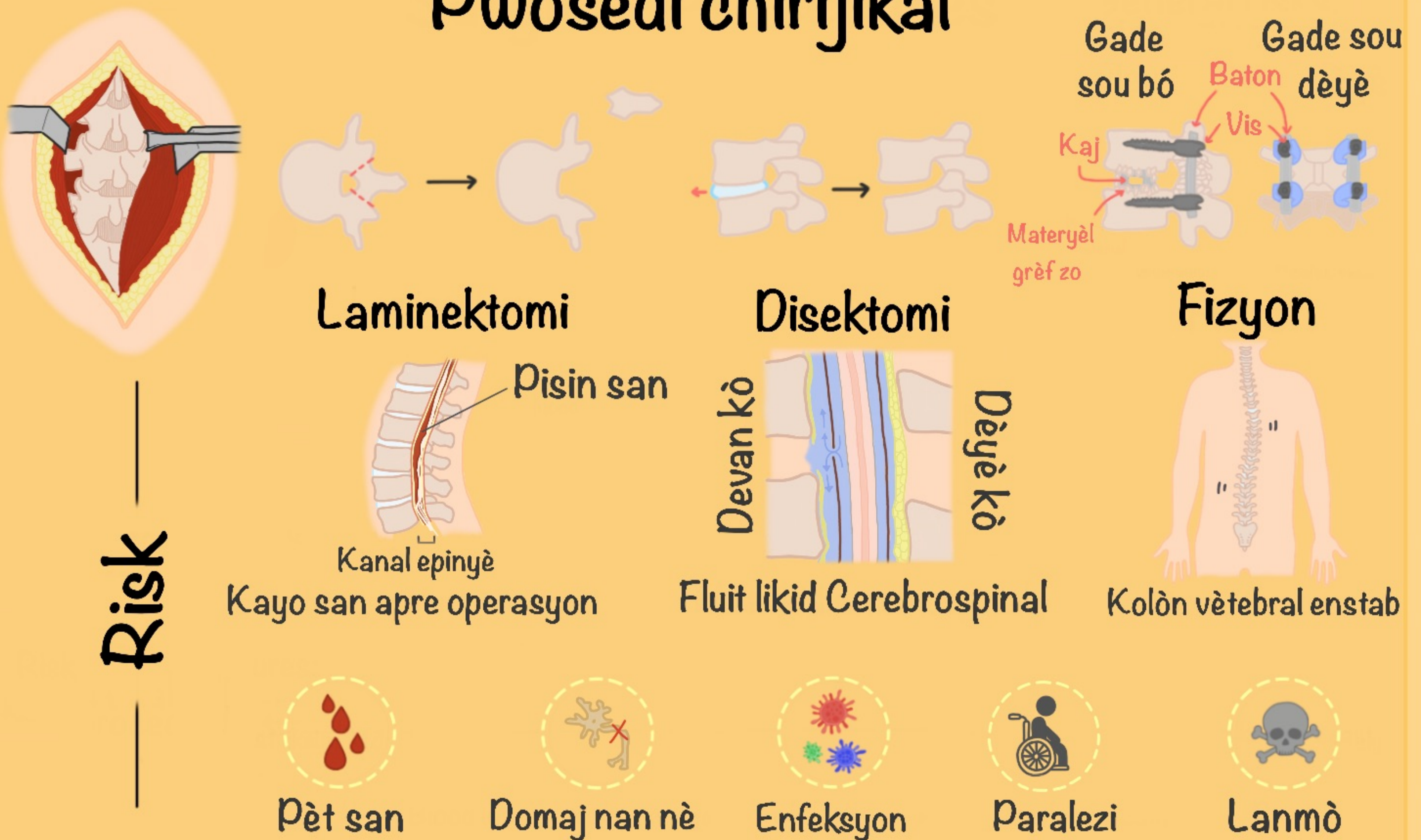


CT eskanè  
(gade sou bó)

# Entèvansyon ki pa chirijikal



# Pwosedi chirijikal

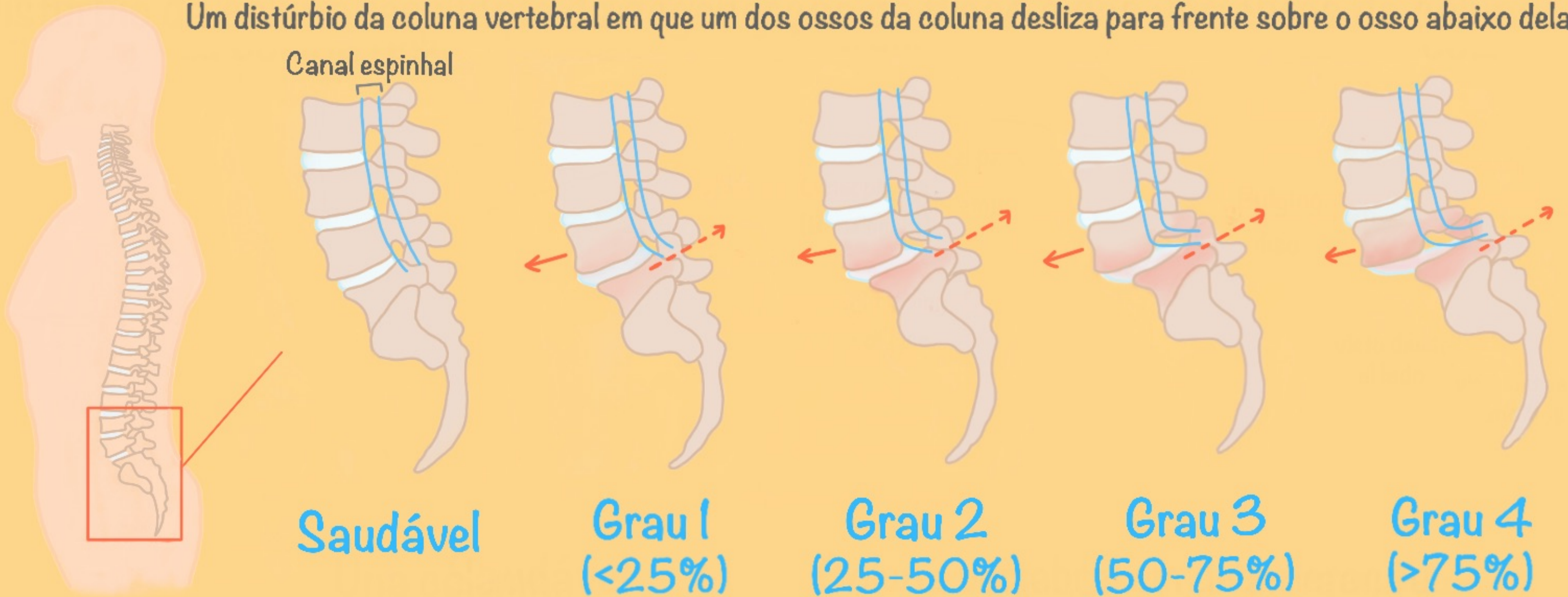


Rekiperasyon ⌚ :

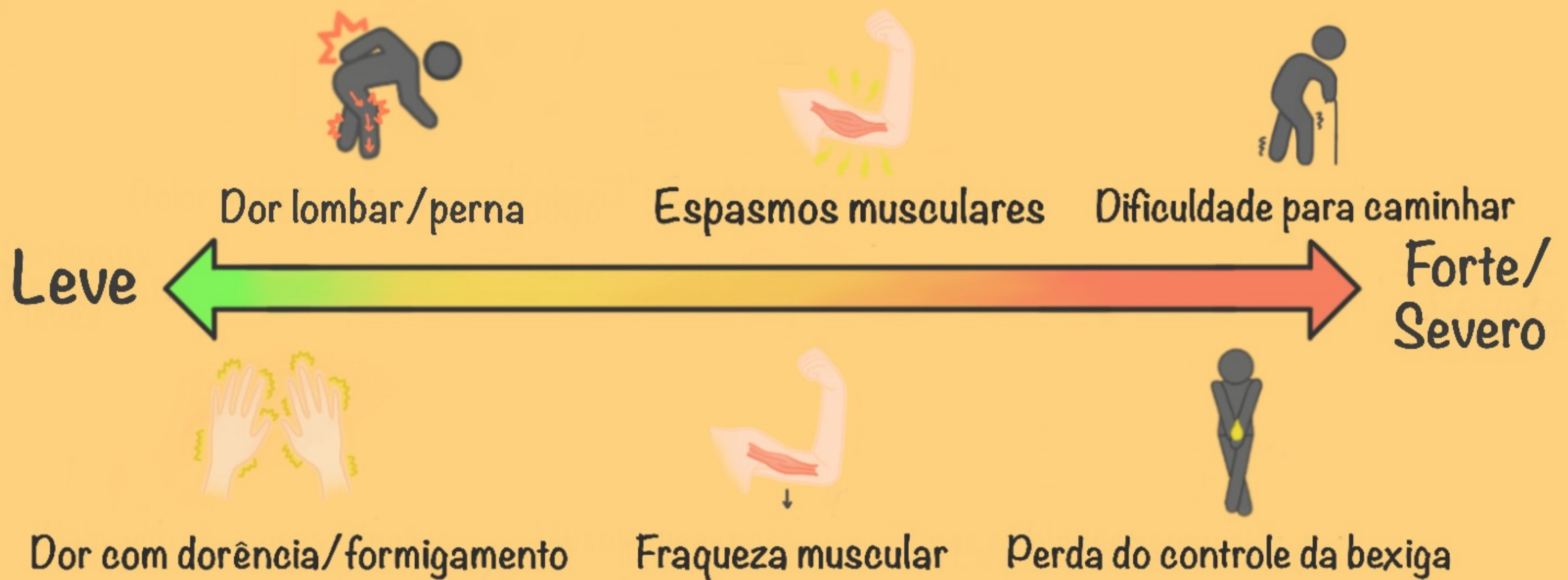


# Espondilolistese

Um distúrbio da coluna vertebral em que um dos ossos da coluna desliza para frente sobre o osso abaixo dela

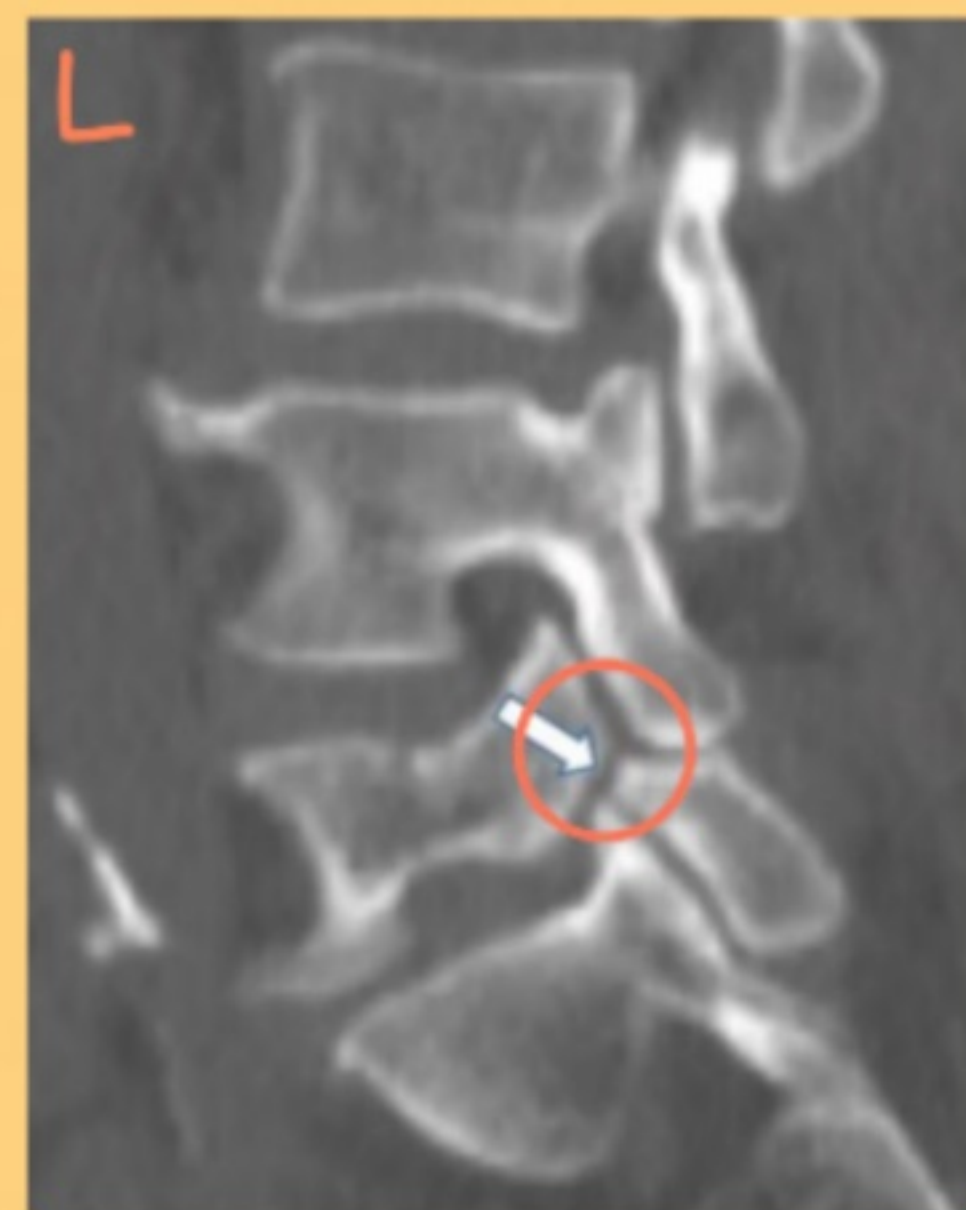
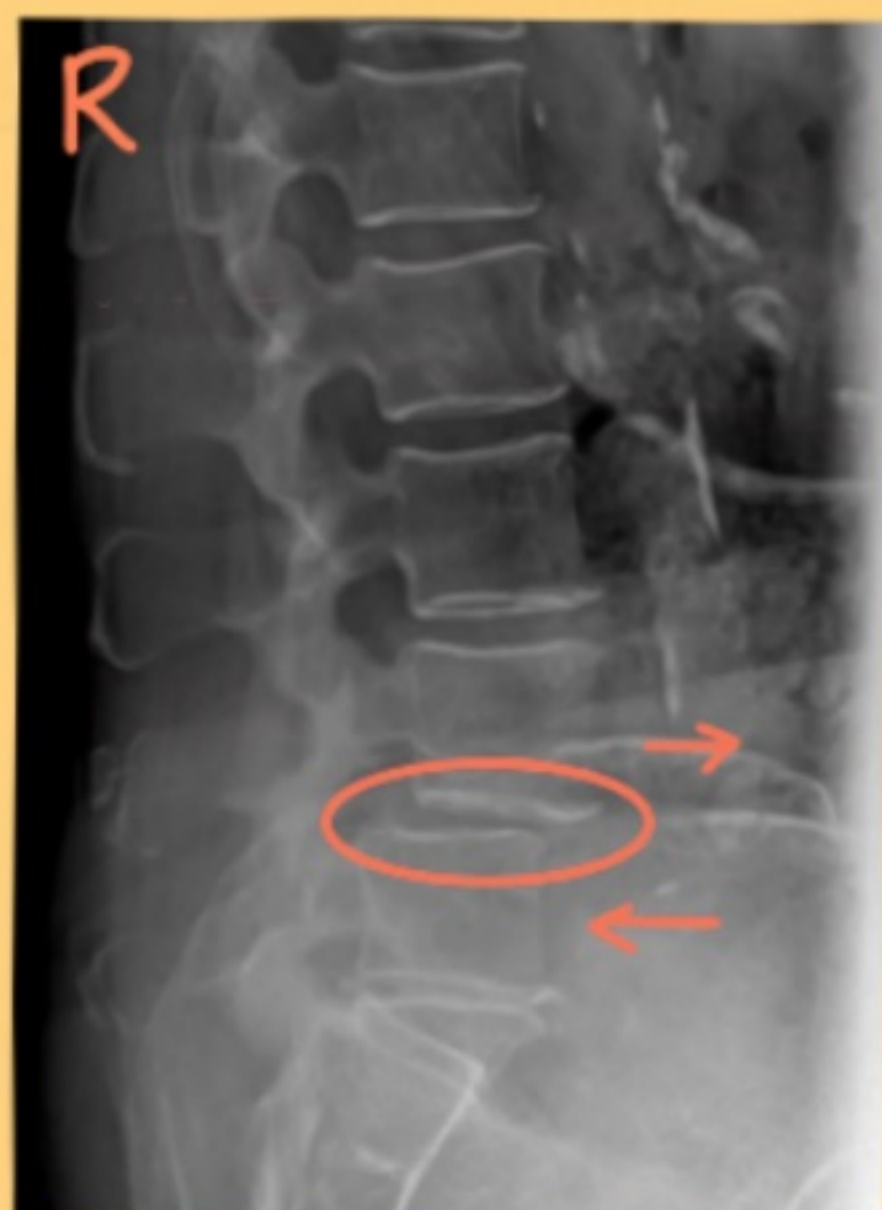
## Sintomas



## Testes de diagnóstico

Raio X  
(vista lateral)

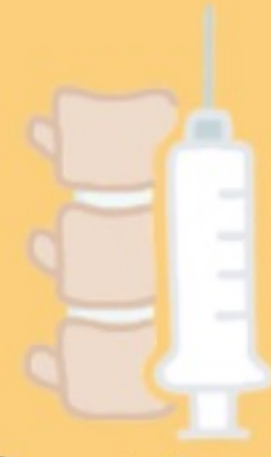

Tomografias  
computadorizadas  
(vista lateral)

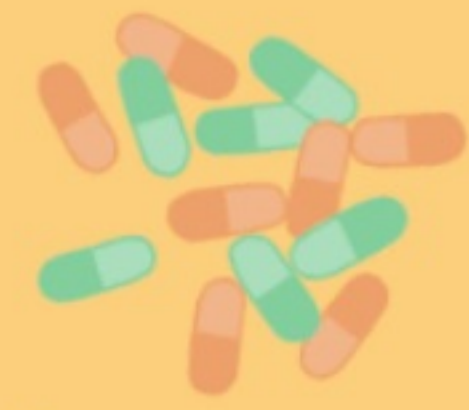# Intervenções Não Cirúrgicas



Fisioterapia



Peridural

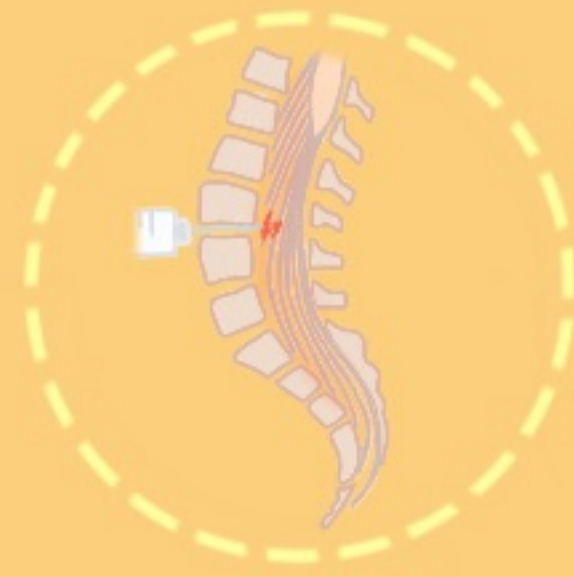

Medicamentos

Riscos

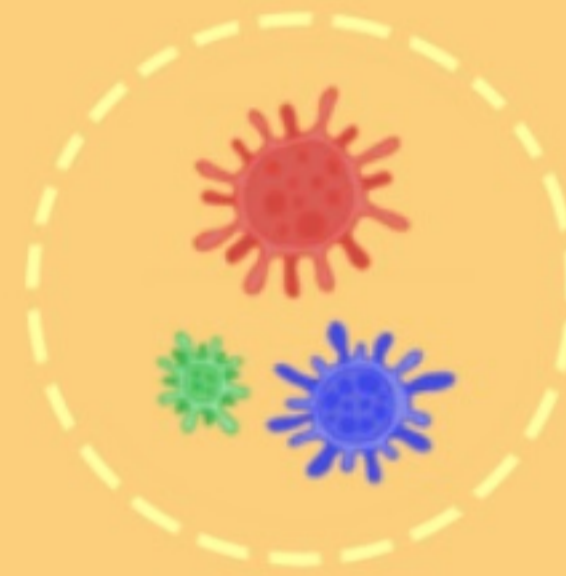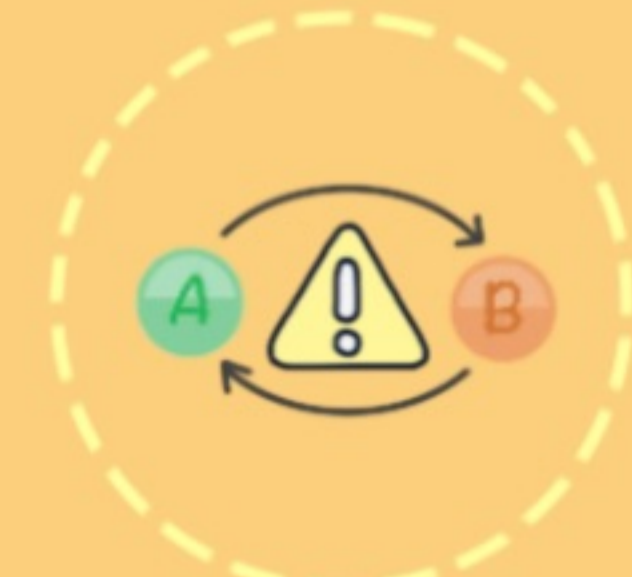


Cataratas



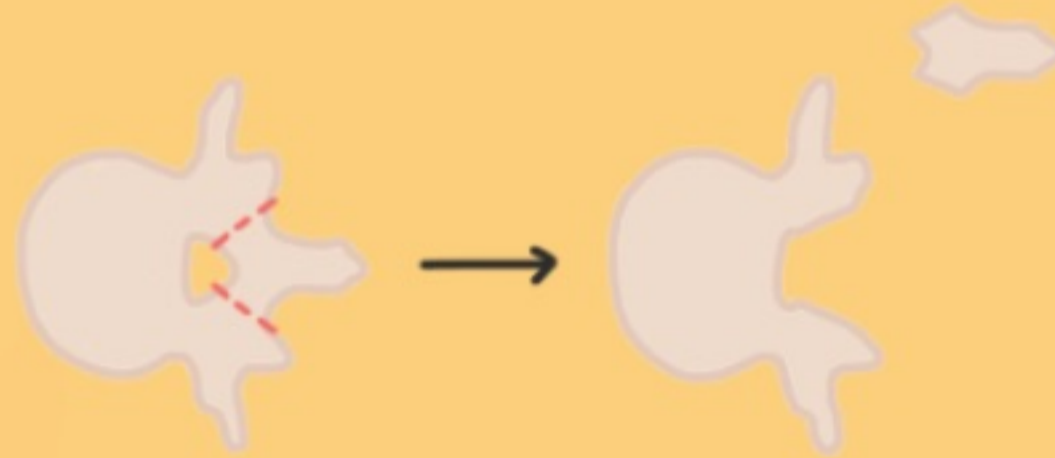
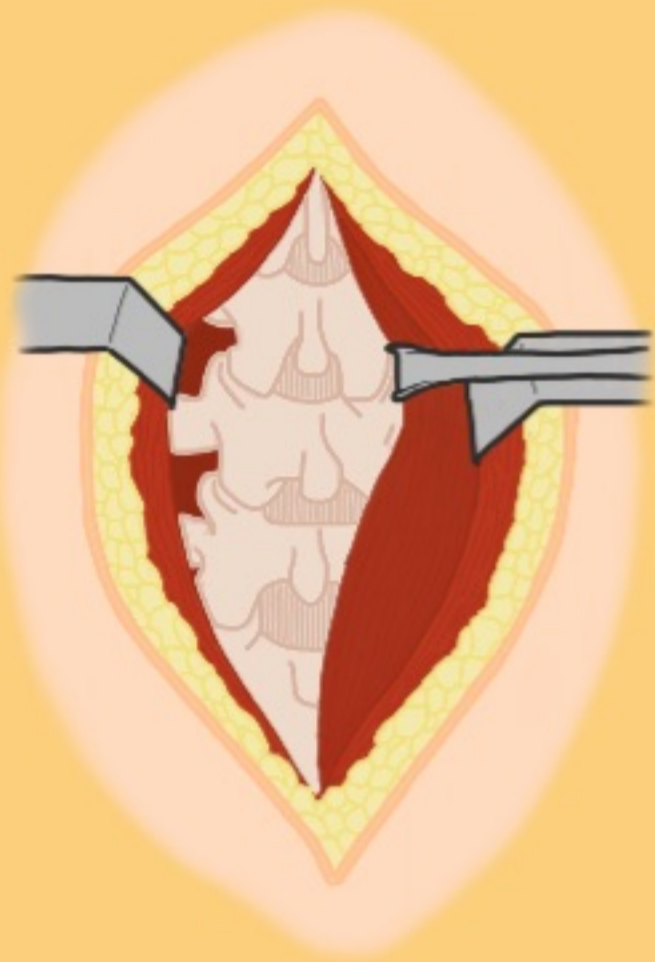
Danos à raiz do nervo

Infecção

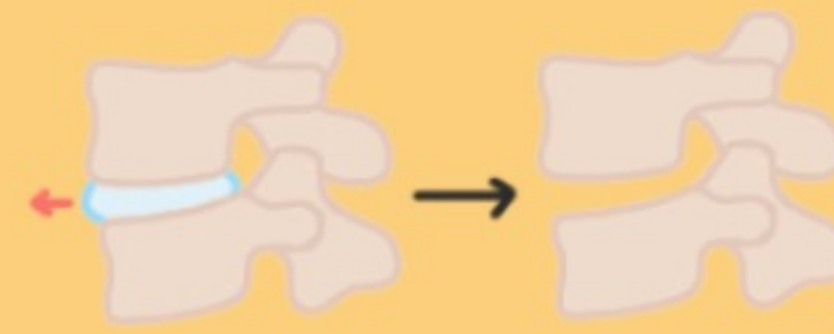

Reações adversas a medicamentos e/ou interações medicamentos

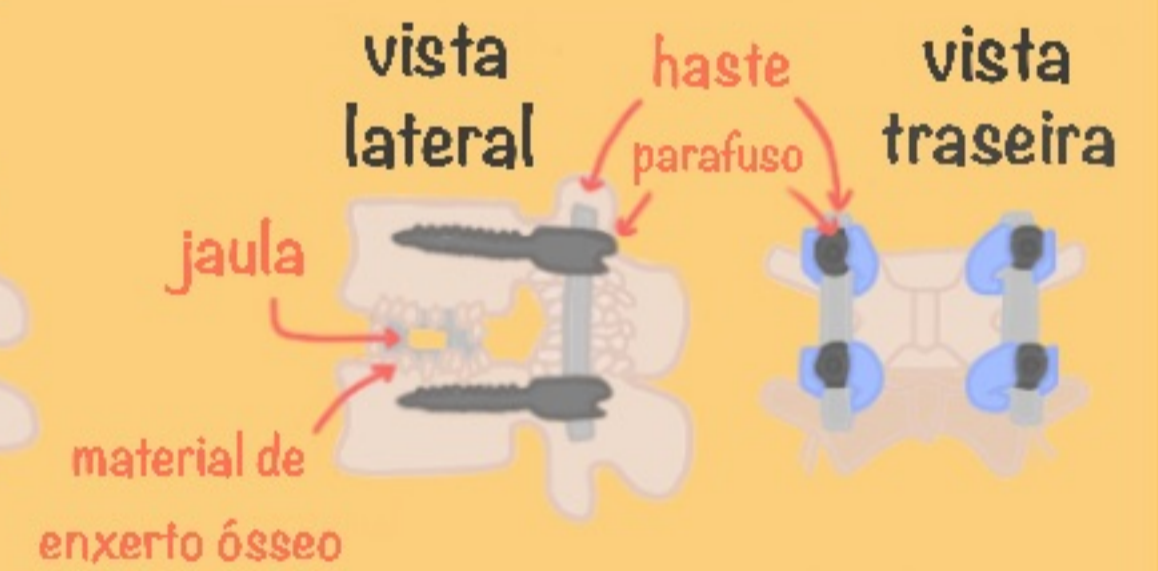
# Procedimentos cirúrgicos



Laminectomia

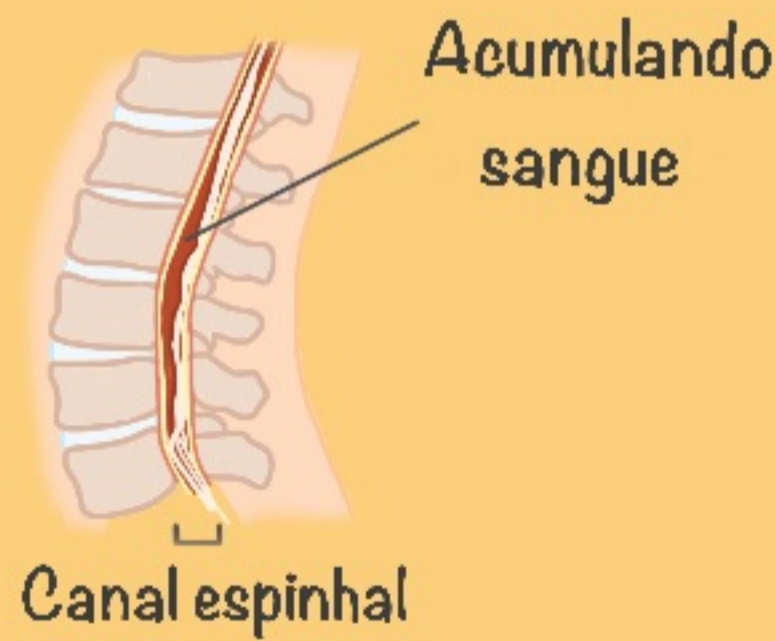

Discectomia

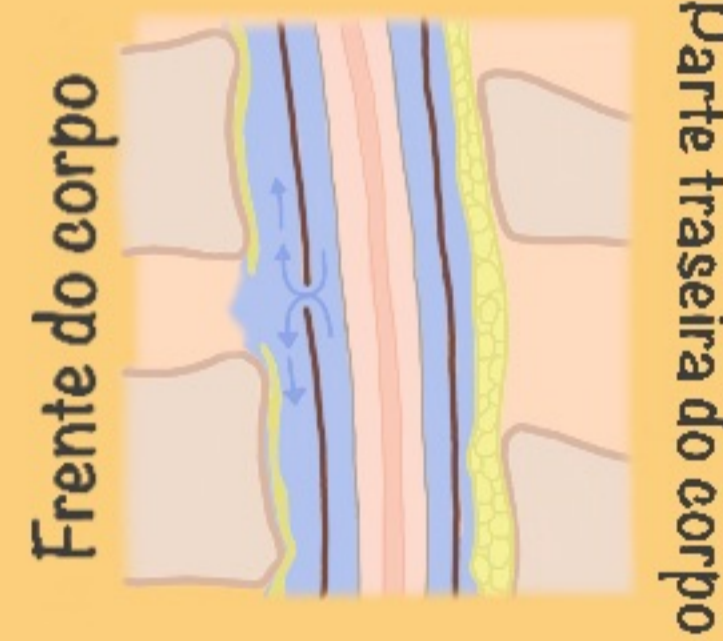


Fusão

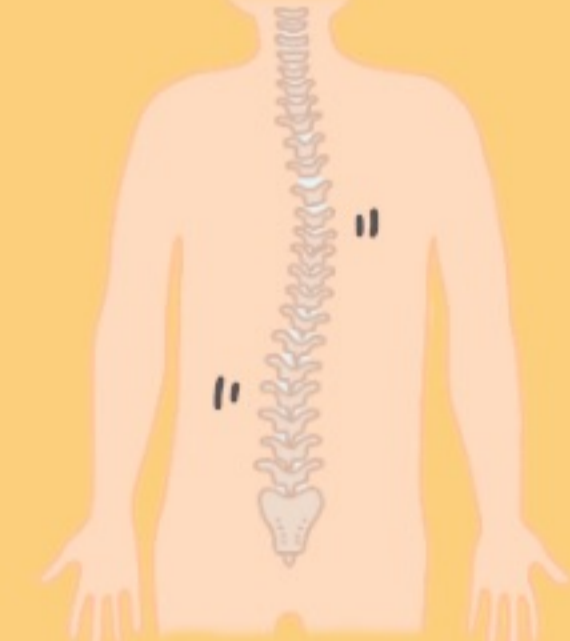
Riscos



Hematoma pós-operatório



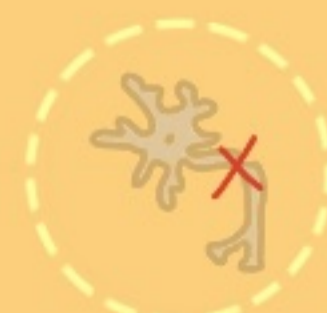Um escape del líquido cerebroespinal



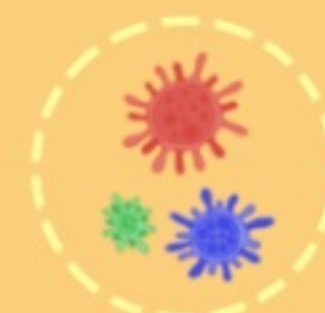Coluna instável



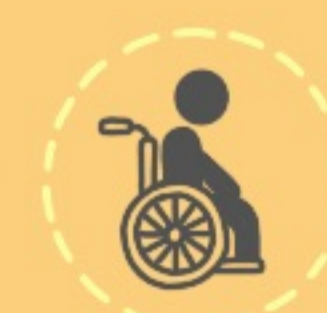Perda de sangue



Danos nos nervos



Infecção



Paralisia



Morte

Recuperação ⌚ :

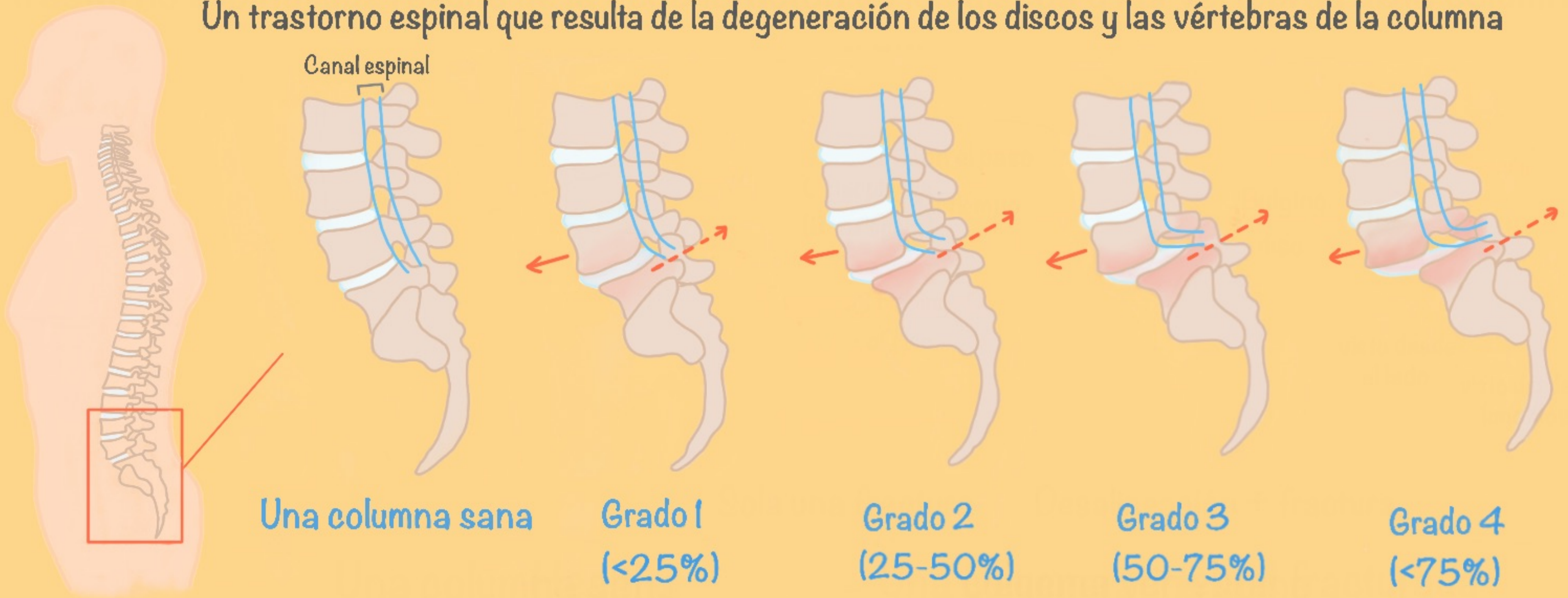
2 semanas



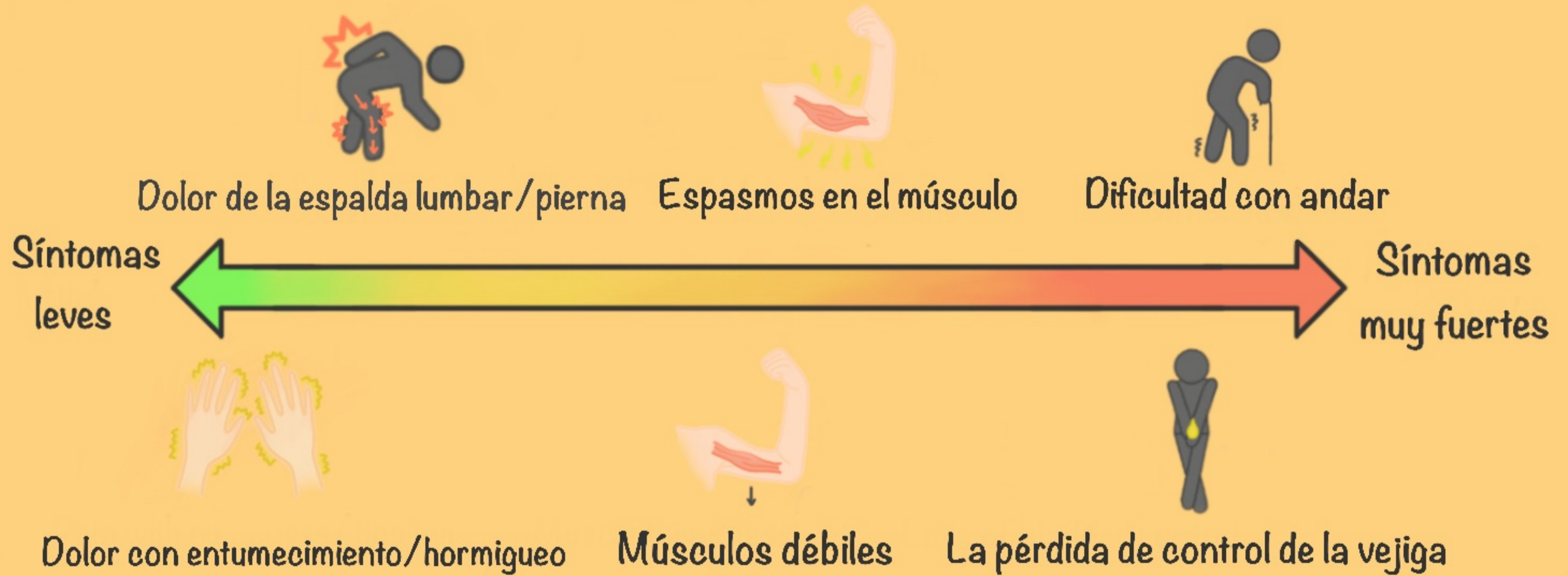6 meses

# Espondilolistesis

Un trastorno espinal que resulta de la degeneración de los discos y las vértebras de la columna

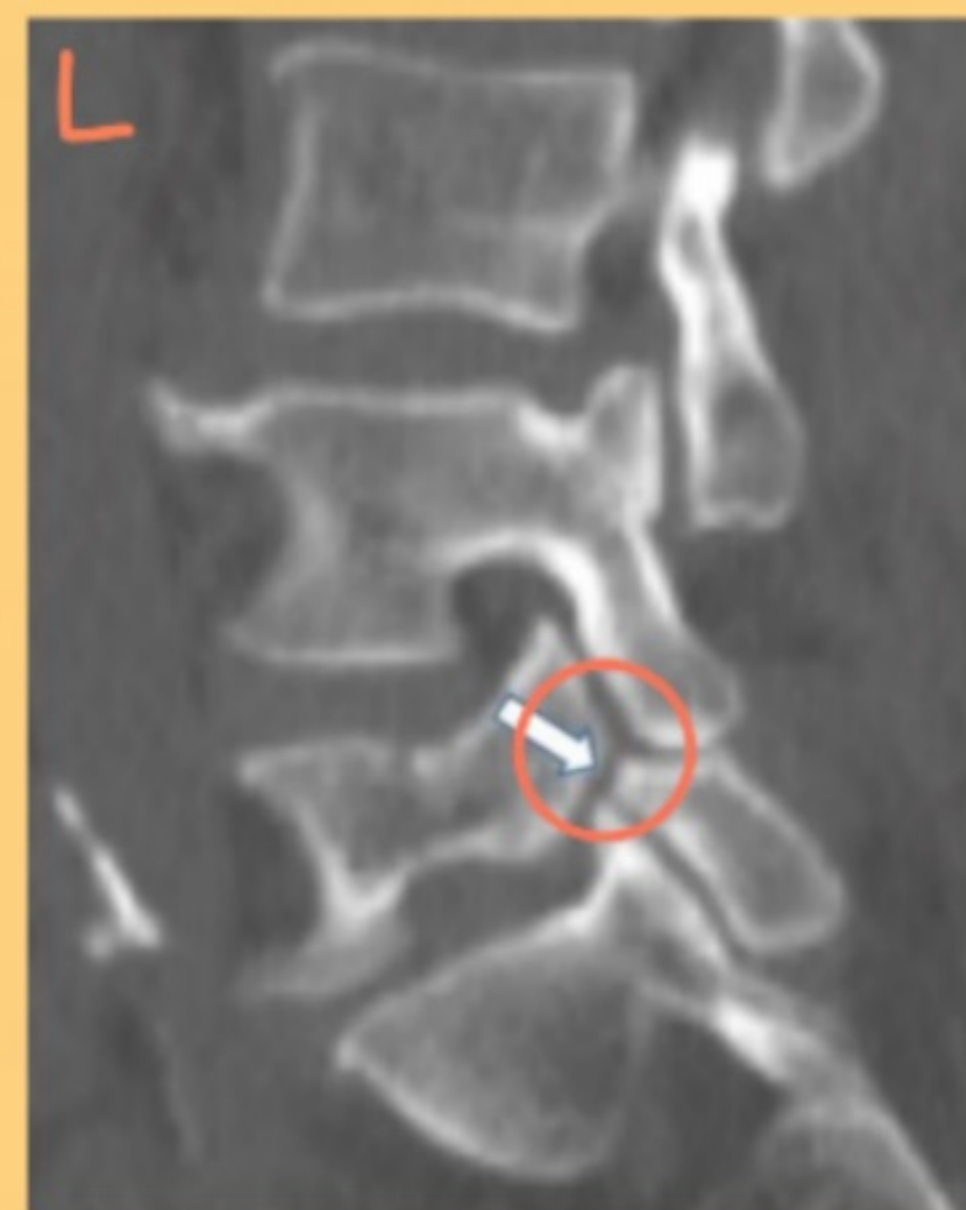
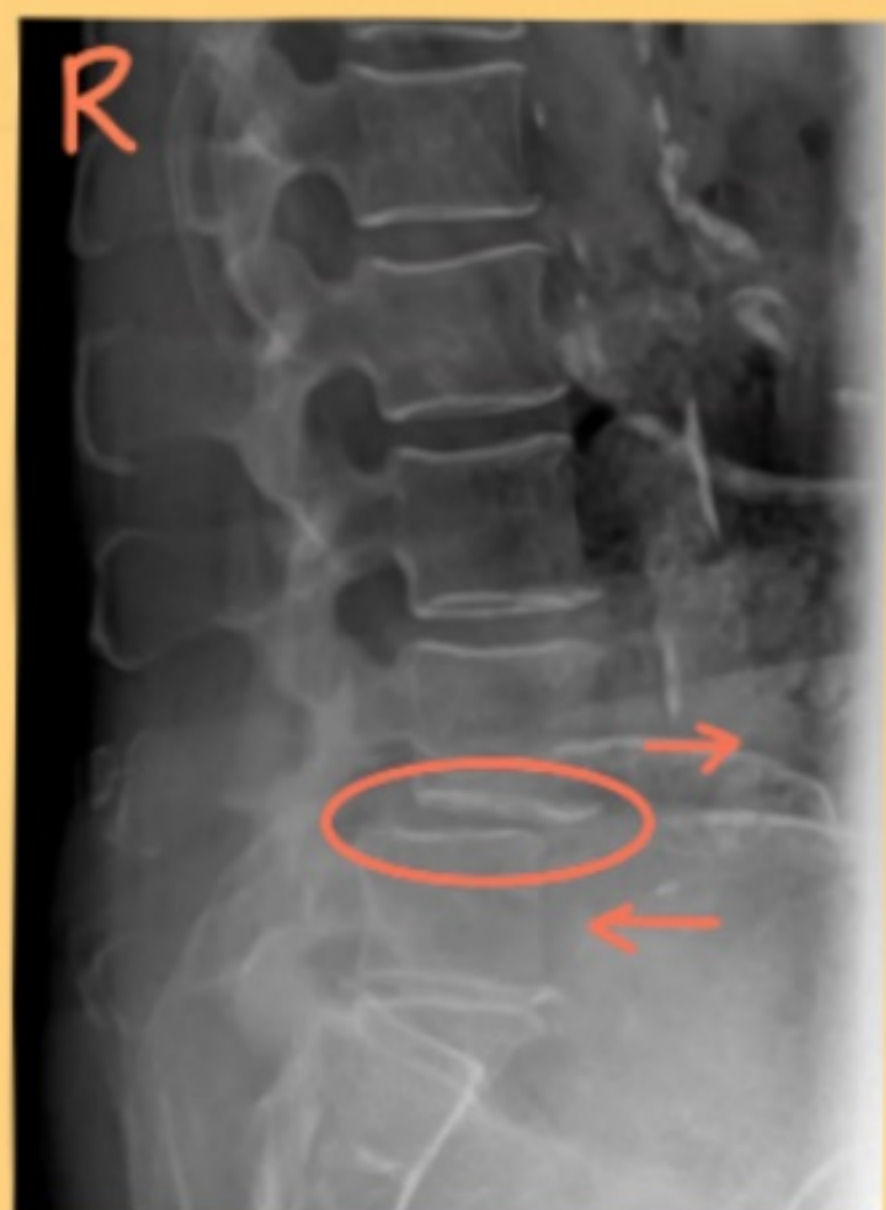
## Síntomas



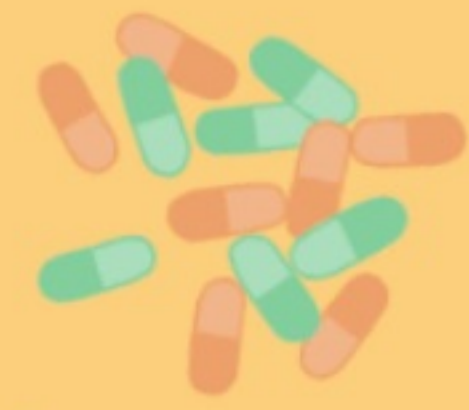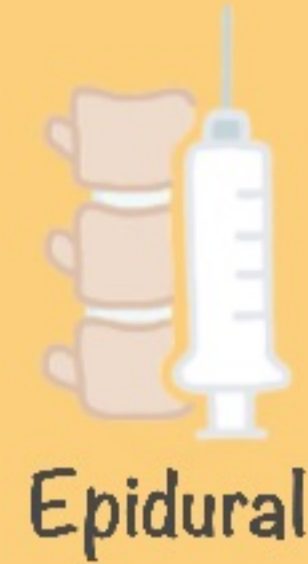## Unos exámenes diagnósticos

Radiografía  
(visto desde  
el lado)

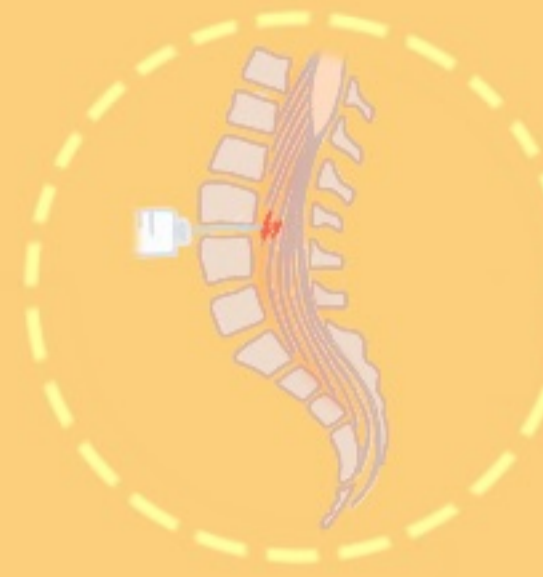


Tomografía  
computarizada  
(visto desde el  
lado)

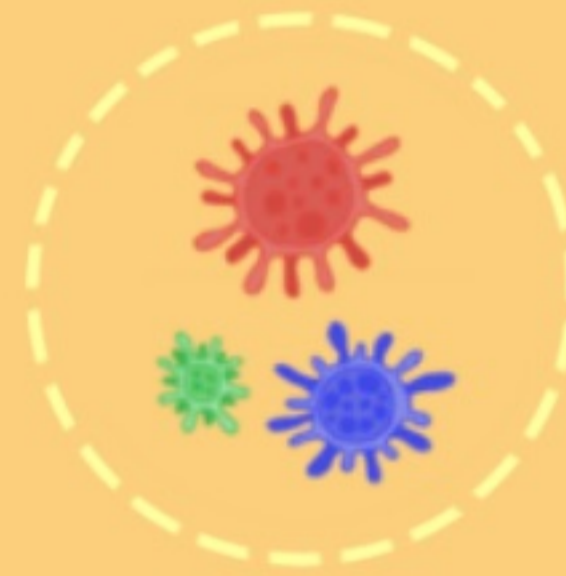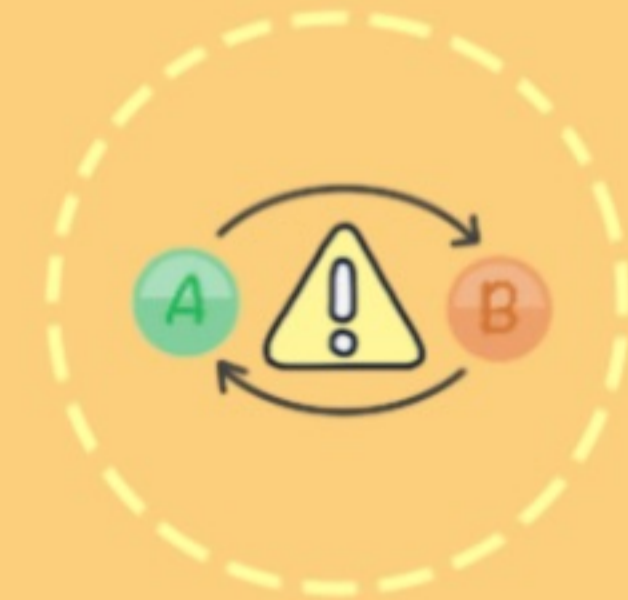
# Intervenciones sin cirugía



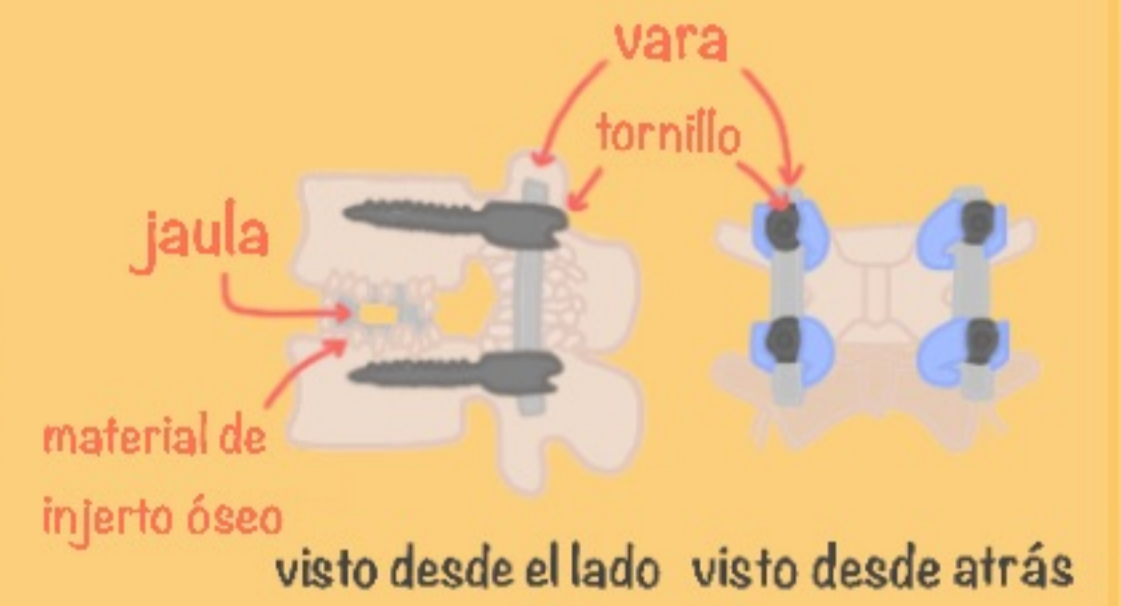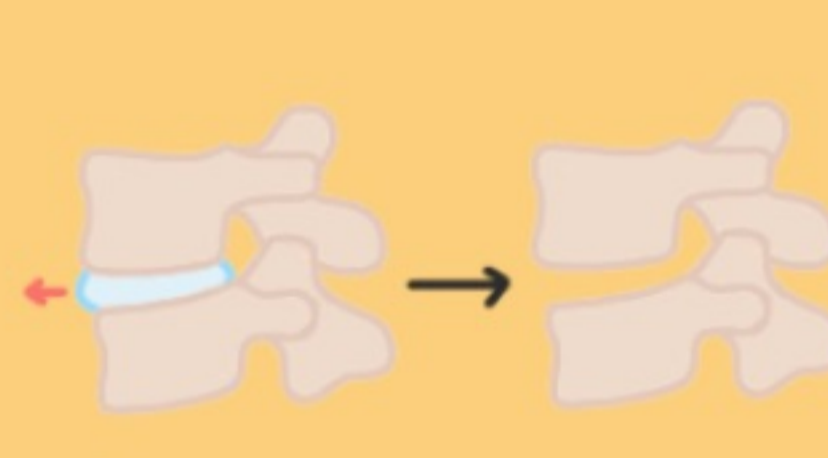
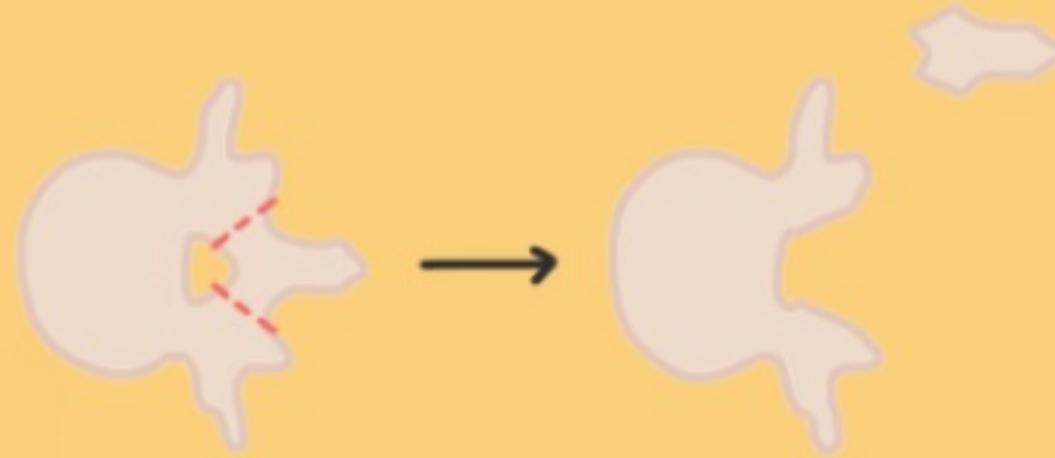
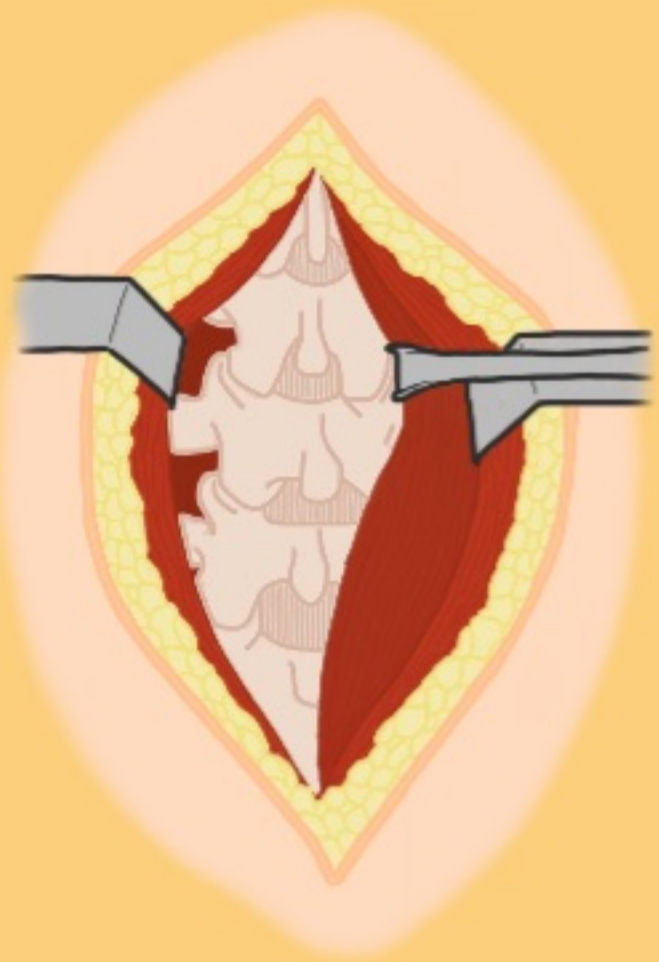
Riesgos



Infección



# Procedimiento Quirúrgico

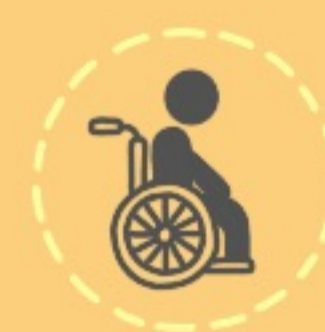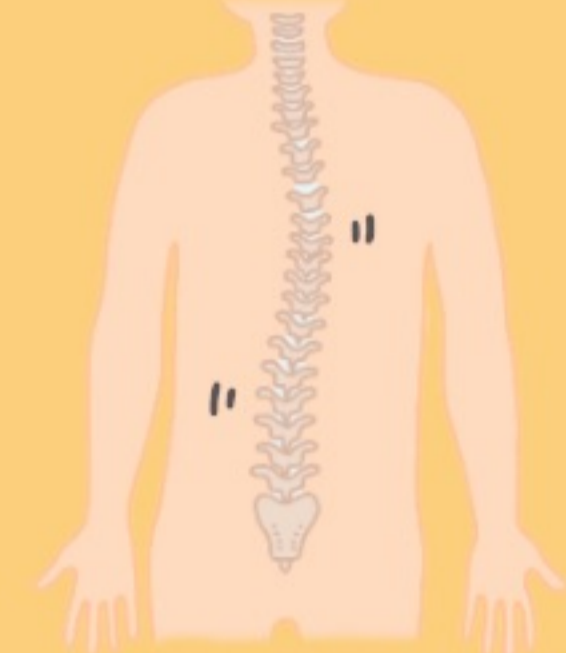
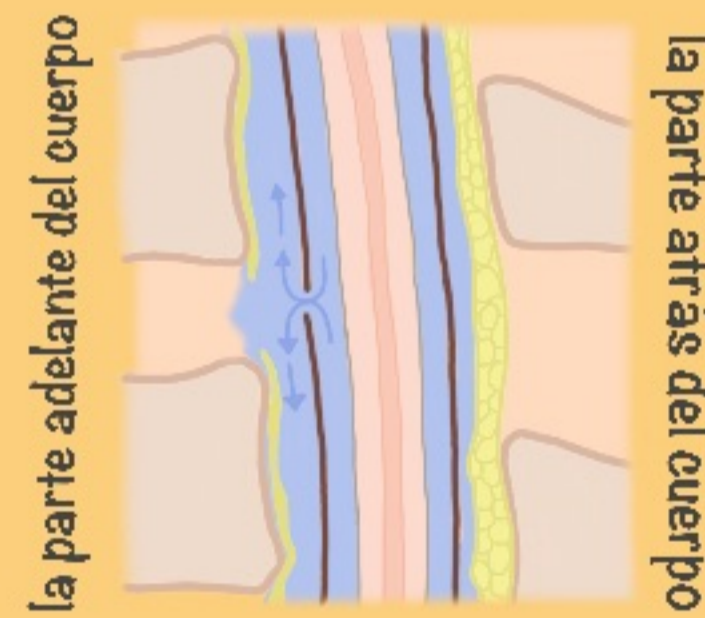

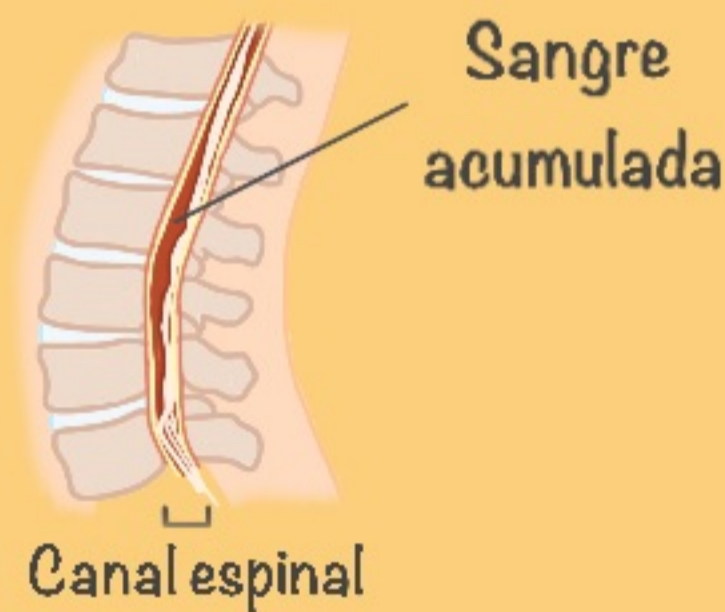
Laminectomía

Discectomía

Fusión

Riesgos



La recuperación 🕒 :

2 semanas



6 meses

