

2017

# Three-dimensional analysis of mandibular landmarks, planes and shape, and the symphyseal changes associated with growth and orthodontic treatment

---

<https://hdl.handle.net/2144/26374>

*"Downloaded from OpenBU. Boston University's institutional repository."*

BOSTON UNIVERSITY

HENRY M. GOLDMAN SCHOOL OF DENTAL MEDICINE

THESIS

**THREE-DIMENSIONAL ANALYSIS OF MANDIBULAR LANDMARKS, PLANES AND  
SHAPE, AND THE SYMPHYSEAL CHANGES ASSOCIATED WITH GROWTH AND  
ORTHODONTIC TREATMENT**

by

**CECILIA M. DELLER**

D.D.S, National University Pedro Henriquez Urena School of Dental Medicine, 2005

Submitted in partial fulfillment of the requirements for the degree of

Master of Science in Dentistry

In the Department of

Orthodontics and Dentofacial Orthopedics

2017

**Reader Approval Page**

Approved by:

First Reader

---

Dr. Goli Parsi, DDS, DScD  
Clinical Assistant Professor, Department of Orthodontics and Dentofacial  
Orthopedics

Second Reader

---

Dr. Melih Motro, DDS, PhD  
Clinical Assistant Professor, Department of Orthodontics and  
Dentofacial Orthopedics

Third Reader

---

Dr. Pelin Karagoz Motro, DDS, MSD, PhD  
Clinical Assistant Professor, Department of General Dentistry

## ACKNOWLEDGEMENTS

I would like to thank God for having directed me in the right way, by always enlighten me every day and giving me strength to move forward; for teaching me that resignation was not an option in my life and that to achieve your goals in life, you need to know how to dream.

I would also like to thank Dr. Goli Parsi for her support of this research project. This study would not have been possible without her fundamental project idea, her support, contribution, and her paramount research and clinical excellence in this field of orthodontics.

I would also like to thank Dr. Melih Motro for his continued support over the past three years. His guidance and clarity were influential throughout my research. I appreciate his efforts tremendously and his willingness to always be there for the residents for anything we need.

I would also like to thank Dr. Kenny Drizen, Dr. Michael Blau, and Dr. John Bendar and his entire family, for believe in me and for supporting me over the past three years. I am very thankful for their amazing advices, and for teaching me great orthodontics. I greatly appreciate their help.

I would also like to thank Dr. David Briss for all his support for the past five years. I sincerely appreciate his knowledge, guidance, advises, and his disposition to always have the residents at heart.

I would also like to thank Dr. Pelin Karagoz Motro for her kindness and supportive nature as a contributing reader of this thesis.

I would also like to thank Dr. Alsulaiman AA, for his statistical expertise. Without his help, the data would have remained unanalyzed and therefore statistically meaningless.

I would also like to thank Jessica Riccobono not only for her enormous help, dedication, and support in this research project, but most important for her unconditional friendship. This project gave me a new sister.

I would like to thank Callahan Dicle, PhD for his enormous help and sincere disposition in this project. Without his help, the shape data would have stayed unanalyzed. Thank you!

I would also like to give a gigantic thanks to the entire faculty in the department of orthodontics at BUGSDM. Since I started working in the department five years ago, I knew a gained a new family. Their knowledge and clinical skill is something that I desire to practice daily. Their personal interest in the patients they treat as well as the residents they teach has had the greatest impression on me.

Additionally, I would also like to thank and congratulate my co-residents, especially Meghan Graham, Sarah Almugairin, and MaryEvan Thacker, for their friendship throughout the last three years. I will miss you tremendously, thank you for all the great memories. I hope that we will take what we have learned thus far as the foundation for our future endeavors. Thank you all.

Finally, I would like to thank my immediate and extended family for their unconditional love, guidance and commitment. Greg, words cannot express how thankful I am. Thank you for your support, and for walking by my side in this wonderful journey. Tata, for being my inspiration, my strength, my greatest counselor, and for your huge help. Justina, I cannot imagine my life without you especially in my first year of residency. Thank you! Camila, you might not understand it yet, but you have been my biggest gift ever. Thank you for being patient with mommy since day one of residency. You make me a better person. Mommy loves you infinite. Dad, mom and the rest of my beautiful family, throughout the ups and downs of my residency you all were a vital support system. Love you all. Whether near or far, you all have always been my biggest “fans,” and I will always be grateful to each of you.

# **THREE-DIMENSIONAL ANALYSIS OF MANDIBULAR LANDMARKS, PLANES AND SHAPE, AND THE SYMPHYSEAL CHANGES ASSOCIATED WITH GROWTH AND ORTHODONTIC TREATMENT**

**CECILIA M. DELLER**

Boston University, Henry M. Goldman School of Dental Medicine, 2017

Dr. Goli Parsi, DDS, DScD, Clinical Assistant Professor, Department of Orthodontics and Dentofacial Orthopedics, Boston University Henry M. Goldman School of Dental Medicine.

## **ABSTRACT**

### **Introduction:**

Mandibular development has been a topic of interest in dentistry, especially to the orthodontists. In treatment planning orthodontic and orthognathic surgery patients, understanding the mandibular shape plays a key role. Morphology is a branch of biology that deals with the study of the form and structures of organisms and their specific structural features. Morphometrics (from Greek “morphe”, meaning ‘shape’ or ‘form’ and “metria”, meaning ‘measurement’) or morphometry refers to the quantitative analysis of form, a concept that encompasses size and shape. Since the introduction of panoramic radiographs, cephalometric radiographs and Cone-Beam Computed Tomography (CBCT), the interest of the variability of mandibular pattern was increased.

### **Objectives:**

- 1) To test reliability of 3D mandibular landmarks, planes of reference and surfaces and assess their correlation to conventional 2D cephalometric measurements.
- 2) To analyze changes in three-dimensional shape of the symphysis due to growth and orthodontic treatment.

**Material and Methods:**

This study was a retrospective analysis of CBCTs of healthy orthodontic patients. A convenience sample of 32 subjects were included, 16 males and 16 females, with mean ages of  $10.6 \pm 1.5$  years and  $15.0 \pm 0.9$  years before and after treatment, respectively. The mean follow-up time was 4.3 years. Subjects with extra-oral and intra-oral examinations free of any craniofacial anomalies, and no observable pathology on panoramic radiograph were included in this study. 15 subjects had Cervical Vertebrae Maturation (CVM) 1 and 17 subjects had Cervical Vertebrae Maturation (CVM) 2 before orthodontic treatment. All subjects had CVM 5 after orthodontic treatment. For the first phase of this study, 3D mandibular landmark identifications were digitized. Planes and landmarks were constructed and compared with conventional 2D mandibular measurements: mandibular plane angle, gonial angle, corpus length, and ramus height. For the second phase of the study, the segmentation of the mandibles was carried out on DICOM files created from CT data set. Mandibles were isolated by progressively removing surrounding structures with sculpting tools. Pearson correlation and paired t-test were performed to test for correlation and differences between 2D and 3D measurements, respectively. Statistical analysis was performed using SAS 9.4 Software. Finally, MorphoJ software (Version 2.0, [www.flywings.org.uk](http://www.flywings.org.uk)) was used for symphysis shape analysis; and Discriminant Function Analysis (DFA) between pre-treatment and post-treatment was used for statistical analysis of the symphysis.

**Results:**

- When correlating between 2D and 3D images, we found statistical significant positive correlation between 2D and 3D post-treatment ramus height (P-value  $<0.01$ ), pre-treatment corpus length (P-value  $<0.01$ ), post-treatment corpus length (P-value  $<0.05$ ), and pre-treatment gonial angle (P-value  $<0.05$ ).

- When comparing pre-treatment and post-treatment measurements, we found statistical significant differences in 2D ramus height (mean difference=3.8, SD= 0.8, P-value=0.001), 3D ramus height (mean difference=3.8, SD=1.1, P-value= 0.002), 2D corpus length (mean difference=3.1, SD=0.6, P-value <0.01), and 3D corpus length (mean difference=4.7, SD=0.7, P-value <0.01).
- When comparing the symphysis shape between pre-treatment and post-treatment, we found that there is no statistically significant difference between pre-treatment and post-treatment symphysis (P-value= 0.99).

### **Conclusions:**

- These results demonstrated statistically significant positive correlation between certain 2D and 3D measurements.
- Pre-treatment and post-treatment differences in 2D and 3D measurements showed consistent results.
- Symphysis shapes do break out as distinctly separate groups, but the differences between the means is small.
- CBCT craniometric measurements are very accurate and can be used for craniofacial analysis.

# Table of Contents

Title Page.....	i
Reader’s Approval.....	ii
Acknowledgements.....	iii
Abstract.....	v
Table of Contents.....	viii
List of Tables.....	ix
List of Figures.....	x
<b>REVIEW OF THE LITERATURE.....</b>	<b>1</b>
HYPOTHESIS & OBJECTIVES.....	5
<b>MATERIALS &amp; METHODS.....</b>	<b>6</b>
SAMPLE SELECTION:.....	6
INCLUSION CRITERIA:.....	6
STATISTICS:.....	13
<i>Intraexaminer Reliability:</i> .....	13
<b>RESULTS.....</b>	<b>14</b>
CORRELATION AND INDEPENDENT T TESTS (MEANS AND STANDARD DEVIATIONS): .....	.....
A. <i>Correlation between 2D and 3D images</i> .....	16
B. <i>T-test comparing differences between pre-treatment and post-treatment measurements in 2D and 3D</i> .....	16
<b>DISCUSSION.....</b>	<b>22</b>
STRENGTHS:.....	24
LIMITATIONS:.....	24
RECOMMENDATIONS AND FUTURE DIRECTIONS: .....	24
CONCLUSIONS: .....	24
<b>REFERENCES.....</b>	<b>26</b>
<b>CURRICULUM VITAE.....</b>	<b>29</b>

## List of Tables

<b>TABLE 1: DIGITIZED LANDMARK</b>	<b>7</b>
<b>TABLE 2: LANDMARK IDENTIFICATION ON CEPHALOMETRIC DEFINITIONS IN 2D AND 3D</b>	<b>7</b>
<b>TABLE 3: STUDY LINEAR AND ANGULAR MEASUREMENTS IN 2D AND 3D</b>	<b>8</b>
<b>TABLE 4: DESCRIPTION OF CONSTRUCTED MANDIBULAR PLANES</b>	<b>10</b>
<b>TABLE 5: STUDY DESCRIPTIVE STATISTICS</b>	<b>15</b>
<b>TABLE 6: PEARSON CORRELATION BETWEEN 2D AND 3D IMAGES</b>	<b>16</b>
<b>TABLE 7: T-TEST COMPARING THE VARIABLES BETWEEN PRE-TREATMENT AND POST-TREATMENT MEASUREMENTS IN 2D AND 3D</b>	<b>16</b>

**LIST OF FIGURES**

**FIGURE 1: CONSTRUCTED MANDIBULAR LANDMARKS IN 3D ..... 9**  
**FIGURE 2: CONSTRUCTED MANDIBULAR PLANES.....11**  
**FIGURE 3: VIEW OF THE ISOLATED MANDIBLE..... 12**  
**FIGURE 4: MANDIBULAR ISOLATED SHYMPHISIS SHAPE POINTS ..... 12**  
**FIGURE 5: PRINCIPAL COMPONENTS AND PERCENTAGE OF VARIANCE .....17**  
**FIGURE 6: PRINCIPAL COMPONENT 1 OF THE WHOLE SAMPLE .....18**  
**FIGURE 7: PRINCIPAL COMPONENT 2 OF THE WHOLE SAMPLE .....19**  
**FIGURE 8: PRINCIPAL COMPONENT 3 OF THE WHOLE SAMPLE .....20**  
**FIGURE 9: DISCRIMINANT FUNCTION ANALYSIS DIFFERENCE BETWEEN PRE-  
TREATMENT AND POST-TREATMENT (A AND B) SYMPHYSIS SHAPE .....21**

## **REVIEW OF THE LITERATURE**

Mandibular development has been a topic of interest in dentistry, especially to the orthodontists. In treatment planning orthodontic and orthognathic surgery patients, understanding the mandibular shape plays a significant role.

Since the introduction of panoramic radiographs, cephalometric radiographs and Cone-Beam Computed Tomography (CBCT), the interest in the variability of mandibular pattern has increased. The earliest contributions to mandibular morphology were aimed at documenting populations and sex differences in mandibular morphology. Also, mandibular measurements were used to explore and develop new techniques for orthodontic treatments<sup>1,2</sup>. Studies done on panoramic radiographs, cephalometric radiographs and CBCT's, have shown slight differences in the morphology of the mandibular foramen, canals, and mental foramen<sup>3</sup>. In the same manner, differences in mandibular condyles and ramus, and variations in the vertical height have been found in men and women<sup>4</sup>.

Evaluations of the shape of the mandible around the pubertal growth spurt by using lateral cephalograms showed statistically significant growth changes, especially during the post pubertal period, indicating a decrease in the gonial angle with age. Also, sex-related differences in shape were observed at all ages, male subjects showing a more rounded shape of the mandible than female subjects<sup>5</sup>. Moreover, mandibular divergency (normodivergent, hypodivergent and hyperdivergent), in conjunction with mandibular shape has been studied evaluating lateral cephalograms. Mandibular shape was different in all the classes, especially a large variation was noticed in hyperdivergent girls compared to normodivergent girls<sup>6</sup>.

In the same manner, mandibles with vertical growth patterns were related with a symphysis with large height, small depth, large ratio between symphysis height and depth, decreased ramus height and width, smaller mandibular depth, increased gonial angle, and decreased mandibular arc angle in contrast to mandible with a horizontal growth pattern. Differences between males and females were also found; especially in ramus height, ramus width and mandibular depth which are found to be greater in males than females<sup>7</sup>. In 1922, Hellman<sup>8</sup>, working on skulls, stated that Class II division I malocclusion skulls exhibited a more acute gonial angle than skulls with excellent occlusion. This would account for the mandible being in a more distal relationship to the maxilla. Likewise, Renfro<sup>9</sup> in 1941 compared the facial patterns of individuals with Class I and Class II division I malocclusions, using means of angular measurements. He also found that the mandible is not underdeveloped, but is posteriorly positioned and the gonial angle is smaller when Class II division I malocclusions were compared to Class I malocclusions.

Class III patients undergo changes in occlusal pattern because occlusal morphology is dictated by mandibular size and length. Possibly, mandibular form is influenced by various intrinsic factors, e.g. genetics, and extrinsic factors, e.g., muscular factors, in addition to growth and teeth eruption<sup>10</sup>. Also, Burdi and Spyropoulos<sup>11</sup> consider that prenatal growth patterns of the human mandible are complex and that abnormal mandibular shape may be directly associated with altered masseter muscle morphologic features.

Evaluating panoramic radiographs, Silva & Fuentes<sup>12</sup> in 2004, studied morphometry in mandibular condyle and ramus; variations in the vertical height were found in men and women. Ramon Fuentes et al., in 2008, also studied the mandibular shape in different facial types by analyzing panoramic x-rays. In contrast to previous studies they found that the mandibular and

mental foramen showed no significant sex differences and the mandibular foramen location was stable on the right and left<sup>13</sup>.

Studies of soft-tissue profiles have been conducted to evaluate the relationship between soft tissue and skeletal patterns. A relationship between the skeletal and soft-tissue components showed that the anterior skeletal and dental landmarks can be used to envision about 50% the soft-tissue profile shape<sup>14</sup>. Another study by Demetrios J. Halazonetis<sup>15</sup> in 2007 using lateral cephalograms, found that the lower lip seemed to be an area of high variability between subjects, to an extent that would perhaps not be expected. Such variability might be due to postural factors and might also be because the lower lip is affected by not only the position of the mandibular incisor, but also the maxillary incisor, especially in patients with large overbites and overjets.

Studies on CBCT's have been done to study the shape of the mandible. Elizabeth Nicholson and Katerina Harvati (2005)<sup>16</sup> used three-dimensional geometric morphometric to compare human mandible shapes between "Neanderthal" mandibular traits (Middle and Late Pleistocene western Eurasian fossil specimens) with geographically different recent humans (samples of modern human from American Museum of Natural History). They concluded that modern human mandibular shape shows considerable geographic patterning, with some aspects of mandibular morphology reflecting a climatic gradient (cold vs. warm), the retromolar gap was found to be related to increased mandibular size in modern humans. Also, in the overall shape of the mandible, they found that the Arthric, European and North Asian populations had short and wide mandibles. These groups with large and wide mandibles were characterize by 1) an antero-posteriorly short and medio-laterally wide mandible with laterally positioned gonion; 2) an anteriorly projecting lower part of the symphysis and supero-inferiorly taller corpus and mental

foramen. On the other hand, the Southeast Asian and Central and South American groups were characterized by 1) a long and narrow mandible with a medially positioned gonion; 2) a more posteriorly receding symphysis; 3) a more superiorly positioned gonion and gnathion, indicating a supero-inferiorly shorter corpus; and 4) a greater antero-posterior distance between the canine and the mental foramen.

Furthermore, comparing anatomical skeletal and dental landmark identification on lateral cephalograms and 3-dimensional CBCT, using dried human skull, showed that the standard deviation (SD) of six landmarks using lateral cephalograms, were more than 1mm and only three were less than 0.5mm. On the other hand, all SD's of the twenty-seven 3-dimensional CBCT landmarks were less than 1mm and only five were more than 0.5mm, demonstrating that jaw and teeth landmarks identification using CBCT's were more accurate<sup>17</sup>.

Several different superimposition techniques are recommended for 3D data sets derived from CBCT scans; landmark-based, surface-based or voxel-based superimposition of anatomical structures that are deemed to be stable throughout treatment. Gkantidis et al.<sup>18</sup> compared five superimposition techniques in non-growing patients who underwent rapid palatal expansion (3-point registration, anterior cranial base and foramen magnum, both zygomatic arches and one zygomatic arch) and found that anterior cranial base and foramen magnum superimposition technique was the most accurate followed by anterior cranial base and both zygomatic arches technique, while one zygomatic arch and 3-point registration superimposition techniques were the least accurate.

Lascalea et al.<sup>19</sup> in 2002, compared 13 direct measurements on 8 human skulls vs those made on a CBCT scan using Multiplanar Reconstructed (MPR) images (i.e., axial, sagittal, and coronal sections). They found that the CBCT images were smaller than those made directly on the skull. These differences, however, were not statistically significant. It should be noted that this 2002 study used New Tom QR DVT 9000, Marburg, Germany (one of the first CBCT units), with a very low resolution and 2 mm slice thickness.

In 2008, Periago et al.,<sup>20</sup> studied 23 dry skulls using Dolphin 3D (Dolphin Imaging, Chatsworth, California) and found that most measurements were statistically different from direct measurements of the same distances. Sixty percent of the measurements varied by more than 1 mm, and 10% varied by 2 mm. The investigators stated that this difference was not clinically significant, concluding that measurements resulting from the CBCT scans were sufficiently accurate for craniofacial analysis.

Hilgers and coworkers<sup>21</sup> in 2005 compared direct measurements of the temporomandibular joint region vs those made on the multiplanar reconstructed (MPR) images of a CBCT scan (iCAT) with 0.4 mm slice thickness of 25 dry skulls, and found that CBCT measurements were accurate and reproducible.

## **HYPOTHESIS AND OBJECTIVES**

Specific Aim 1: To test reliability of 3D mandibular landmarks, planes of reference and surfaces and assess their correlation to conventional 2D cephalometric measurements.

Specific Aim 2: To analyze changes in three-dimensional shape of the symphysis due to growth and orthodontic treatment.

The null hypotheses are that there is no difference in 3D mandibular landmarks identification when compared to 2D conventional mandibular landmarks identification, and there is no symphyseal changes associated with orthodontic treatment and growth.

## **MATERIALS AND METHODS**

### ***Sample Selection:***

This study was a retrospective analysis of CBCTs of healthy orthodontic patients. A convenience sample of 32 subjects were included, 16 males and 16 females, with mean ages of  $10.6 \pm 1.5$  years and  $15.0 \pm 0.9$  years before and after treatment, respectively. The mean follow-up time was 4.3 years.

### ***Inclusion criteria/Clinical Exam:***

- Healthy individuals free of any craniofacial anomalies
- Extraoral and intraoral hard and soft tissue examinations: no significant findings (lumps, abscess, inflammation, etc.)

### **Radiographically:**

- Pre-treatment CBCT showing CVM 1-2 and post-treatment CBCT showing CVM 5 or higher
- No pathology on panoramic radiograph

Pre-treatment and post-treatment CBCT scans were screened based on our inclusion criteria, using Mimics™ Research 18.0 Software (Materialise NV Technologielaan, Leuven, Belgium).

For the first phase of this study, 3D mandibular landmark identifications and reliability, the following landmarks were digitized (see table 1). Enhancing tools and maximum zoom were used to be sure each point was marked properly, in all three planes of space (i.e., axial, sagittal, and coronal). The 3D anatomic landmarks follow the same path of the traditional 2D measurements:

Sigmoid Notch Right and Left	Deepest point of sigmoid notch
Coronoid Process Right and Left	Most superior point of coronoid process
Mental Foramen Right and Left	Most inferior point of mental foramen
Genial Tubercle	The most posterior point of the genial tubercle
Lingula Right and Left	Most inferior point of the lingula
Midpoint of the Lingula	Midpoint of lingula right and left
Gonion Right and Left	Most inferior border of gonion
Midpoint of Gonion	Midpoint of gonion right and left
Constructed Gonion	Bisection of the angle formed by lines tangent to the posterior ramus and inferior border of the mandible
Pogonion	The most antero-superior point of pogonion

Table 1: 3D digitized landmarks.

<b>Landmark</b>	<b>Definition</b>
Articulare	The point of intersection of the external dorsal contour of the mandibular condyle and the temporal bone
Gonion	The most inferior and posterior point of the mandibular angle
Sigmoid Notch	A concavity on the superior surface of the mandibular ramus between the coronoid and condyloid processes
Constructed Gonion	Located by bisecting the angle formed by lines tangent to the posterior ramus and inferior border of the mandible
Gnathion	Midpoint between the most anterior and inferior point on the bony chin
Menton	The most inferior point of the mid-mandibular suture
Orbitale	The lowest point on the lower edge of the cranial orbit
Porion	The point on the skull located at the upper

	margin of each ear canal (external auditory meatus, external acoustic meatus)
Lingula	Triangular bony projection or ridge on the medial surface of the rams of the mandible, immediately superior to the mandibular foramen.
Mental Foramen	One of two foramina (openings) located on the anterior surface of the mandible
Genial tubercle	Projection of bone on the posterior aspect of the mandible in the midline

Table 2: Landmark Identification on cephalometric definitions.

<b>Linear and angular measurements</b>	<b>Landmarks</b>
Ramus height (R/L)	2D: Ar-Go
	3D: Sigmoid notch-constructed gonion
Corpus length (R/L)	2D: Go-Gn
	3D: Genial tubercle-constructed gonion
Mandibular plane angle (R/L/) (MP)	2D: FH-Go-Me
	3D: FH → Or (R), Or (L), Po (R) Lingula mental foramen plane/Sigmoid notch lingula plane (R/L)
Gonial angle (R/L)	2D: Ar-Go-Me
	3D: Sigmoid notch lingula plane: Sigmoid notch (R), lingula (R/L) MP: Lingula mental foramen plane (R) and lingula (L)

Table 3: Linear and angular measurements, and mandibular landmarks in 2D and 3D.

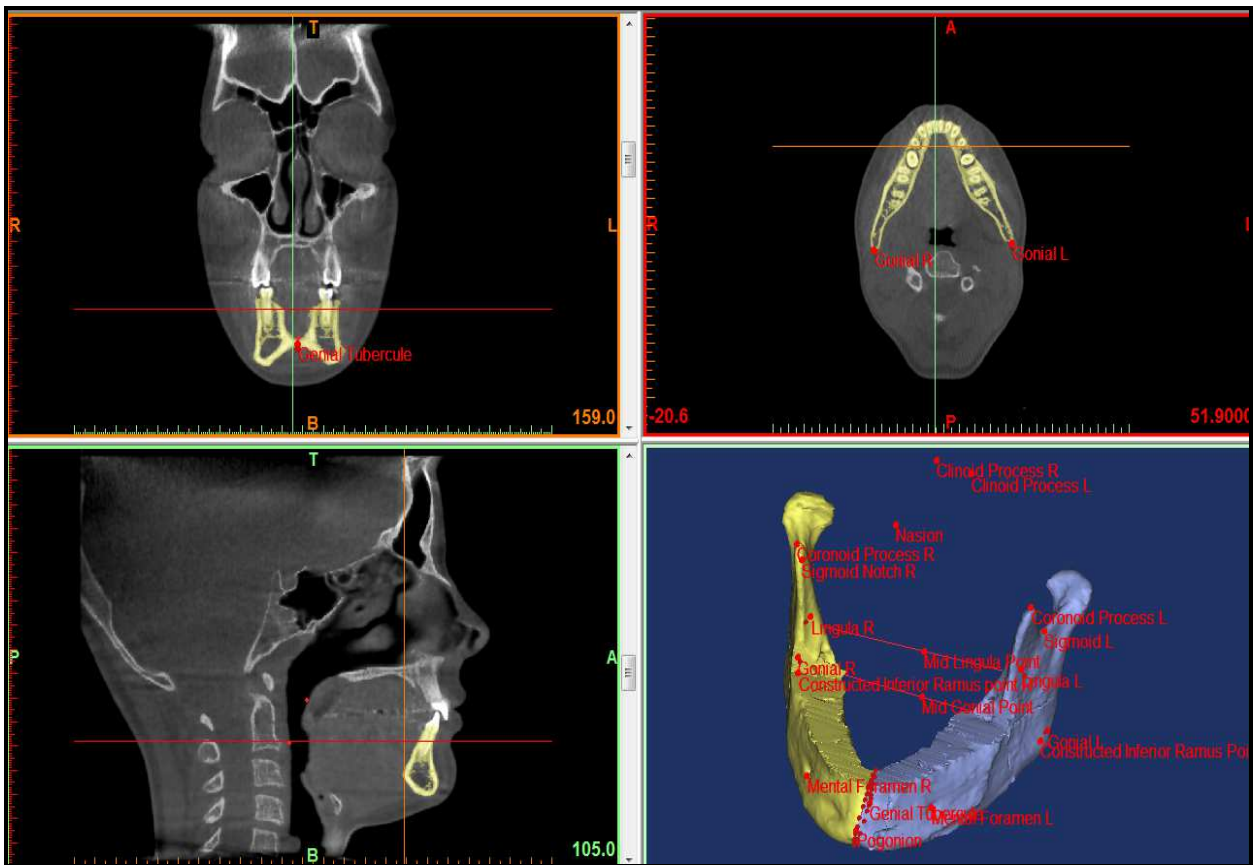


Figure 1: Constructed mandibular landmarks in 3D. With the software used, a suitable slice can be freely selected for landmark identification on sectional images. When a landmark is identified on a slice image, it can be marked automatically on all other slice images.

Planes were constructed and compared with conventional 2D mandibular measurement; mandibular plane angle, gonial angle, corpus length, and ramus height.

Constructed planes	Landmarks used to construct the planes
Mid mandibular plane	<ol style="list-style-type: none"> <li>1) Genial tubercle</li> <li>2) Mid gonial point</li> <li>3) Mid lingula point</li> </ol>
Left ramus plane	<ol style="list-style-type: none"> <li>1) Coronoid process left</li> <li>2) Sigmoid notch left</li> <li>3) Mental foramen left</li> </ol>
Right ramus plane	<ol style="list-style-type: none"> <li>1) Coronoid process right</li> <li>2) Sigmoid notch right</li> <li>3) Mental foramen right</li> </ol>
Sigmoid notch lingula plane	<ol style="list-style-type: none"> <li>1) Sigmoid notch right</li> <li>2) Lingula right</li> <li>3) Lingula left</li> </ol>
Symphysis plane	<ol style="list-style-type: none"> <li>1) Mid lingula point</li> <li>2) Genial tubercle</li> <li>3) Pogonion</li> </ol>
Lingula mental foramen plane	<ol style="list-style-type: none"> <li>1) Lingula left</li> <li>2) Lingula right</li> <li>3) Mental foramen right</li> </ol>

Table 4: Description of constructed planes.

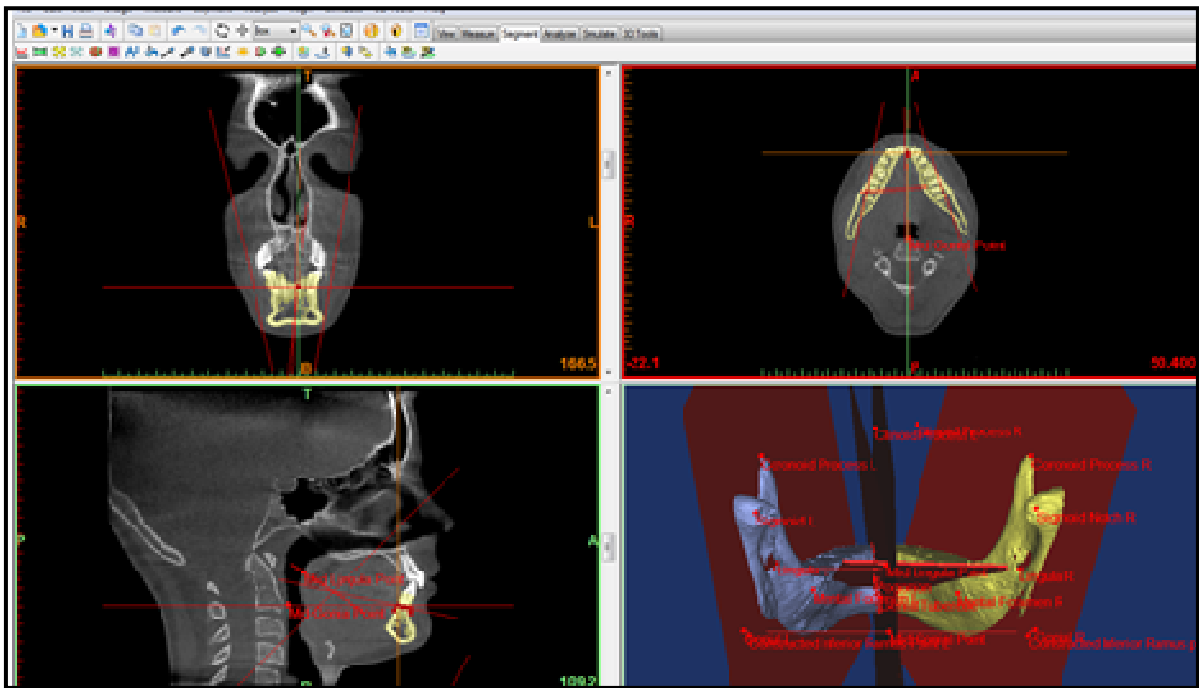


Figure2: Constructed mandibular planes.

For the second phase of the study, the segmentation of the mandible was carried out on DICOM files created from CT data set. Mandibles were isolated by progressively removing surrounding structures with sculpting tools. The results were saved into a “.CSV” file and were copied to an excel spreadsheet. On segmentation, we also used MATLAB Distributed Computing Server Software 2017 (The MathWorks, Inc. Natick, Massachusetts), to convert 3D symphyseal shape data into 2D data.

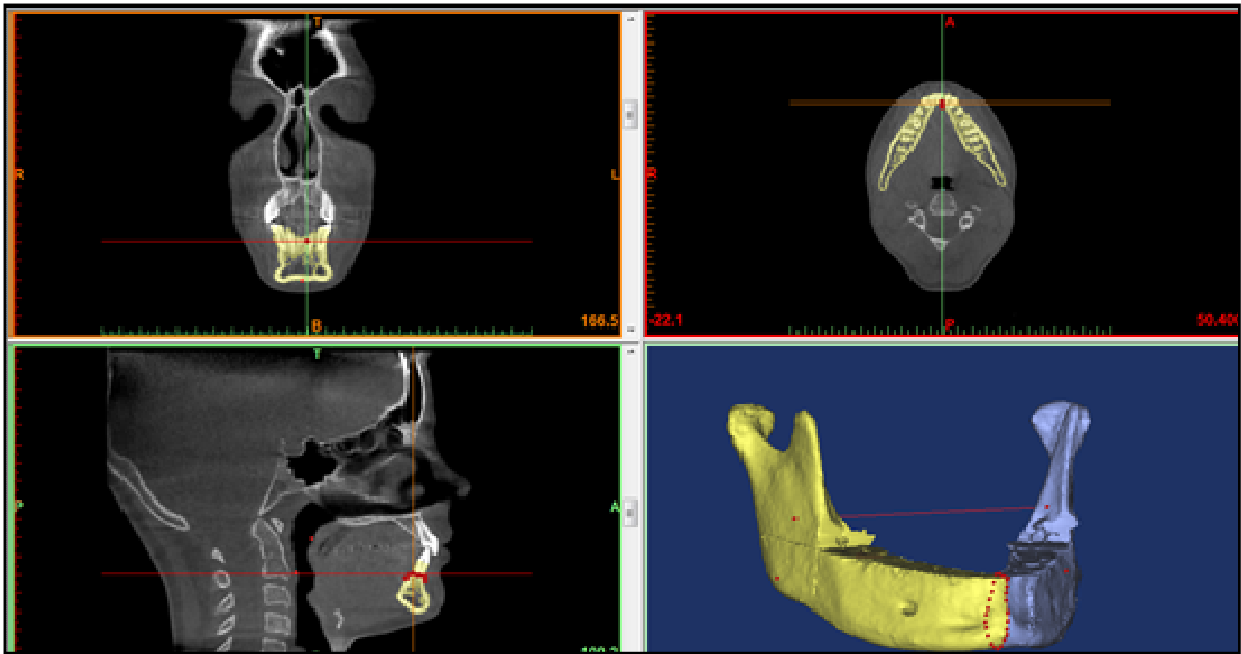


Figure 3: View of the isolated mandible.

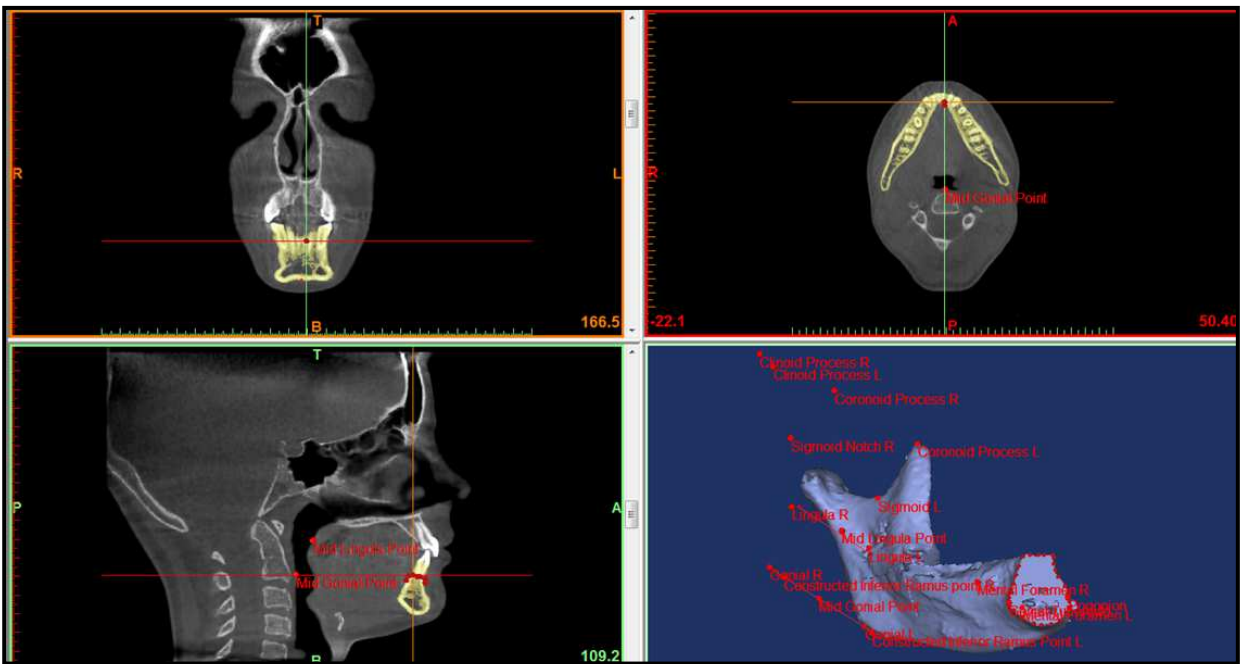


Figure 4: Cross section of the symphysis (isolated shape points).

Finally, symphysis isolated shape change was assessed using geometric morphometric software after segmentation of mandible from pre-treatment and post-treatment CBCT scans (MorphoJ: an integrated software for geometric morphometrics. Version 2.0, [www.flywings.org.uk](http://www.flywings.org.uk)).

## STATISTICS

Data collected were exported to SAS 9.4 Software for statistical analysis. Descriptive statistics and comparison of total measurements between the two samples (pre-treatment and post-treatment) using independent samples t-test were performed. Test statistics with p-values equal to or less than 0.05 were considered statistically significant. All 3D measurements were carried out on DICOM files created from CT data set so that surface area measurements of shape analysis could be performed. Mandibles were isolated by progressively removing surrounding structures with sculpting tools. Discriminant Function Analysis between pre-treatment and post-treatment was used for statistical analysis of the shape of the symphysis between pre-treatment and post-treatment groups.

### *Intra-examiner Reliability:*

To assess the intra-examiner reliability, CBCT data of 5 patients were segmented and landmarks were digitized under the same conditions, by the same operator, 6 weeks after the completion of the first segmentation and landmarks digitization. Differences in 3D coordinates and mandibular areas were evaluated as method errors, and then compared with the natural variance of the whole sample. An intraclass correlation analysis was performed to show the reliability between the two readings and intra-examiner reliability for all the variables range from 0.87 to 0.99%. The 3D landmarks used were found to be very reliable and reproducible, especially coronoid process,

sigmoid notch, lingula, and mental foramen. The least reliable were genial tubercle, and constructed gonion, but the statistical results were enough to demonstrate their reliability.

## **RESULTS**

When correlating 2D and 3D images, we found statistical significant positive correlation between 2D and 3D pre-treatment ramus height (P-value =0.01), post-treatment ramus height (P-value < 0.0001), pre-treatment corpus length (P-value 0.0003), post-treatment corpus length (P-value 0.04), pre-treatment gonial angle (P-value <0.0001), and post-treatment gonial angle (P-value=0.05). However, no statistical significant correlation was found in pre-treatment mandibular plane angle (P-value =0.1), and post-treatment mandibular plane angle (P-value =0.4).

When comparing pre-treatment and post-treatment measurements, we found statistically significant differences in 2D ramus height (mean difference=3.8, SD= 0.8, P=0.001), 3D ramus height (mean difference=3.8, SD=1.1, P-value=0.002), 2D corpus length (mean difference=3.1, SD=0.6, P-value <0.01), and 3D corpus length (mean difference=4.7, SD=0.7, P-value <0.01). However, no statistical significant difference was found between pre-treatment and post-treatment 2D mandibular plane angle (mean difference=-0.5, SD=0.6, P=0.4), 3D mandibular plane angle (mean difference=-2.5, SD=1.3, P-value=0.07), 2D gonial angle (mean difference=-0.7, SD=0.6, P-value=0.2), 3D gonial angle (mean difference=-2.7, SD=5.3, P-value=0.6), and inter- ramal width (mean difference=0.3, SD=0.4, P-value=0.5).

### Descriptive statistics of the sample

VARIABLE	N	Mean	SD
Age 1	32	10.2968750 years	1.3371815
Age 2	32	15.2187500 years	0.8607714
Ramus height (pre-treatment) average in 2D	32	40.9218750 mm	4.3796991
Ramus height (pre-treatment) average in 3D	32	40.0034375 mm	4.4694611
Ramus height (post-treatment) average in 2D	32	44.6937500 mm	4.5798251
Ramus height (post-treatment) average in 3D	32	44.2817188 mm	6.2098976
Corpus length (pre-treatment) average in 2D	32	68.6718750 mm	6.3199242
Corpus length (pre-treatment) average in 3D	32	60.9667188 mm	4.6717795
Corpus length (post-treatment) average in 2D	32	71.9781250 mm	6.0227919
Corpus length (post-treatment) average in 3D	32	65.4592188 mm	4.8070412
Mandibular plane (pre-treatment) in 2D	32	21.3593750 mm	4.2946974
Mandibular plane (pre-treatment) in 3D	32	66.1087500 deg	8.7106341
Mandibular plane (post-treatment) in 2D	32	21.1921875 deg	4.4178120
Mandibular plane (post-treatment) in 3D	32	64.5159375 deg	8.4688910
Gonial angle (pre-treatment) in 2D	32	124.112500 deg	5.2350401
Gonial angle (pre-treatment) in 3D	32	113.892500 deg	8.7162925
Gonial angle (post-treatment) in 2D	32	123.599687 deg	6.0441763
Gonial angle (post-treatment) in 3D	32	109.406562 deg	27.657983
Inter ramal angle (pre-treatment) 3D	32	39.7631250 deg	3.6472512
Inter ramal angle (post-treatment) 3D	32	40.1834375 deg	3.6386807

Table 5: Study descriptive statistics.

VARIABLE	Mean in 2D	SD	Mean in 3D	SD	r: co-efficient of Pearson	P-value
Pre-treatment Ramus Height	40.92	4.37	40.00	4.46	0.4	0.01*
Post-treatment Ramus Height	44.69	4.57	44.28	6.20	0.6	<.0001*
Pre-treatment Gonial Angle	124.11	5.23	113.89	8.7	0.6	<.0001*
Post-treatment Gonial Angle	123.59	6.04	110.62	7.41	0.4	0.05*
Pre-treatment Corpus Length	72.12	4.62	60.43	5.33	0.7	0.0003*
Post-treatment Corpus Length	75.18	3.71	65.13	5.42	0.5	0.04*
Pre-treatment Mandibular Plane	21.35	4.29	66.10	8.7	-0.2	0.2
Post-treatment Mandibular Plane	21.19	4.41	64.51	8.4	-0.04	0.8

Table 6: Pearson correlation between 2D and 3D images.

\*Statistically significant value.

VARIABLE	Pre-treatment and post-treatment mean difference	SD	P-value
Ramus height in 2D	3.77	0.5	<.0001*
Ramus height in 3D	4.27	0.7	<.0001*
Corpus length in 2D	3.30	0.6	<.0001*
Corpus length in 3D	4.49	0.6	<.0001*
Mandibular plane in 2D	0.16	0.3	0.6
Mandibular plane in 3D	1.59	0.8	0.06
Gonial angle in 2D	0.51	0.4	0.2
Gonial angle in 3D	4.48	4.2	0.3
Inter ramal angle in 3D	0.42	0.4	0.3

Table 7: T-test comparing differences between pre-treatment and post-treatment measurements in 2D and 3D.

\*Statistically significant value.

As the first step in shape analysis, a Generalized Procrustes Analysis (GPA) was performed. Principal Component Analysis was completed (following the GPA), as a mathematical way to explain the excess amount of variance once size, rotation, and translation were removed from the

sample. In the first principal components of the whole sample, the variance tended to make the symphysis more narrow and vertical. The first three principal components account for seventy three percent of the variance in the sample. PC 1: 38%, PC 2: 20%, and PC 3: 15%.

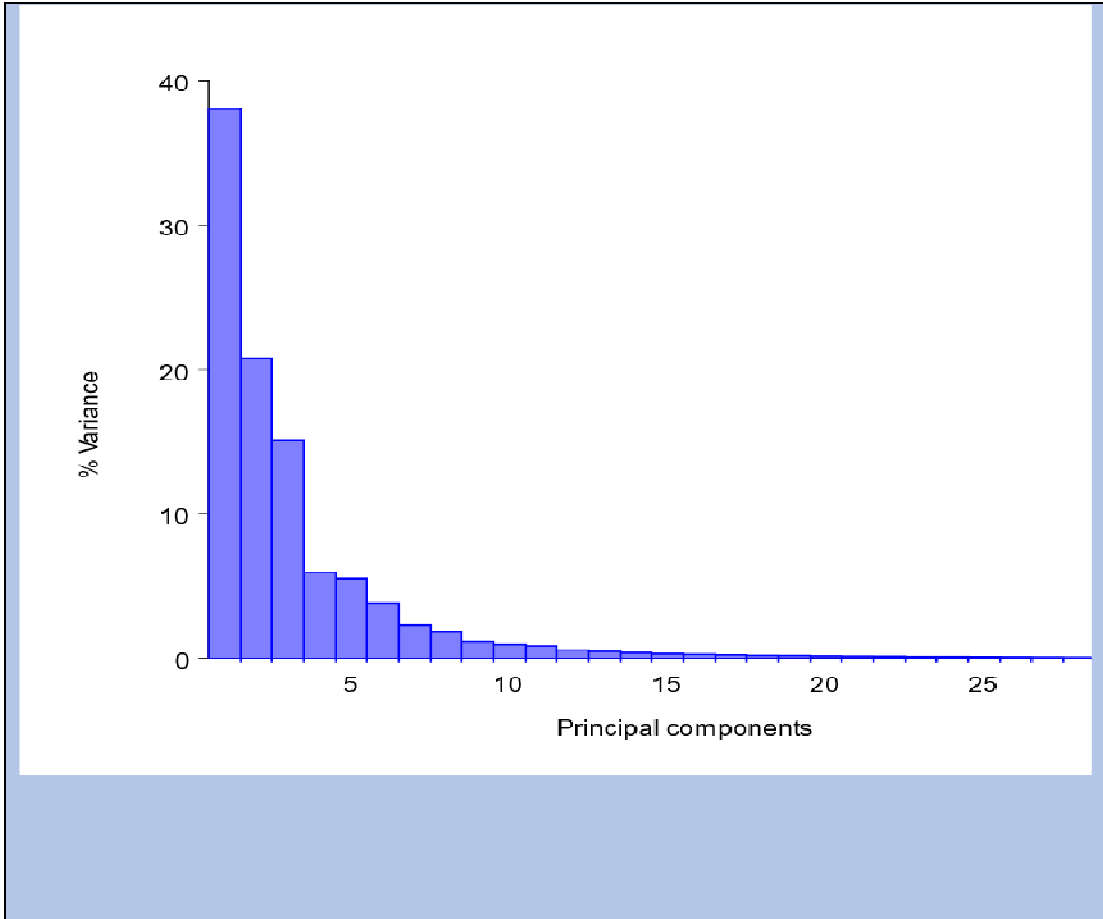


Figure 5: Principal components and percentage of variance.

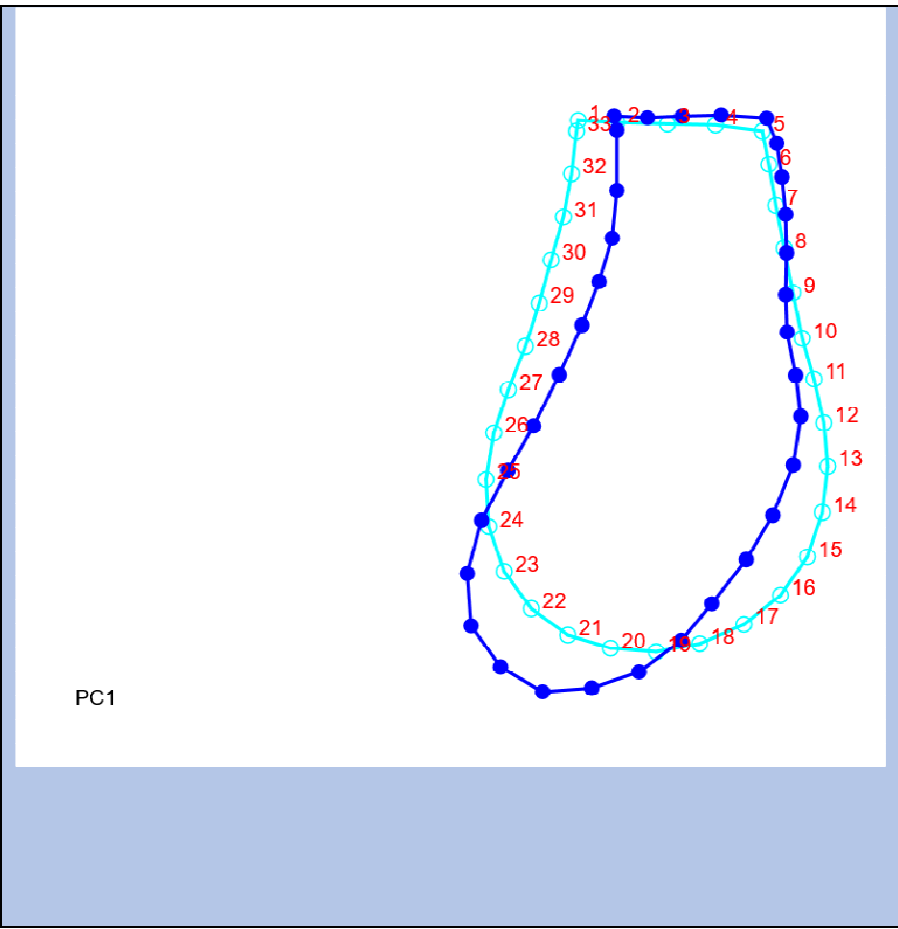


Figure 6: Principal Component 1 of the whole sample describing 38% of difference (pre-treatment light blue and post-treatment dark blue).

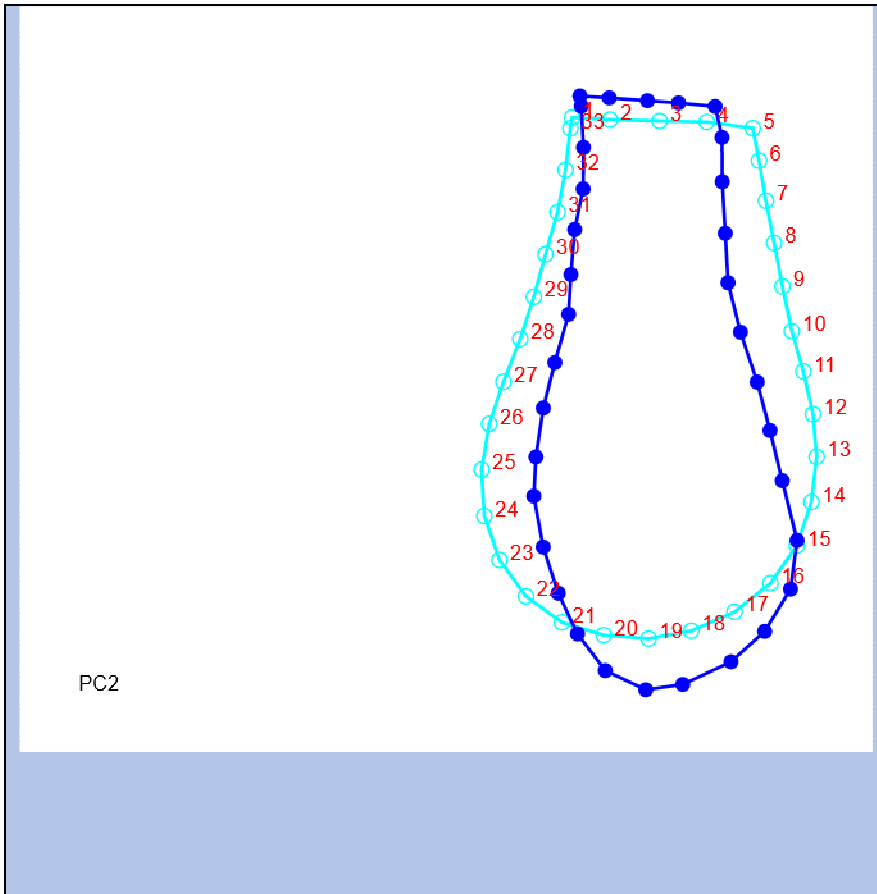


Figure 7: Principal Component 2 of the whole sample describing 20% of difference (pre-treatment light blue and post-treatment dark blue).

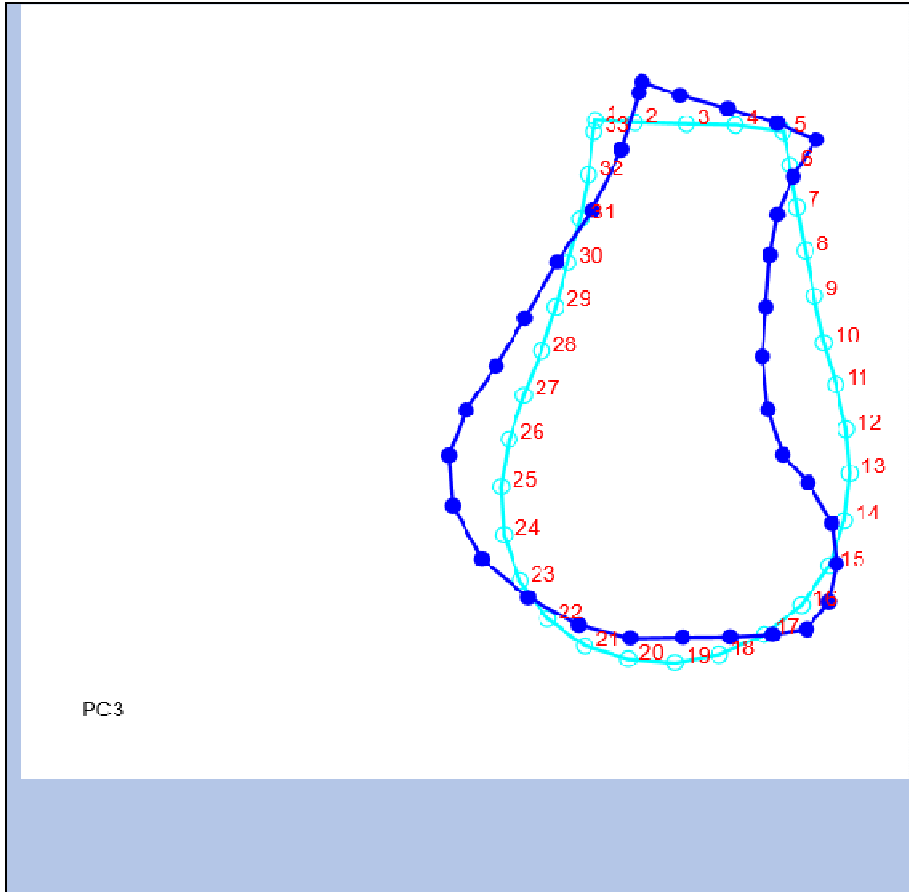


Figure 8: Principal Component 3 of the whole sample describing 15% of difference (pre-treatment light blue and post-treatment dark blue).

Discriminant Function Analysis (DFA) was used to examine the differences between pre-treatment and post-treatments sub-groups. DFA showed that there are two distinct groups separate from each other, but the cross validation shows that they are very close to the mean of the overall sample, showing that the difference between pre-treatment and post-treatment symphysis shape breaks into two distinct groups, but the difference of the DFA mean was non-statistically significant (P-value= 0.9949).

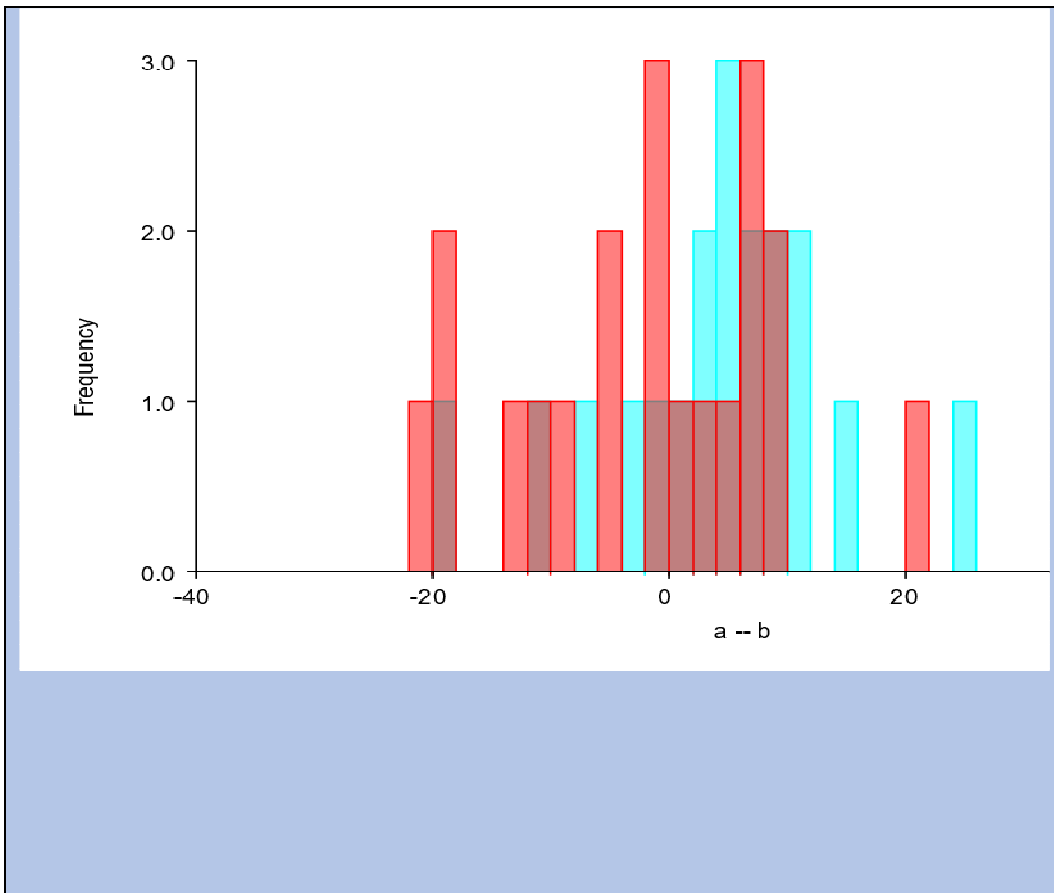


Figure 9: Discriminant Function Analysis difference between pre-treatment and post-treatment (A and B) symphysis shape.

## DISCUSSION

Over the past two decades, morphometric analysis of landmarks data has developed significantly<sup>22</sup>. CBCT has been enthusiastically embraced by dentistry, and use of CBCT has found its way into many aspects of general and specialty practices, including orthodontics<sup>23</sup>. Cone Beam Computed Tomography allows us to handle images three-dimensionally, and is now broadly used for planning and evaluating various dental treatments<sup>24,25</sup>, such as orthodontic treatment. Some procedures have been proposed for three-dimensional (3D) measurements and are also applied to cephalometric analysis, which has the potential to replace traditional two-dimensional (2D) cephalometric evaluation<sup>26</sup>. The images obtained by CBCT are now generally manipulated as volume data, and we can simultaneously observe three sectional planes—sagittal, coronal, and axial—with the use of ordinarily available 3D software. It is, however, problematic to apply the 2D definitions themselves to 3D analysis because we cannot clearly identify the landmarks on each sectional plane using a 2D definition<sup>27</sup>. Consequently, the reproducibility of landmark identification becomes poor. Although the definitions of landmarks should be modified for 3D analysis, there have been no generally accepted definitions<sup>28</sup>. This is probably attributed to a lack of well-established methods to evaluate the plotting reproducibility of landmarks. Through the evolution of CBCT, 3D scanning, and the capability of current software analysis, the ability to identify and analyze growth, diagnosis, and better predict the outcomes of treatment in the orthodontic population has been increased. Morphometric cephalometric analysis of lateral cephalograms constructed from CBCT scans can be a very useful adjunct to determine how the development of the craniofacial structures such as the mandible, and overall cranial base affect the shape and growth<sup>29</sup>.

Bruno Frazão Gribela et al.<sup>30</sup> in 2011, studied the accuracy and reliability of craniometric measurements on lateral cephalometry and 3D measurements on CBCT scans, and they found that CBCT craniometric measurements are accurate and potentially can be used as a quantitative orthodontic diagnostic tool. Two-dimensional cephalometric norms cannot be readily used for three-dimensional measurements because of differences in measurement accuracy between the two images. High accuracy and reproducibility of cephalometric measurements are particularly important because we also compared the CBCT measurements vs those made on the lateral cephalograms to assess whether 2D cephalometric norms could be used as normative values for 3D measurements. Obviously, the accuracy of the measurements is affected by the method used, and not only the quality of the images and the instruments used to accomplish those measurements.

Using anatomical landmarks (which are more accurate and reproducible) as a replacement of orthodontic landmarks, the differences in the overall shape of the mandible could be better appreciated. Several studies in the past years have looked at surface area measurements in the mandible, and they were used to explore and develop new techniques for orthodontic treatments<sup>1,2</sup>. Evaluations of the shape of the mandible around the pubertal growth spurt by using lateral cephalograms showed statistically significant growth changes, especially during the post pubertal period. Finally, investigating growth and shape of the mandible (as what was done in this study), enables clinicians not only to provide a better diagnosis and treatment plan to the orthodontic patient; but also, to more accurately predict future prognosis.

*Strength:*

The most significant difference between previous studies on mandibular landmarks and the study at hand can be noted in the decision to choose CBCT scans and anatomical landmarks instead of conventional lateral cephalograms, and the ability to recognize anatomical landmarks that are more reliable, reproducible, that are following the same pattern of the traditional cephalometric landmarks.

*Limitations:*

Because of the retrospective design of this study, direct patient evaluation for additional growth information was not possible. The selection of subjects was solely based on the availability of good CBCT scans. There were also limitations of sample size due to the samples inclusion criteria.

*Recommendations:*

The study's small sample did not allow for more stringent criteria based on ethnicity, familial influence, and other contributing growth factors. An increased sample size would allow for a smaller standard deviation and perhaps a more detailed correlation. Ethnicity in this study was not part of the inclusion criteria, but it could play a significant role. It is important to be aware of this and its ability to skew the data.

## **SUMMARY AND CONCLUSIONS**

From the results of this study, the following conclusions can be drawn: (1) These results demonstrated statistical significant positive correlation between certain 2D and 3D measurements; (2) Pre-treatment and post-treatment differences in 2D and 3D measurements

showed consistent results; (3) pre-treatment and post-treatment symphysis shape were found to break out as distinctly separate groups, but the difference between the means is small; and (4) CBCT craniometrics measurements are very accurate and can be used for craniofacial analysis.

The use of 3D measurements in the orthodontic field is very promising for growth analysis and treatment planning. The statistically significant results from this study show that the use of 3D measurements are reliable, therefore we can more accurately predetermine the outcomes of treatment in orthodontic patients.

## REFERENCES

1. Martin ES. A study of an Egyptian series of mandibles with special reference to mathematical methods of sexing. *Biometrika* 28, 149–178, 1936.
2. Morant GM, Collett M, Adyanthaya NK. A biometric study of the human mandible. *Biometrika* 28, 84–122, 1936.
3. Perin, C. P.; Suzuki, A. M. M.; Fernandez, A.; Westphalem, F. H. & Scheussel, J. L. Importancia das vaiacoes anatomicas dos canais mandibulares e sus implicacoes clinicas. *JBC: jornal brasileiro de clinica odontologica integrada*, 8(44):144-6, 2004.
4. Silva, M. H., and F. R. Fuentes. "Morfometría del proceso condilar y rama de la mandíbula en individuos adultos de la ciudad de Temuco, Chile." *International Journal of Morphology* 22.2 (2004): 169-172.
5. Demetrios J. Halazonetis, DMD, MS, Everett Shapiro, DMD, Russi K. Gheewalla, DMD, MS, R. Ernest Clark, PhD. Quantitative description of the shape of the mandible. Boston, Massachusetts, 1991.
6. Ferrario, Virgilio F., Sforza, Chiarella and De Franco, David J. *Mandibular Shape and Skeletal Divergency*, 1999.
7. Mangla, Rajat, Navjot Singh, Vinay Dua, Preajeesh Padmanabhan and Mannu Khanna. Evaluation of mandibular morphology in different facial types. *Contemporary Clinical Dentistry*. July-September 2001.
8. Hellman, Milo. Studies of the ethiology of Angle's Class II malocclusions of the teeth. *International Journal of Orthodontics*, 17: 113-155, 1931.
9. Renfroe, Earl W., Astudy of the facial patterns associated with Class I, Class II, division 1, and Class II, division 2 malocclusions. *Angle Orthodontist*, 18: 12-15, 1948.
10. Tollaro, Isabella, et al. "Class III malocclusion in the deciduous dentition: a morphological and correlation study." *The European Journal of Orthodontics* 16.5 (1994): 401-408.
11. Burdi, AR; Spyropoulos, M.N. Prenatal growth patterns of the human mandible and masseter muscle complex. *American Journal of Orthodontics*; 74: 380-387, 1978.

12. Silva, M. H., and F. R. Fuentes. "Morfometría del proceso condilar y rama de la mandíbula en individuos adultos de la ciudad de Temuco, Chile." *International Journal of Morphology* 22.2 (2004): 169-172.
13. Fuentes, Ramon, et al. "Mandibular morphometry in adults by panoramic radiographic/Morfometria mandibular en adultos a traves de una radiografia panoramica." *International Journal of Morphology* 26.2 (2008): 415-419.
14. Demetrios J. Halazonetis. Morphometric correlation between facial soft-tissue profile shape and skeletal pattern in children and adolescents. *American Journal of Orthodontics and Dentofacial Orthopedics*. Volume 132, Number 4, 2005.
15. Demetrios J. Halazonetis. Morphometric evaluation of soft-tissue profile shape. *American Journal of Orthodontics and Dentofacial Orthopedics*. April 2007.
16. Nicholson, Elizabeth and Katerina Harvati. *Quantitative Analysis of Human Mandibular Shape using Three-Dimensional Geometric Morphometrics*. Leipzig, Germany, 2005.
17. Fuyamadaa, Marico; Hiroyuki Nawab; Momoko Shibatac; Kazuhito Yoshidac; Yoshitaka Kisee; Akitoshi Katsumataf; Eiichiro Arijig; Shigemi Gotoh. Reproducibility of landmark identification in the jaw and teeth on 3-Dimensional cone-beam computed tomography images, a preliminary study of tentative methods compared to those based on cephalometric definitions. *Angle Orthodontist*, Vol 81, No 5, 2011.
18. Gkantidis, Nikolaos; Schauseil, Michael; Pazera, Pawel; Zorkun, Berna; Katsaros, Christos; Ludwing, Björn. Evaluation of 3-dimensional superimposition techniques on various skeletal structures of the head using surface models. *PloS One*. 10(2): e0118810. 2015
19. CA Lascala, J Panella, MM Marques. Analysis of the accuracy of linear measurements obtained by cone beam computed tomography (CBCT-NewTom). *Dentomaxillofacial Radiology* (2004) 33, 291–294
20. Danielle R. Periagoa; William C. Scarfeb; Mazyar Moshiric; James P. Scheetzd; Anibal M. Silveirae; Allan G. Farmanf. Linear Accuracy and Reliability of Cone Beam CT Derived 3-Dimensional Images Constructed Using an Orthodontic Volumetric Rendering Program. *The Angle Education and Research Foundation*. 2008- 0.2319/122106-52.1
21. Michael L. Hilgers,<sup>a</sup> William C. Scarfe,<sup>b</sup> James P. Scheetz,<sup>c</sup> and Allan G. Farmand. Accuracy of linear temporomandibular joint measurements with cone beam computed tomography and digital cephalometric radiography. 2005-10.1016/j.ajodo.2005.08.034

22. Matteo Saccucci, Michele D'Attilio, Daria Rodolfino, Felice Festa, Antonella Polimeni and Simona Tecco. Condylar volume and condylar area in class I, class II and class III young adult subjects. *Head and Face Medicine*; Vol. 8:34, 2012
23. J B Ludlow, Timothy, Walker, Hunter, Benavides, Samuelson and J Scheske. Effective dose of dental CBCT—a meta-analysis of published data and additional data for nine CBCT units. *Dentomaxillofacial Radiology*; Vol. 44, 20140197, 2015
24. Kawamata A, Arijji Y, Langlais RP. Three-dimensional computed tomography imaging in dentistry. *Dental Clinic of North America*. 2000; 44:395–410
25. Naitoh, Munetaka, et al. "Postoperative assessment of incisor dental implants using cone-beam computed tomography." *Journal of Oral Implantology* 36.5 (2010): 377-384.
26. Gribel BF, Gribel MN, Frazão DC, McNamara JA Jr, Manzi FR. Accuracy and reliability of craniometric measurements on lateral cephalometry and 3D measurements on CBCT scans. *Angle Orthodontist*. 2011; 81:28–37
27. Yitschaky O, Redlich M, Abed Y, Faerman M, Casap N, Hiller N. Comparison of common hard tissue cephalometric measurements between computed tomography 3D reconstruction and conventional 2D cephalometric images. *Angle Orthodontist*. 2011; 81:13–18
28. Lou, Leo, et al. "Accuracy of measurements and reliability of landmark identification with computed tomography (CT) techniques in the maxillofacial area: a systematic review." *Oral Surgery, Oral Medicine, Oral Pathology, Oral Radiology, and Endodontology* 104.3 (2007): 402-411.
29. Park, Sun-Hyung, et al. "A proposal for a new analysis of craniofacial morphology by 3-dimensional computed tomography." *American Journal of Orthodontics and Dentofacial Orthopedics* 129.5 (2006): 600-e23.
30. Bruno Frazão Gribela; Marcos Nadler Gribelb; Diogo Campos Frazãooc; James A. McNamara Jr; Flavio Ricardo Manzie. Accuracy and reliability of craniometric measurements on lateral cephalometry and 3D measurements on CBCT scans. 2011 *Angle Orthodontist*, Vol 81, No 1

