

2016

Improved detection and characterization of obscured central gland tumors of the prostate: texture analysis of non contrast and contrast enhanced MR images for differentiation of benign prostate hyperplasia (BPH) nodules and cancer

---

<https://hdl.handle.net/2144/19200>

*Downloaded from DSpace Repository, DSpace Institution's institutional repository*

BOSTON UNIVERSITY  
SCHOOL OF MEDICINE

Thesis

**IMPROVED DETECTION AND CHARACTERIZATION OF  
OBSCURED CENTRAL GLAND TUMORS OF THE PROSTATE:  
TEXTURE ANALYSIS OF NON CONTRAST AND CONTRAST ENHANCED  
MR IMAGES FOR DIFFERENTIATION OF BENIGN PROSTATE  
HYPERPLASIA (BPH) NODULES AND CANCER**

by

**DUAA MUHAMEDSALEH A. BANAJA**

B.Sc., King Abdul-Aziz University, 2010

Submitted in partial fulfillment of the  
requirements for the degree of

Master of Science

2016



Approved by

First Reader

---

Boris Nicolas Bloch, M.D.  
Associate Professor of Radiology  
Chief, MR imaging  
Medical Director, MS Bioimaging Program

Second Reader

---

Kevin Thomas, Ph.D.  
Assistant Professor of Bioimaging and Health Emergency

## **DEDICATION**

I would like to dedicate my thesis to my parent and sisters, for their endless love and great support.

A special dedication to my mother,

Thank you for your enormous love, scarifies, and continuous care.

## ACKNOWLEDGMENTS

In the name of **Allah**, the most gracious and most merciful who gave me the strength and blessing, that I can finish conducting this thesis.

My mother, **Najwa reda**, a strong and compassionate heart. I could never have done this without her faith, support, and constant encouragement. I hope this achievement will complete the dream that you had for me all those many years ago when you scarify with all what you can to give me the best education.

I spent a great deal of time finishing this thesis, but this research would not be completed without some contribution and supports from many people. First, My deepest appreciation to my advisor, Dr. **Nicolas Bloch**, who has the attitude and the substance of genius who continually and convincingly conveyed a spirit of adventure in regard research and an excitement in regard to teaching. Without his guidance and persistent help, this thesis would not have been possible. Also, I would like to thank my professor Dr. **Kevin Thomas**, who guided me from the first day I started my master degree and as an advisor throughout my thesis.

Last but not least, I owe the deepest sense of gratitude to my friend **Ziyad**, who been there every single moment, thank you for supporting me through the whole journey.

Finally, there are many people who have walked alongside me during my master study. they have supported me and guided me. I would like to thank my classmates **Craig**, **Heba**, and **kris**, and the **technologists** at the Boston Medical Center for teaching me all of the information I have gained through my journey of the master degree.

**IMPROVED DETECTION AND CHARACTERIZATION OF  
OBSCURED CENTRAL GLAND TUMORS OF THE PROSTATE:  
TEXTURE ANALYSIS OF NON CONTRAST AND CONTRAST ENHANCED  
MR IMAGES FOR DIFFERENTIATION OF BENIGN PROSTATE  
HYPERPLASIA (BPH) NODULES AND CANCER**

**DUAA MUHAMEDSALEH A. BANAJA**

ABSTRACT

**Objective:** The purpose of this study to assess the value of texture analysis (TA) for prostate cancer (PCa) detection on T2 weighted images (T2WI) and dynamic contrast-enhanced images (DCE) by differentiating between the PCa and Benign Prostate Hyperplasia (BPH).

**Materials & Methods:** This study used 10 retrospective MRI data sets that were acquired from men with confirmed PCa. The prostate region of interest (ROI) was delineated by an expert on MRI data sets using automated prostate capsule segmentation scheme. The statistical significance test was used for feature selection scheme for optimal differentiation of PCa from BPH on MR images. In pre-processing, for T2-WI, Bias correction and all images intensities are standardized to a representative template. For DCE images, Bias correction and all images are registered to time point 1 for that patient. Following pre-processing texture, features from ROI were extracted and analyzed. Texture features that were extracted are: Intensity mean and standard deviation, Sobel (Edge detection), Haralick features, and Gabor features.

**Results:** In T2-WI, statistically significant differences were observed in Haralick features. In DCE images, statistically significant differences were observed in mean intensity, Sobel, Gabor, and Haralick features.

**Conclusion:** BPH is better differentiated in DCE images compared to T2-WI. The statically significant features may be combined to build a BPH vs. cancer detection system in future.



## TABLE OF CONTENTS

TITLE.....	i
COPYRIGHT PAGE.....	ii
READER APPROVAL PAGE.....	iii
DEDICATION.....	iv
ACKNOWLEDGMENTS .....	v
ABSTRACT.....	vi
TABLE OF CONTENTS.....	viii
LIST OF FIGURES .....	x
LIST OF ABBREVIATIONS.....	xi
Chapter I: Introduction.....	1
Chapter II: Background.....	3
<b>Prostate cancer and treatment options</b> .....	3
<b>Clinical staging without imaging:</b> .....	4
<b>Imaging of prostate cancer (PCa):</b> .....	4
<b>Ultrasound Imaging (USD):</b> .....	4
<b>Computed Tomography (CT)</b> .....	5
<b>Magnetic Resonance Imaging (MRI)</b> .....	6
<b>MRI Prostate Challenges:</b> .....	11

<b>Computer-aided diagnosis (CAD) Analysis for Prostate Cancer:</b> .....	11
<b>Summary and challenges of PCa vs. BPH overlap:</b> .....	12
<b>Texture Analysis (TA):</b> .....	13
Chapter III: Methods and Materials .....	15
<b>Data</b> .....	15
<b>Pre-processing</b> .....	16
Chapter IV: Results.....	18
Chapter V: Conclusion.....	22
Chapter VI: Discussion.....	24
Bibliography .....	26
Curriculum Vitae .....	29

## LIST OF FIGURES

Figure	Title	Page
1	Ultrasound Image of Prostate	4
2	CT Image of Prostate	5
3	Prostate MR images of Patient with clinically Suspected Extra Capsular Disease	7
4	Prostate MR Images With and Without erCoil	8
5	DCE-3D MRI Prostate	9
6	MRS of Prostate	9
7	MRI of Prostate	10
8	T2WI and DCE Image Based Color Coded Image	12
9	Box-and-whisker Plots for T2W Images	18
10	Box-and-whisker Plots for DCE Images	19
11	Representative Data Set for T2W Images	20
12	Representative Data Set for DCE Images	21

## LIST OF ABBREVIATIONS

ACS	American Cancer Society
ACRIN®	American College of Radiology Imaging Network®
BIDMC	Beth Israel Deaconess Medical Center
BPH	Benign Prostatic Hyperplasia
CT	Computed Tomography
CZ	Central Zone
CG	Central Gland
DCEI	Dynamic Contrast Enhancement Image
DRE	Digital Rectal Exam
EBRT	External Beam Radiotherapy
ECE	Extracapsular Extension
erCoil	Endo-Rectal Coil
er-MRI	Endo-Rectal-MRI
FDA	Food and Drug Administration
IRB	Institutional Review Board
fMRI	Functional Magnetic Resonance Imaging
MATLAB	Matrix Laboratory
MR	Magnetic Resonance
MRI	Magnetic Resonance Imaging
MRS	Magnetic Resonance Spectroscopy
PCa	Prostate Cancer

PD .....	Power Doppler
PSA .....	Prostate Specific Antigen
PLND .....	Pelvic Lymph Node Dissection
PZ .....	Peripheral Zone
RP .....	Radical Prostatectomy
SV .....	Seminal Vesicle
TRUS .....	Trans-Rectal Ultrasound
TA .....	Texture Analysis
T1-WI.....	T1-Weighted Image
T2-WI.....	T2-Weighted Image
US .....	United States
USI .....	Ultrasound Imaging
1.5T .....	1.5 Tesla
3T .....	3 Tesla

## **Chapter I: Introduction**

In the United States, Prostate cancer (PCa) is the most common non-cutaneous malignancy after lung cancer in men with an incident rate of 126 per 100,000 people. The American Cancer Society (ACS) reported that the number of new cases of men diagnosed with PCa by 2016 will be approximately 180,890 cases. PCa is still considered as the second leading cause of cancer death in men. Also, the ACS added that the estimation of death will occur from PCa is 26,120 deaths in 2016. Today, research shows that the mortality rate is gradually decreasing compared with the past years. This is due to the development of prostate cancer screening using serum prostatic specific antigen (PSA) and digital rectal examination (DRE), in which early detection of prostate cancer and stage identification are possible. However, these traditional evaluations have limitations in that they provide inaccurate diagnoses when they are used individually in-patient for pre- and post-treatment assessments (Steuber & Huland, 2005; Sved & Gomez, 2004; Bock & Klee, 2004).

The prostate biopsies under trans-rectal ultrasound (TRUS) guidance is a following step after an abnormal PSA and DRE. Although TRUS provides histopathological examination and identify suspicion lesions, it has low sensitivity and provides limited information on the extent and the differentiation of PCa (Shijun Wang, 2014). Computed Tomography (CT) is also limited in classification of PCa and plays a key role only in staging the cancer.

As a result of these limitations, Magnetic Resonance Imaging (MRI) has emerged as a promising solution for excellent noninvasive imaging to detect, localize, and stage

the aggressiveness of PCa (Shijun Wang, 2014). However, an MRI provides a somewhat accurate prediction of the PCa that has penetrated the prostate capsule and still requires an external hardware to strengthen the utility of this imaging modality. Therefore, the application of texture analysis (TA) is a promising tool to assess PCa which has an advantage in early detection and measurement of the disease without the increase of the acquisition time. The goal of this study is to provide an effective tool to achieve an oncological control and an accurate preoperative staging of PCa to aid the physicians first for an accurate diagnose and the patients for a best treatment decision.

## **Chapter II: Background**

### **Prostate cancer and treatment options**

In 1853, John Adams, a surgeon at The London Hospital discovered the first prostatic cancer case as a rare disease in a 59-year-old male patient by histological examination (Li, et al., 2013). One hundred and fifty years later, the number of cases diagnosed with prostate cancer has increased remarkably and has become a significant health problem in the U.S. with 180,000 new cases and about 31,000 deaths occurring annually (Samuel R. Denmeade, 2002). PCa is one of these cancer types that can slowly grow, which is not threatening to a patient's life. Conversely, if the cancer metastasizes, the disease will become fatal and there is currently no cure (Bloch, Lenkinski, & Rofsky, 2008).

PCa staging relies on three factors: tumor, node, and metastasis (TNM) staging (Li, et al., 2013). The tumor cells begin within the prostate gland, and these cells have a higher probability of reaching the firm outer edge of the gland, called the capsule, and breaking through it, an event called extracapsular extension (ECE) (Feng TS, 2015). Compared with organ-confined disease, PCa with ECE is associated with decreased overall and cancer-specific survival following radical prostatectomy (Feng TS, 2015).

The current treatment options available, such as pelvic lymph node dissection (PLND), external beam radiotherapy (EBRT), and radical prostatectomy (RP) have significant side effects for patients, such as incontinence, rectal injury, and impotence (Li, et al., 2013) (Li, et al., 2013). Since patient's survival depends on the treatment selection that is based on the TNM staging and clinical symptoms, it requires an accurate



evaluation using the imaging techniques, which provide a significant contribution to the treatment regimen (Shijun Wang, 2014). MRI is one of the imaging techniques used as a determining factor because it is highly sensitive in providing pretreatment information and helping the physician in the treatment decision. Furthermore, recent advances in MRI with the computer-aided diagnosis (CAD) of the prostate are beginning to meet these challenges.

### **Clinical staging without imaging:**

Currently, elevated levels of the PSA in the blood and DRE are still used for diagnosing and staging prostatic cancer. PSA has been approved by the U.S Food and Drug Administration (FDA) in 1986 to be used as a primary biomarker to diagnose PCa (Li, et al., 2013). It has some limitation in that it is not capable of differentiating between PCa and benign prostatic hyperplasia (BPH). Thus, recent advances in medical imaging, such as MRI and other imaging modalities, contribute to the detection of PCa.

### **Imaging of prostate cancer**

#### **(PCa):**

#### *Ultrasound Imaging (USI):*

High PSA levels typically indicate a blinded sextant TRUS-guided symmetrical needle biopsy. However, TRUS biopsies have been associated with a significantly lower PCa detection accuracy due

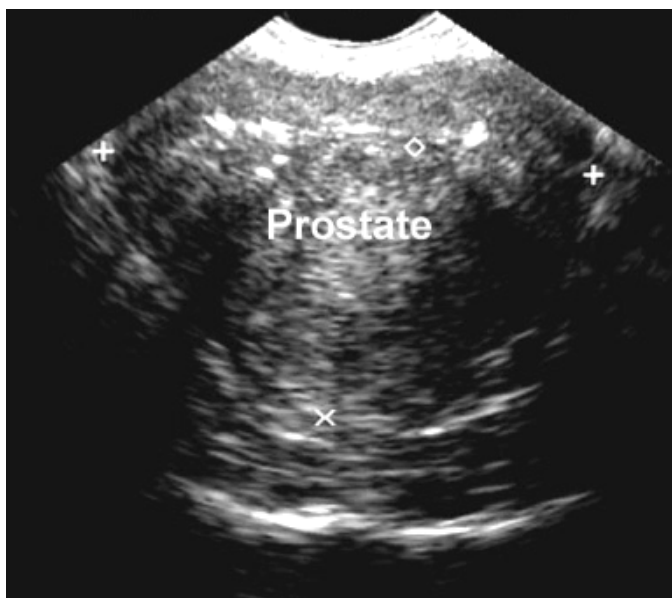

Figure (1). Ultrasound Image of the prostate indicates the poor sensitivity for PCa detection.

to the low specificity of the PSA and poor image resolution of ultrasound. In Figure (1), USI has limited spatial resolution and has not proven satisfactory for local staging of prostate cancer (American College of Radiology, 2012). Furthermore, prostate cancer appears as a hypoechoic lesion in the peripheral zone (PZ) on the transrectal probe. Many cancers can be undetected and are presumably isoechoic. In a study of 2427 men provided through the American Society, a total of 52 cancers were detected. Of these, TRUS identified 44 (85%), indicating its limited sensitivity. The addition of color and power Doppler (PD) has been reported to improve the detection of PCa by identifying increased vascularity but has not yet been shown to improve staging accuracy (American College of Radiology, 2012).

### **Computed Tomography (CT)**

CT lacks sufficient soft tissue contrast in initial staging and in assessing the local extent of prostatic carcinoma in low-to-intermediate –risk patients (Figure 2). However, it has a great value in the evaluation of distant spread of the disease and should be reserved for use in patients with higher probability of metastases (John M. Heath, 1998).

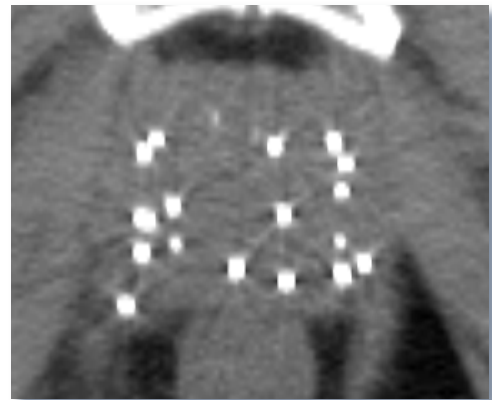


Figure (2). CT image of the prostate indicates the limitation as it shows the low soft tissue contrast in the image.

## **Magnetic Resonance Imaging (MRI)**

Magnetic Resonance Imaging has been employed in the development of the noninvasive approach to assess and detects PCa because it provides the highest spatial resolution compared with the other imaging modalities. It can be performed with or without the insertion of the endorectal coil (erCoil) (Figure 4). Although the endorectal coil insertion discomfort some patients, using it in 1.5T or higher field strength has the benefit of providing the highest spatial resolution among all the imaging modalities. Furthermore, the variation of techniques including T1-weighted image (T1-WI), T2 weighted image (T2-WI), dynamic contrast enhanced image (DCEI), Magnetic Resonance spectroscopy (MRS), diffusion weighted image (DWI), provide many chanced to diagnose the biologic processes.

### *T2 weighted image (T2-WI):*

T2-WI is the most commonly used since it has led to an excellent image with quality and resolution. This is evidenced in the image below, which it shows an improvement in the sensitivity of the MRI (Figure 3). Consequently, it is able to detect the ECE. Due to the improved sensitivity, MRI is also able to detect the invasion of the seminal vesicle (SV) (Abdellaoui, Iyengar & Freeman, 2011). This is because the specificity improves from the initial range of between 73% and 80% to a range of between 97% and 100%. Therefore, the ECE that has a distance of 0.5 millimeters is detected accurately (Abdellaoui, Iyengar & Freeman, 2011).

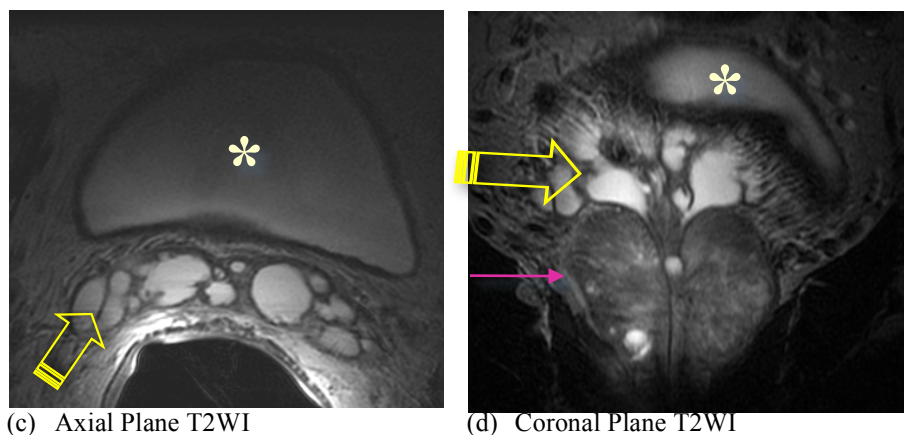
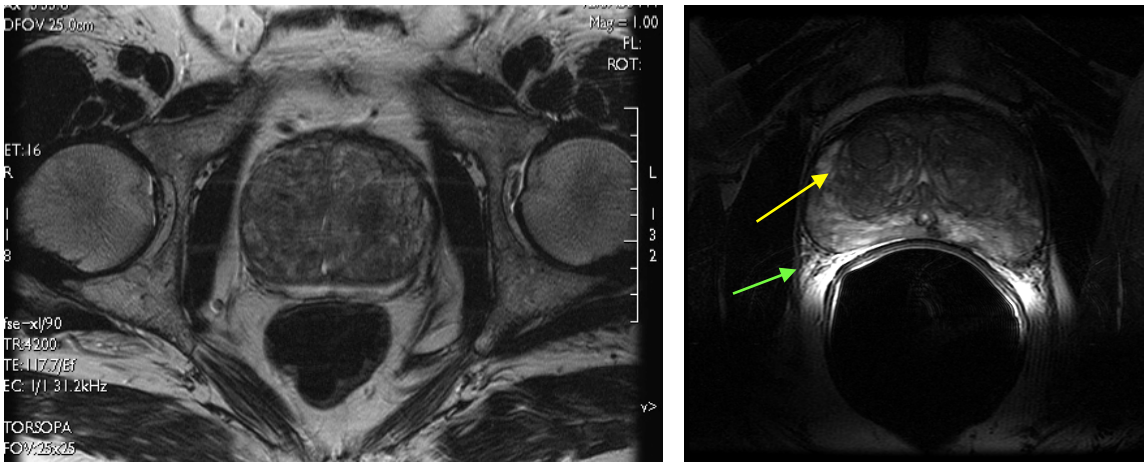


Figure (3). Prostate MR images of patient with clinically suspected extracapsular disease. In (a), the Axial T2W image of the Base of the Seminal Vesicles. Note the well-defined thin-walled Vesicles with homogeneous bright intraluminal signal (fluid). In (b), coronal T2W image of the prostate. Note the Yellow arrow is Seminal vesicles; Asterisk is the Urinary Bladder; and the Pink arrow is the prostate capsule.

There are intrinsic complexities in imaging prostate that limit staging accuracy. The good spatial resolution achieved with the erCoil in 3 Tesla (3T) MRI scan with at least halving the voxel size (voxel size  $0.35 \text{ mm}^3$  v  $0.66\text{-}1.12 \text{ mm}^3$ ), reveals pathoanatomic details on T2-WI not seen at 1.5T or 3T without erCoil, as it shown in Figure (4) (Bloch, Lenkinski, & Rofsky, 2008). In T2-WI, the interpretation of PCa can be affected by false-positive findings such as prostatitis, post-biopsy hemorrhage, and fibrosis. Thus, the addition of functional magnetic resonance imaging (fMRI) is necessary to improve the accuracy of diagnosing PCa, such as DCE-MRI, MRS, DWI (Li, et al., 2013).

#### ***Dynamic Contrast Enhanced MRI (DCE- MRI):***

DCE-MRI can diagnose earlier and more intense enhancement in sites of tumor compared with the normal PZ. PCa like any tumors has two factors microvessel density



(c) Axial Prostate MRI without erCoil

(d) Axial Prostate MRI with erCoil

Figure (4). Prostate MR images with (a) and without erCoil (b). In (a), the sequence used in this image is T2WI with erCoil Note the BPH-nodule in the right central gland (yellow arrow), and the nerves and small vessels in the neuro vascular bundle (green arrows).

(a) Sosna et al., Acad Radiol, Aug 2004

(b) Bloch et al., Acad Radiol 2004; 11:863-867

(MVD) and angiogenic that were evaluated as prognostic factors in patients with PCa. MVD has been correlated with clinical and pathological stage, metastasis, and histological grade in PCa (Bloch, Lenkinski, & Rofsky, 2008). Although there is some controversy, MVD also has been correlated with disease-specific survival and progression after treatment. Moreover, recent data suggest that DCE-MRI can provide valuable information about individual MVD in PCa. Thus, there are biological features associated with PCa that can be demonstrated with DCE-MRI for further disease characterization, as it shown in Figure (5) (Bloch, Lenkinski, & Rofsky, 2008).

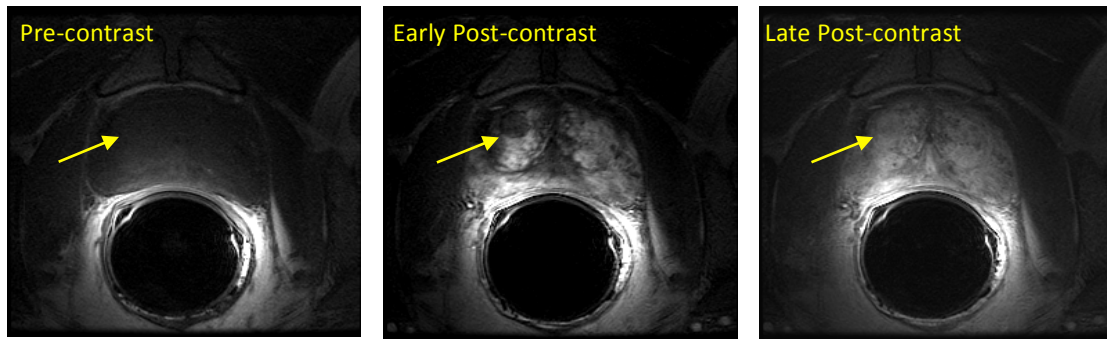


Figure (5). DCE-3D MRI of prostate. Note the features of the BPH nodule (yellow arrows), the visualization of the prostate capsule and of structures of the neurovascular bundle, as well as the superb anatomical information intraglandular. Bloch et al., Acad Radiol 2004; 11:863-867

### ***Magnetic Resonance Spectroscopic Imaging (MRSI):***

The addition of MRSI to MR imaging significantly improves characterization of PZ prostate tissue as benign or malignant. Coakley et al. demonstrated that PCa have a characteristic loss of the citrate (Cit) peak and gain in the choline/creatine (Cho/Cr) peak on MRSI. Moreover, the ratio of Cho to citrate Cit is related to the Gleason score, indicating that MRSI provides information about tumor aggressiveness (American College of Radiology, 2012). MRS facilitates the differentiation of normal and altered tissue metabolism (Figure 6). Therefore, it is different to other imaging methods that only assess abnormalities of structure or perfusion. Incremental improvement in accuracy of

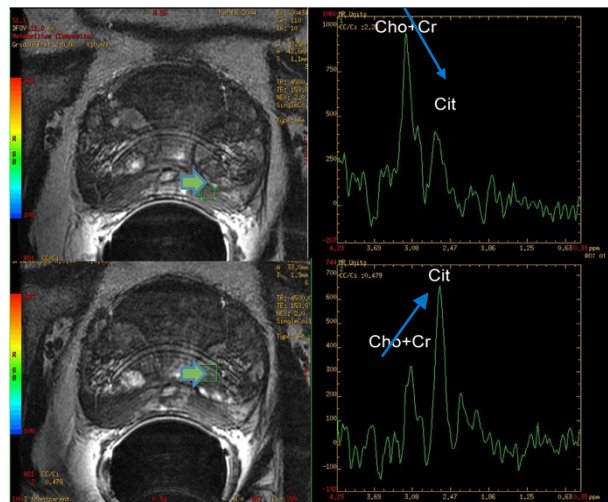


Figure (6). MRS image of the prostate indicates the assessment of metabolic information for cancer and BPH. The malignant tissue shows an elevation of Cho peak and drop of Cit peak. Whereas, the normal prostatic tissue shows the opposite elevated Cit and dropped in Cho.

cancer detection and staging has been reported when MRSI was added to endorectal-MRI (erMRI) alone (American College of Radiology, 2012). As an indicator of outcome, MRSI has been shown predictive of biochemical recurrence. However, a recent American College of Radiology Imaging Network® (ACRIN®) multicenter trial showed no incremental benefit of MRSI for localizing prostate cancer over 1.5T erMRI alone (American College of Radiology, 2012). MRSI cannot yet be considered to provide significant advantages in local staging before treatment (American College of Radiology, 2012).

#### ***Diffusion-weighted imaging (DWI):***

The inclusion of DWI technique to MR prostate imaging gives an additional method to improve prostate tumor detection and localization compared to T2-Weighted Images alone (American College of Radiology, 2012). It generates tissue contrast reflecting water molecular diffusion using apparent diffusion coefficient (ADC) mapping (figure 7). MR diffusion has been used commonly for evaluating acute stroke in the brain. Recently, it has been suggested that DWI may also play a role in the early detection of tumor response to therapy.

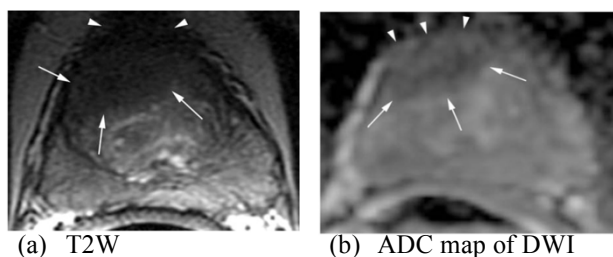


Figure (7). MRI of the prostate. (a) Axial T2-W FSE image of the mid-third of the prostate. Note the large hypointense area in the anterior portion of the gland (white arrows). (b) ADC map of DWI, Note the area with reduced ADC values suggesting tumor in the anterior gland (white arrows) with ECE (white arrow heads).

Bloch et al, Cancer Biomarkers 4 (2008) 251–262

**MRI Prostate Challenges:**

Although MRI in managing and detecting the PCa is expanding, its exact role is not yet defined. The staging of PCa is still challenging, in which there are potential indications for prostate MRI that includes surveillance in patients who are known to have low-risk PCa, for staging in patients with intermediate and high-risk cancer prior to therapy, and for detection of cancer in patients with elevated PSA but negative TRUS biopsy (Sajal S. Pokharel, 2015).

BPH is not a PCa. It is a benign enlargement of the prostate due to an abnormal growth of the noncancerous prostate cells. They differ in the way they develop. PCa commences in the outer PZ of the prostate and grown outward invading the surrounding tissues whereas in BPH the growth is inward toward the prostate's core and begins in the inner area of the prostate called the transition zone (TZ) that is a ring tissue circling and tightening the urethra. This explains why BPH produces noticeable symptoms, such as affecting the urination while the PCa is often silent disease with no obvious symptoms often for years.

**Computer-aided diagnosis (CAD) Analysis for Prostate Cancer:**

As already discussed, MRI for prostate detection and localization is widely used. However, the image interpretation is time consuming and requires high level of expertise (Shijun Wang, 2014). At least 10 parameters can be extracted from DCE-MRI scans, which make it very challenging for the radiologist to evaluate all the parameters and interpret the volume and stage of the lesion in prostate MRI (Sung, et al., 2011). CAD is a technology that is able to analyze comprehensively all the parameters of DCE-MRI



offering a more reliable in the diagnose and the detection of PCa in situations where they might be undetectable (Figure 8) (Sung, et al., 2011). CAD software imports the MR images, processes them, and generates colorized maps based on how the contrast materials flows into and out the prostate. This enhanced visualized images will help the radiologist to distinguish between PCa and benign lesions (Schruff, 2016). Using this technology will save time working on large data sets accurately and efficiently (Schruff, 2016).

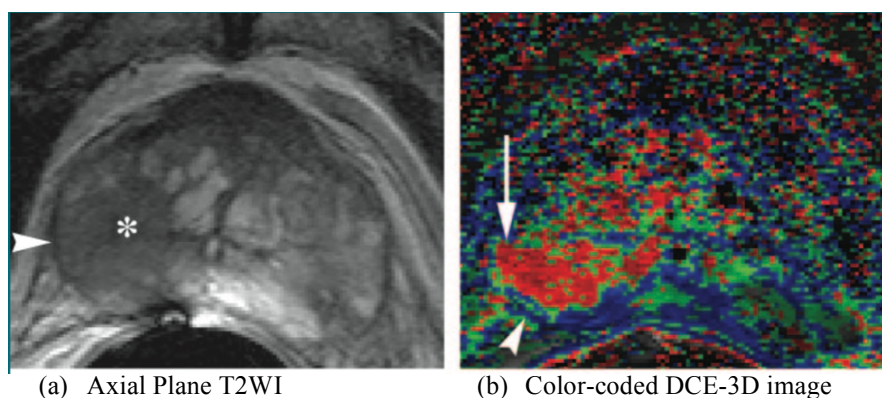


Figure (8). T2WI and DCE-3D image based color-coded image. (a) Transverse T2WI of the middle third of the prostate. Large cancer area is in the right peripheral zone and adjacent central gland (\*). Capsule (arrowhead) is clearly distinguishable and well defined. (b) color-coded DCE-3D image. Capsule (arrow) shows irregularity, in contrast to well-defined capsule (arrowhead). It was diagnosed as ECE.

Bloch, B. N. et al. Radiology 2007;245:176-185

### **Summary and challenges of PCa vs. BPH overlap:**

The prevalence of PCa necessitates a diagnostic procedure that is both sensitive and specific. There are different diagnostic procedures at the disposal of physicians. Different procedures bring with them different benefits and limitations. Many of the treatment options for PCa result in rectal injuries for the patient, incontinence, and impotence. This poses a challenge for the detection and treatment of prostate cancer. The

use of the MRI has proved valuable in the detection, localization, and the determination of the stage aggressiveness of PCa because it is more sensitive than the other procedures available. It helps address the challenges highlighted above in addition to provide better results when compared to the other approaches. However, it has a limitation in that it is less specific compared to conventional methods. Continued research and improvements have offered solutions, which show more promise in terms of the improvement of the effectiveness of the MRI in the screening, detection, and localization of PCa.

#### **Texture Analysis (TA):**

The diagnosis of PCa using the MRI is very challenging, especially during the separation of benign confounders, such as inflammation, atrophy, prostatic intra-epithelial neoplasia, BPH, and the PCa. Although there is an increased interest in the role of MRI to evaluate PCa aggressiveness, there is still the need for advanced methods of image processing and analysis as a next step to overcome current challenges. TA is a branch of image processing, which aims to reduce image information by extracting a texture description from image (Brian Barry, 2014). This extraction may allow for the mathematical and statistical analyses to detect a subtle MRI signal changes among image pixels (Brian Barry, 2014). In other words, it determines the relationship between adjacent pixels within an image that is not seen and distinguish by human eye (Wibmer A1, 2015).

It describes how often one grey tone, or pixel intensity, will appear in a specified spatial relationship to another grey tone on the image (Wibmer A1, 2015; Haralick RM, 1973). By using a series of mathematical equations, it generates a range of quantitative

parameters called “texture features” that characterize the spatial variation of grey levels throughout an image (Wibmer A1, 2015). The early changes in the image texture are of particular relevance, as relatively normal-appearing tissues with subtle microscopic disturbances due to disease, such as in the case of hepatic fibrosis, may be detected in its earlier stages (HeiShun Yu, 2015). The major advantage of this approach is the ability to detect early and quantify a chronic disease without increasing the acquisition time of the image or the dose for the patient.

TA is commonly done using the MATLAB analysis software. In the first-order grey scale analysis, individual pixels are analyzed for their values. The mean values, and the difference between the minimal and maximal pixel values is determined. In the second order grey scale analysis, the co-occurrence matrices are used to analyze the textural features. For instance, entropy matrices determine the extent of the PCa, and the distribution of its intensities. Contrast matrices are used in determining the weighted mean differences of the neighboring pixels’ intensity. The correlation is used to determine the relationship between the intensity of neighboring pixels. Using these analyses, analysts can tell benign cells from cancerous cells (Nguyen et al., 2012).

### **Chapter III: Methods and Materials**

#### **Data**

The data cohort of 10 patients in this study was collected from a previously conducted retrospective study approved by the Institutional Review Board (IRB) at The Beth Israel Deaconess Medical Center (BIDMC). All of these patients in this prospective study were confirmed to have PCa through positive core needle biopsy. Before performing the radical prostatectomy, they were scanned using 3T MRI scan with both a torso-phased array coil and an erCoil. After the surgery, it was ensured that the sectioning was done in a plane corresponding to the pre-operative MRI by sectioning and staining the excised gland with hematoxylin and eosin [H&E] (Viswanath, et al., 2012).

McNeal's recommendation is that patient study was classified into two categories; central gland (CG) and PZ PCa if more than 70% of prostate volume was found in a particular zone (JE, 1968). From the 22 MRI data sets, 16 were determined as PZ PCa (50 2D sections) and 6 were found as having PCa in the CG (30 2D sections). Only those sections were chosen to be included in the study, which showed an explicit focus of PCa in either CG or PZ to make sure that the sets of CG and PZ PCa were distinct from each other (Viswanath, et al., 2012).

The prostate region of interest (ROI) was delineated by an expert pathologist on T2-WI and DCEI using automated prostate capsule segmentation scheme. A total of 110 texture features were then extracted on a per-voxel basis from all T2-WI and DCEI data sets. Then, the statistical significance test was used for feature selection scheme is used to find an ensemble of features that will allow for optimal differentiation of PCa from BPH

on MRI.

### **Pre-processing**

The pre-processing procedures for the T2-WI involved the correction of the bias and the standardization of the image intensities to yield a representative image. For the DCE images, the pre-processing procedures involved the correction of bias, and the registration of images to the point 1 for every patient. Following pre-processing, the texture features from ROI were extracted and analyzed. Some of the texture features that were extracted included the intensity mean and standard deviation, Sobel (edge detection), Haralick features, and Gabor features.

The intensity mean and the standard deviation are important value in the analysis of digital images. This is especially the case when the TA is performed using MATLAB. The mean values for the intensity are used in the first order grey scale analysis. The standard deviation is an important part of the interpretation of the mean intensity.

The other texture feature was Sobel (edge detection). The analysis of the data required the determination of the intensity of the digital images taken using the MRI machine and the DCE-MRI. The intensity function can only be determined at discrete points. The underlying assumption in the application of the Sobel operator for edge detection is that there is a continuous intensity function. The Sobel operator serves as a differentiation operator, which is determined by the approximation of the image intensity function's gradient.

Haralick features and Gabor features were also some of the texture features. Haralick features are important in the differentiation of the homogenous low Signal

intensity (SI) regions of the PCa. The analysts use the Haralick features to differentiate them from the normal prostate, which have a hyper-intense appearance (Haralick, 1973). The Gabor feature of interest was the Gabor wavelet transform. This was acquired through the application of the Gaussian function to modulate a complex sinusoid. The purpose of this feature is to the matching of localized frequency characteristics based on their scales and orientations. This feature is important in the identification of the appearance of PCa. This is through the quantification of the visual processing features that radiologists rely upon in the examination of the appearance of the PCa.

### Chapter IV: Results

Figures 9 and 10 show box-and-whisker plots comparing the intensity difference between the two data sets; cancer (1) and BPH (2) for T2-WI and DCE images. The analysis of the images provides a statistically significant difference in the T2-WI as was observed using the Haralick features as it shown in Figure (4). While in Figure (5), it shows that there is a statistically significant difference in the DCEI that were observed in mean intensity, Sobel, Gabor, and Haralick features.

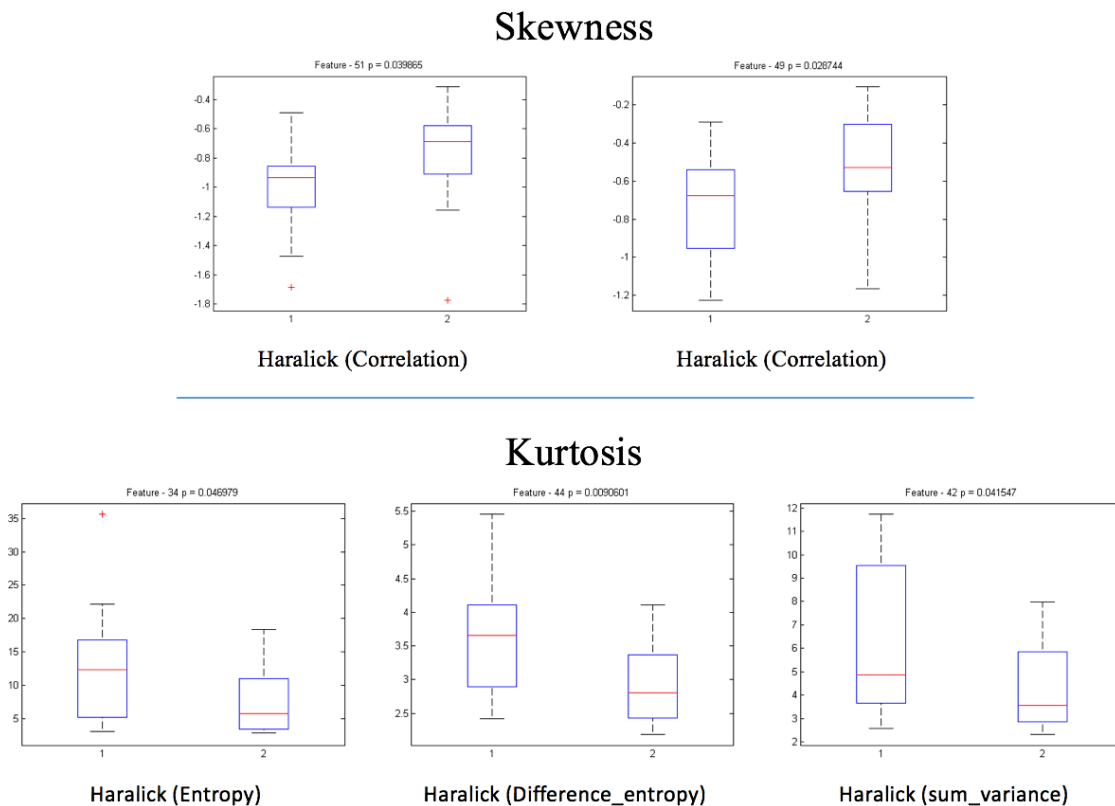


Figure (9). Box-and-whisker plots comparing the intensity difference for PCa detection in T2W images. It observes a statistically-significant difference in Haralick features.

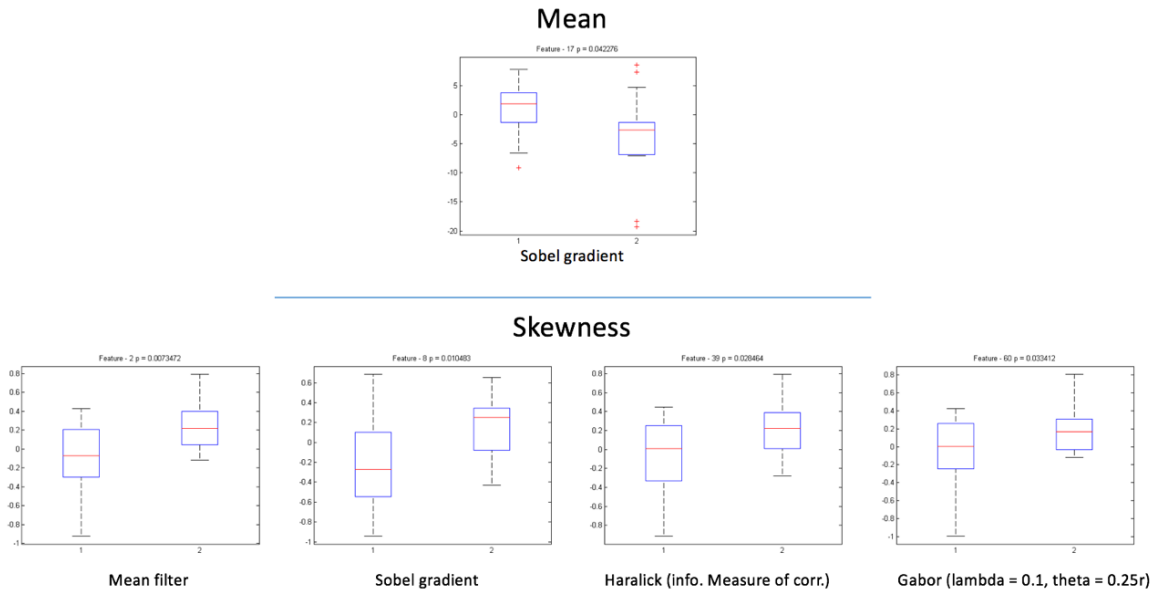
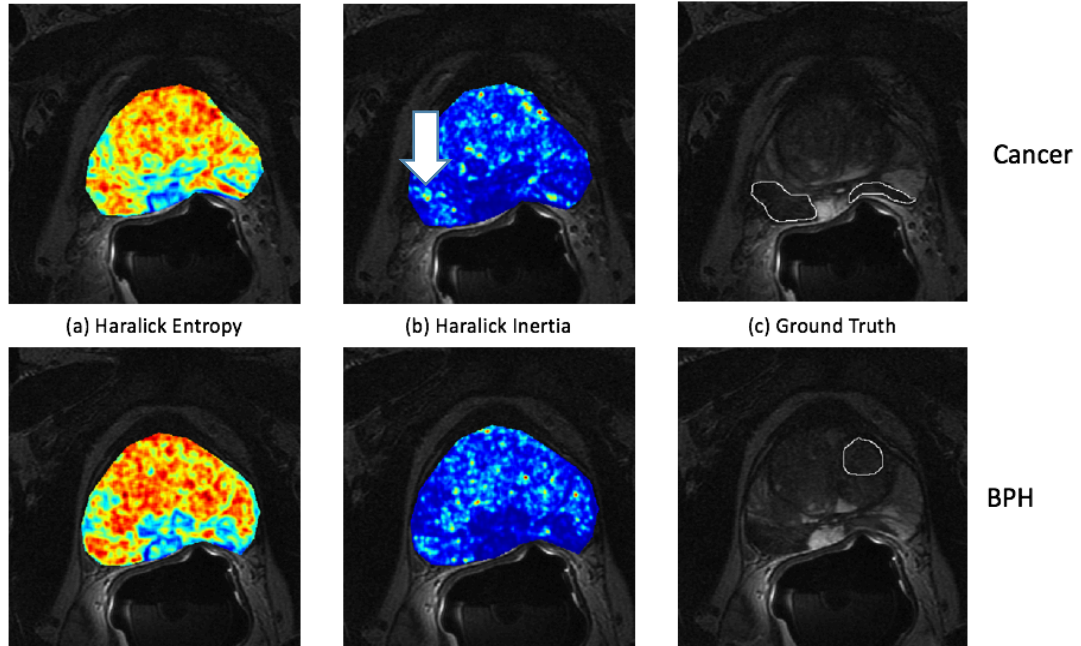


Figure (10). Box-and-whisker plots comparing the intensity difference for PCa detection in DCE images. It observes a statistical significant differences in mean intensity, Sobel, Gabor, and Haralick features

The Figures 11 and 12 show there is a visual difference in the expression of features when the cancer is compared to the BPH in T2WI and DCE images. For both patients (1 and 2), note the improved visual differentiability between cancer and BPH regions on textures features images compared with the original intensity image. Thus, we conclude that texture analysis is a promising tool to help in diagnose and differentiate between PCa and BPH.



Patient #1



Patient #2

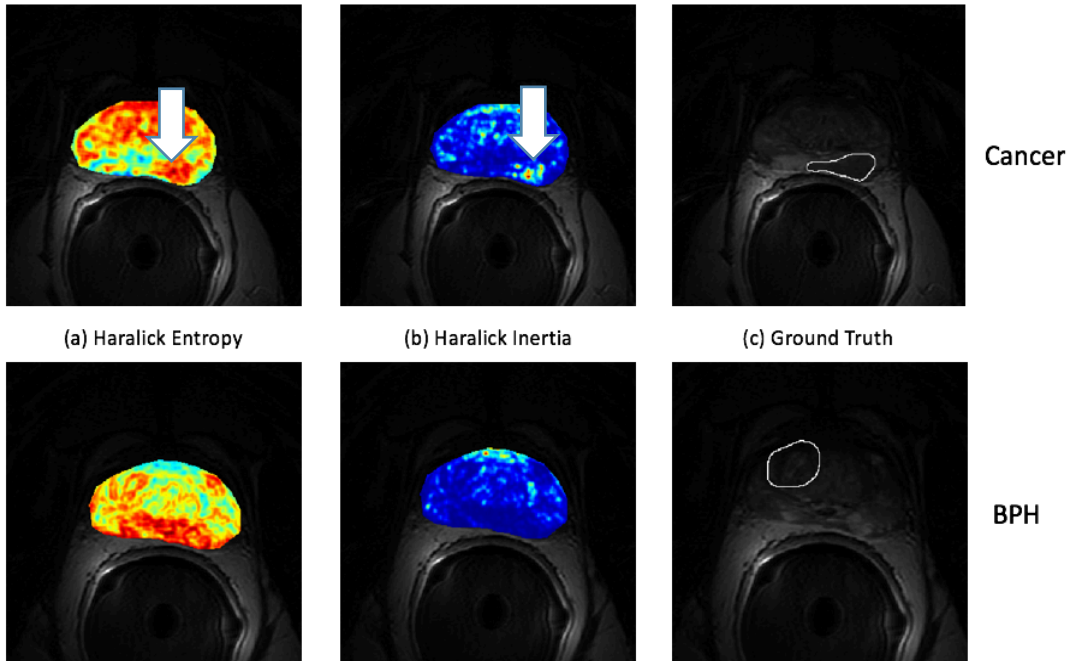
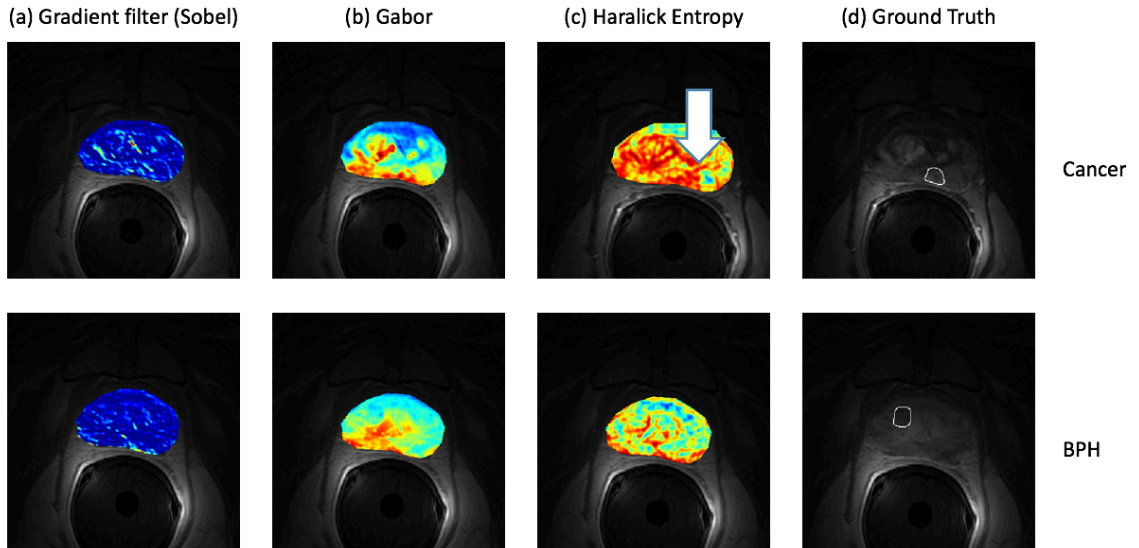


Figure (11). Representative data set and improved visual differentiability between PCa and PBH regions for patient #1 and #2: (d) mapped PCa and BPH on T2W images (outlined in white, from the outlined region). Three texture features are used (a), and (b): the probabilistic heat map of PCa presence mapped back into the images, each color map are shown confirmed statistical difference in T2W images (arrow).

## Patient #1



## Patient #2

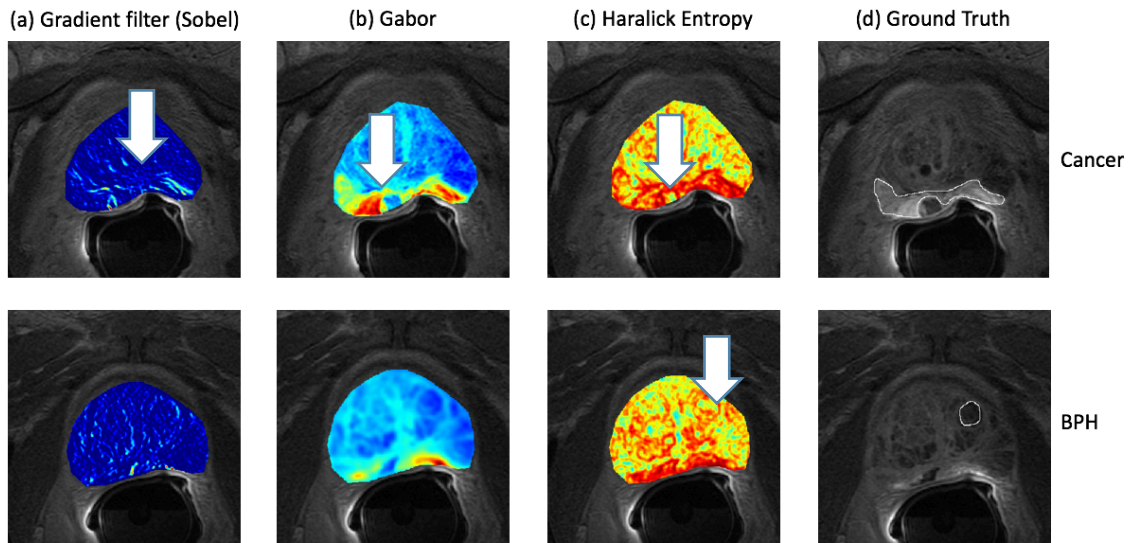


Figure (12). Representative PCa data set and improved visual differentiability between PCa and PBH regions for patient #1 and #2: **(d)** mapped PCa and BPH on DCE images (outlined in white, from the outlined region). Three texture features are used (a), (b), and (c): the probabilistic heat map of PCa presence mapped back into the images, each color map are shown confirmed statistical difference in DCE images (arrow).

## **Chapter V: Conclusion**

The proper treatment of cancer is dependent on its accurate detection, characterization of the tumor, and the differentiation of benign cells and from cancerous cells. The major finding in our study is that BPH is better differentiated in DCEI compared to T2-WI. The goal of this study is to emphasize the use of TA of non-contrast and contrast enhanced MR images to improve the detection and characterization of obscured ventral gland tumors of prostate and differentiate between BPH nodules and PCa.

TA presents a solution to mitigate some of the challenges that have been addressed in the thesis. TA shows great potential in the detection of PCa. The analysis of the intensities in the region of interest using superior software, such as MATLAB has shown a significant improvement in the detection of cancerous cells.

The accurate detection and characterization of cancer cells is important in understanding its prognosis. It also helps to improve the patient outcomes through its influence in the formulation of individualized treatments. However, the characterization of tumors has been challenged by technological challenges. TA offers a reprieve in that regard. TA offers potential for the advancement of this area of cancer research and treatment.

Finally, TA is important in the differentiation of BPH from cancerous cells. The application of texture analysis has shown that there is a statistically significant features that may be combined to build a BPH vs cancer detection system in the future. In

conclusion, this can potentially develop an important quantitative approach for characterizing PCa further in future studies.

## Chapter VI: Discussion

The initial findings of this study are very promising. The statistically significant differences between the BPH and the PCa as determined using the MRI and the DCE-MRI contributes to the body of information on the subject. It also contributes to the understanding of the modalities through which the accuracy in the detection of PCa can be improved given the limitations in the methods available.

The use of a DCE-MRI results in better differentiation of the BPH when compared to the T2-WI, which are taken using a magnetic resonance imaging machine. As discussed above, the improved differentiation when the DCE-MRI is used is because of the heightened sensitivity. The heightened differentiation of the BPH is also because of the increase resolution when the DCE-MRI is used in generating the images of the subject.

When the DCE-MRI was used, the researcher also found that there were statistically significant differences in the mean intensity, Sobel, Gabor, and Haralick features. This is very significant for future research into the detection, localization and the differentiation between the PCa and the BPH. Researchers can combine the statistically significant features in mean intensity, Sobel, Gabor, and Haralick to build a detection system that can be used not only in the detection and localization, but also in the differentiation of PCa and the BPH

This can be achieved by using the statistically significant different features as a baseline against which images can be compared. However, there is need for refinement of the image and their combination in a manner that helps achieve these objectives. Despite

the insurmountable challenges, the thesis made significant findings that not only contributed to the body of knowledge but also helped generate a potential area for future research in the detection and localization of PCa, as well as the differentiation of PCa and the BPH.

The current study was limited in the fact that the number of patients who were enrolled to participate was small. A small sample size has an effect on the validity and credibility of the results. It also affects the sampling criteria and by association, the generalizability of the results. Future studies require a detailed logistical planning to ensure that a sizable sample is acquired for any studies.

## Bibliography

- Bloch, N. B., Lenkinski, R., & Rofsky, N. (2008). The role of magnetic resonance imaging (MRI) in prostate cancer imaging and staging at 1.5 and 3 Tesla: the Beth Israel Deaconess Medical Center (BIDMC) approach. *Cancer Biomarkers*, 4(4–5), 251-262.
- Bock, J., & Klee, G. e. (2004). How Sensitive is a Prostate-Specific-Antigen Measurement? How Sensitive does it Need to Be? *Archives of Pathology & Laboratory Medicine*, 128(3), 341-343.
- Barry, B., Buch, K. et al. (2014). Quantifying Liver Fibrosis Through The Application of Texture Analysis to Diffusion Weighted Imaging. *Magnetic Resonance Imaging*, 32(1), 84-90.
- Coakley FV, Q. A. (2003). Magnetic Resonance Imaging and Spectroscopic Imaging of Prostate Cancer. *Journal of Urology*, 170(6 pt 2), S69-75.
- Conquer Cancer Foundation (n.d.). *American Society of Clinical Oncology*. Retrieved January 25, 2016, from cancer.net: <http://www.cancer.net/cancer-types/prostate-cancer/statistics>
- Cornud F, H. K. (2000). Endorectal Color Doppler Sonography and Endorectal MR Imaging Features of Nonpalpable Prostate Cancer: Correlation with Radical Prostatectomy Findings. *AJR: American Journal of Roentgenology*, 175(4), 1161-1168.
- Denmeade, S. R., & Isaacs J. T. (2002). A History of Prostate Cancer Treatment. *Nature Reviews. Cancer*, 2(5). 389–396.
- Expert Panels on Urologic Imaging and Radiation Oncology-Prostate. (2012, May 1). *ACR Appropriateness Criteria*. Retrieved June 6, 2016, from American College of Radiology: <https://acsearch.acr.org/docs/69371/Narrative>
- Feng TS, Sharif-Afshar A. et al. (2015). Multiparametric Magnetic Resonance Imaging Localizes Established Extracapsular Extension of Prostate Cancer. *Urologic Oncology*, 33(3), 109.e15–109.e22. Retrieved May 20, 2015, from Sperling Prostate Center.
- Haider MA, van der Kwast, T.H. et al. (2007). Combined T2-Weighted and Diffusion-Weighted MRI for Localization of Prostate Cancer. *AJR: American Journal of Roentgenology*, 189(2), 323-328.

- Haralick RM, S. K. (1973). Textural Features for Image Classification. *IEEE Transactions on Systems, Man and Cybernetics*, SMC-3(6), 610–621.
- Heath, J. M., & Mongia, R. (1998). Chronic Bronchitis: Primary Care Management. *American Family Physician*, 57(10), 2365-2372.
- Kwek J. W., & Thng, C. H. (2003). MR Imaging and MR Spectroscopy of Adenocarcinoma of the Prostate. *Annals of the Academy of Medicine, Singapore*, 32(4), 500-506.
- Lee, H., Xie, L., Yu, M. & Benveniste, H. (2015). The Effect of Body Posture on Brain Glymphatic Transport. *Journal of Neuroscience*, 35(31), 11034-11044.
- Li, L., Wang, L., Feng, Z., Hu, Z., Wang, G., Yuan, X., & Hu, D. (2013). Prostate Cancer Magnetic Resonance Imaging (MRI): Multidisciplinary Standpoint. *Quantitative Imaging in Medicine and Surgery*, 3(2), 100-112.
- Pokharel, S. S., Patel, N. U. et al. (2015). Multi-Parametric MRI Findings of Transitional Zone Prostate Cancers: Correlation with 3D Transperineal Mapping Biopsy. *Abdominal Imaging*, 40(1), 143–150.
- Sauvain JL, Palascak, P. et al. (2003). Value of Power Doppler and 3D Vascular Sonography as a Method for Diagnosis and Staging of Prostate Cancer. *European Urology*, 44(1), 21-30.
- Schruff, L. M. (2016, July 1). *Prostate 3T Magnetic Resonance Imaging*. Retrieved from Diagnostic Imaging Services : <https://www.disnola.com/mri/prostate-3t-magnetic-resonance-imaging/>
- Sedelaar JP, van Leenders, G. J. et al. (2002). Value of Contrast Ultrasonography in the Detection of Significant Prostate Cancer: Correlation with Radical Prostatectomy Specimens. *Prostate*, 53(3): 246-253.
- Steuber, T., Huland, H. et al. (2005). Transition Zone Cancers Undermine the Predictive Accuracy of Partin Table Stage Predictions. *Journal of Urology*, 173(3), 737-741.
- Sung, Y., Kwon, H., Park, B., Cho, G., Kim, J., Cho, K., & Lee, C. (2011). Prostate Cancer Detection on Dynamic Contrast-Enhanced MRI: Computer-Aided Diagnosis Versus Single Perfusion Parameter Maps. *AJR: American Journal of Roentgenology*, 197(5), 1122-1129.
- Sved, P., & Gomez, P. et al. (2004). Limitations of Biopsy Gleason Score Grade: Implications for Counseling Patients with Biopsy Gleason Score 6 Prostate Cancer. *Journal of Urology*, 172(1), 98-102.



- Viswanath, S., Bloch, N., Chappelow, J., Toth, R., Rofsky, N., Ganega, E., . . . Satish, E. (2012). Central Gland and Peripheral Zone Prostate Tumors Have Significantly Different Quantitative Imaging Signatures on 3 Tesla Endorectal, In Vivo T2-Weighted MR Imagery. *Journal of Magnetic Resonance Imaging*, 36(1), 213–224.
- Wang, S., Burt, K. et al. (2014). Computer Aided-Diagnosis of Prostate Cancer on Multiparametric MRI: A Technical Review of Current Research. *BioMed Research International*, 2014:789561. doi: 10.1155/2014/789561.
- Weinreb JC, et al. (2009). Prostate Cancer: Sextant Localization at MR Imaging and MR Spectroscopic Imaging Before Prostatectomy. *Radiology*, 251(1), 122-133.
- Wibmer A, et al. (2015). Haralick Texture Analysis of Prostate MRI: Utility for Differentiating Non-Cancerous Prostate from Prostate Cancer and Differentiating Prostate Cancers with Different Gleason Scores. *European Radiology*, 25(10), 2840-2850.
- Yu, H., Buch, K. et al. (2015). Utility of Texture Analysis for Quantifying Hepatic Fibrosis on Proton Density MRI. *Journal of Magnetic Resonance Imaging*, 42(5), 1259–1265.
- Zakian K. L., et al.. (2005). Correlation of Proton MR Spectroscopic Imaging with Gleason Score Based on Step-Section Pathologic Analysis After Radical Prostatectomy. *Radiology*, 234(3), 804-814.

## Curriculum Vitae

### DUAA MUHAMEDSALEH A BANAJA

7103 Avalon Drive, Randolph, MA 02368

+1(619) 319 7339 [deezee14@bu.edu](mailto:deezee14@bu.edu)

YOB: 1986

#### **EDUCATION:**

King Abdul-Aziz University	Jul 2005 – Jul 2010
Faculty of Applied Medical Sciences	
B.Sc. Diagnostic Radiology	Jeddah - Saudi Arabia

- Graduated top in my class GPA: 4.49/5.0 with second honor and obtained an assistant teacher position.
- Awarded a merit based full scholarship (based on grades and performance) to continue post-graduate studies (Master and Ph.D. degrees).
- Performed graduation research project “The Value of Magnetic Resonance Spectroscopy for Brain Lesions Imaging in KAU Hospital” supervised by one of my professors and examined by a radiologist in KAU Hospital

Boston University	Jul 2005 – Jul 2010
Division of Graduate Medical Science	
Master of Science, Bioimaging	Boston – United States

- Expected to Graduate top with current GPA: 3.84/4.0
- Took dual master programs, research and clinical path.
- Clinical internship (MRI), Jan 2016 – Aug 2016.
- Mater thesis, topic is “Improved Detection and Characterization of Obscured Central Gland Tumors of the Prostate: Texture Analysis of Non Contrast and Contrast Enhanced MR Images for Differentiation of Benign Prostate Hyperplasia (BPH) Nodules and Cancer”.

**CLINICAL EXPERIENCE:**

King Abdul Aziz University 2012 - Present  
 Diagnostic Radiology Department  
 Teacher Assistant Jeddah - Saudi Arabia

- Supervised senior students through their graduation research project.
- Lectured and established new education approach for practical subjects, which result in student's satisfaction from the course.
- Directed and led students during clinical practice in in the KAU hospital, which result in improving student's application what they learned.
- Assisted professors in teaching courses through attending weekly meeting to develop the program. 2 courses changed and developed with new education strategies.

King Khalid National Guard Hospital 07/2010 – 01/2012  
 Medical Imaging Department  
 Intern student Jeddah - Saudi Arabia

Trained and worked in the following section:

- General X-Ray includes: Fluoroscopy, Mobile and Operative X-Ray, and Mammography. Exposed to numerous imaging techniques.
- Nuclear Medicine includes: performing imaging and use of the hot lab.
- Ultrasound. Performed various type of Doppler Sonography.

King Faisal Specialist Hospital & Research Center 01/2012 – 07/2012  
 Medical Imaging Department  
 Intern student Jeddah – Saudi Arabia

Trained and worked in the following section:

- Angiography. Scrubbed and exposed to various procedures and manipulated with developed equipment.
- Computed tomography. Witnessed lung and liver biopsies procedures
- Magnetic Resonance Imaging. Practiced on open and close MRI.

9<sup>th</sup> Applied Medical Sciences Annual Meeting 19<sup>th</sup> – 20<sup>th</sup> Feb. 2013  
 Faculty of Applied Medical Sciences - KAU  
 Organizer Jeddah – Saudi Arabia

Led this conference through supervising the students, preparing topics to be discussed in the conference, and developing new ideas for the workshop day.

8<sup>th</sup> Applied Medical Sciences Annual Meeting 31<sup>st</sup> Jan – 1<sup>st</sup> Feb. 2013  
 Faculty of Applied Medical Sciences - KAU  
 Organizer Jeddah – Saudi Arabia

Designed new ideas and topics to be applied by the students and introduced in the radiology booth in the workshop, which result in success and win the competition the 1<sup>st</sup> place.

1<sup>st</sup> Saudi Biomedical Summit 3<sup>rd</sup> Jan. 2012  
 Jeddah Chamber of Commerce - KSA  
 Organizer Jeddah – Saudi Arabia

Organized the grand opening ceremony day and the registration day.

7<sup>th</sup> Applied Medical Sciences Annual Meeting 18<sup>th</sup> – 19<sup>th</sup> April 2011  
 Faculty of Applied Medical Sciences - KAU  
 Organizer Jeddah – Saudi Arabia

- Participated as member in the organizing team and presented a presentation in the conference about my graduation project “The Value of Magnetic Resonance Spectroscopy for Brain Lesions Imaging in KAU Hospital”
- Designed a poster presented in the workshop about “Interventional Radiology”, which been nominated one of the best posters and hanged in radiology department in King Faisal Specialist Hospital & Research Hospital.

6<sup>th</sup> Applied Medical Sciences Annual Meeting  
 Faculty of Applied Medical Sciences - KAU  
 Organizer

27<sup>th</sup> – 28<sup>th</sup> April 2010

Jeddah – Saudi Arabia

- Participated as an organizing member and presented a presentation about “Therapeutic Role of Intervention radiology”.

Grand Opening Conference  
 King Abdullah University of Science & Technology  
 Organizer

2009

Jeddah – Saudi Arabia

- Organized the grand opening ceremony day and registration day.
- Designed effective tour plan through the KAUST Campus for the invited international visitors.

#### **SKILLS AND QUALIFICATIONS:**

-ImageJ (Image processing software).

-Prostate MRI preparation and procedures.

#### **CONFERENCE ATTENDED & CERTIFICATIONS:**

##### **Radiology for non-Radiologist.**

King Abdul-Aziz University Hospital, Jeddah.

##### **4th Applied Medical Sciences Student Meeting.**

King Abdul-Aziz University Main Auditorium, Jeddah.

##### **Basic Life Support-provider (4CME)**

King Abdul-Aziz University Hospital, Jeddah.

##### **Introduction To Women Health.**

King Abdul-Aziz Medical City, Jeddah.

##### **The 1<sup>st</sup> Radiology Technologist Symposium.**

Riyadh International Exhibition Center, Riyadh.

##### **Basic Life Support-Provider.**

King Abdul-Aziz University Hospital, Jeddah

##### **MRI In Practice.**

abdul Latif Jameel Hospital, Jeddah

##### **The 1<sup>st</sup> International Genomic Medicine Conference.**

Center of Excellence in Genomic Medicine Research, Jeddah

- ✍ **Radiology Training Conference.**  
Intercontinental Hotel, Jeddah
- ✍ **Sterilization Machine in Hospitals.**  
King Abdul-Aziz University – King Faisal Hall, Jeddah.
- ✍ **Women’s Cancer Conference.**  
King Abdul-Aziz University Main Auditorium, Jeddah.
- ✍ **Advanced Applications in Biomedical Engineering.**  
King Abdul-Aziz University – King Faisal Hall, Jeddah.
- ✍ **Radiation Therapy (Linear Acceleration)**  
King Abdul-Aziz University – King Faisal Hall, Jeddah.
- ✍ **Breast Cancer Education Day.**  
King Abdul-Aziz University, Jeddah.
- ✍ **1<sup>st</sup> international Symposium on Osteoporosis & bone health.**  
Laylatee Gala Hall, Jeddah, Saudi Arabia.
- ✍ **Nanotechnology- based renewable energy**  
King Fahad Medical Research Center, Jeddah, Saudi Arabia.
- ✍ **Preparation For Scholarship.**  
King Abdul-Aziz University Main Auditorium, Jeddah.
- ✍ **6<sup>th</sup> Clinical Research Methodology Course for Beginners**  
Crowne Plaza Hotel – Jeddah
- ✍ **Interventional Radiology Course.**  
Laylatee Gala Hall, Jeddah, Saudi Arabia.

#### **OTHER RELEVANT TRAINING AND DEVELOPMENT:**

San Diego State University	Jan 2013 – Dec 2013
American Language Institute	
Pre-MBA / Pre-Master’s Program	San Diego, CA- USA

- Enrolled in the program to prepare me for matriculation to a Master’s program for three semesters; Spring 2013, Summer 2014, and Fall 2014.

UCLA Extension	Jan 2014 – March 2013
American Language Center	
Pre-MBA/ Pre-Master’s Program	Los Angeles, CA- USA