

**Boston University**

**OpenBU**

**<http://open.bu.edu>**

---

Boston University Theses & Dissertations

Boston University Theses & Dissertations

---

2015

# Computer assisted navigation in spine surgery

---

<https://hdl.handle.net/2144/15634>

*Downloaded from DSpace Repository, DSpace Institution's institutional repository*

BOSTON UNIVERSITY  
SCHOOL OF MEDICINE

Thesis

**COMPUTER ASSISTED NAVIGATION IN SPINE SURGERY**

by

**SHERWIN AZAD**

B.S., University of California Irvine, 2009

Submitted in partial fulfillment of the  
requirements for the degree of  
Master of Science

2015

© 2015 by  
SHERWIN AZAD  
All rights reserved

Approved by

First Reader \_\_\_\_\_

Theresa A. Davies, Ph.D.  
Director, M.S. in Oral Health Sciences Program  
Adjunct Assistant Professor of Medical Sciences & Education

Second Reader \_\_\_\_\_

Gwyneth Offner, Ph.D.  
Director, M.S. in Medical Sciences Program  
Associate Professor of Medicine

# COMPUTER ASSISTED NAVIGATION IN SPINE SURGERY

SHERWIN AZAD

## ABSTRACT

**Introduction:** Computer aided navigation is an important tool which has the capability to enhance surgical accuracy, while reducing negative outcomes. However, it is a relatively new technology and has not yet been accepted as the standard of care in all settings.

**Objectives:** The objective of the present study is to present the development and current state of technologies in computer aided navigation in Orthopedic Spine Surgery, specifically in navigated placement of pedicle screws, to examine the clinical need for navigation, its effect on surgical accuracy and clinical outcome and to determine whether the benefits justify the costs, and make recommendations for future use and enhancements.

**Conclusion:** Computer aided navigation in pedicle screw placement enhances accuracy, reduces the probability of negative outcomes, reduces the exposure of the patient and staff to radiation, reduces operative time, and provides cost-savings. Future investigations may potentially enhance this effect further with the use of innovative augmented reality type displays.

## TABLE OF CONTENTS

TITLE.....	i
COPYRIGHT PAGE.....	ii
READER APPROVAL PAGE.....	iii
ABSTRACT .....	iv
TABLE OF CONTENTS .....	v
LIST OF TABLES .....	vii
LIST OF FIGURES .....	viii
LIST OF ABBREVIATIONS .....	ix
INTRODUCTION .....	1
OBJECTIVES .....	5
HISTORY .....	6
APPLICATION.....	17
Accuracy .....	24
Radiation Exposure .....	29
COST-BENEFIT ANALYSIS.....	31
FUTURE DIRECTION .....	33

CONCLUSIONS .....	41
REFERENCES .....	43
CURRICULUM VITAE .....	49

## LIST OF TABLES

Table	Title	Page
1	Overview of Steps involved in Surgical Navigation	9



## LIST OF FIGURES

Figure	Title	Page
1	Intra-Operative Radiation Dose Comparison	4
2	Image guidance system for navigated hip surgery	10
3	Optical tracking System	12
4	Three-Dimensional Fluoroscopy	14
5	Sample view of Final navigation Display	15
6	Image Quality	16
7	Vertebral Anatomy	19
8	Pullout Strength	23
9	Accuracy Meta-Analysis I	25
10	Accuracy Meta-Analysis II	27
11	Forest Plot Depicting Neurological Complications	28
12	Ipad® Display	35
13	Augmented Reality	37
14	Components of a Google Glass®	40

## LIST OF ABBREVIATIONS

CAOS	computer assisted orthopedic surgery
CCD	charge coupled device
Cos	coordinate system
CT	computed tomography
DICOM	Digital Imaging and Communications in Medicine
GPS	global positioning system
IR	infrared
mRem	millirem, one thousandth of a Rem (Roentgen equivalent in man)
MRI	magnetic resonance imaging
OR	operative room
PACS	picture archiving and communication system
TKA	total knee arthroplasty

## INTRODUCTION

Successful incorporation of computer assistance may hold the key to improving orthopedic productivity to levels necessary to keep up with the growing demands for services being made by an increasingly aged population under increasing financial strain (Cobb and Andrews 2012). Additionally, computer assistance may result in superior accuracy and may reduce both the patient and surgeon's exposure to harmful ionizing radiation as a consequence of necessary intra-operative fluoroscopic X-ray imaging (Kraus et al. 2013, Liebergall et al. 2003). However, questions remain regarding whether the potential benefits of computer assisted orthopedic surgery (CAOS), outweighs the cost, learning curve, and risks associated with its use.

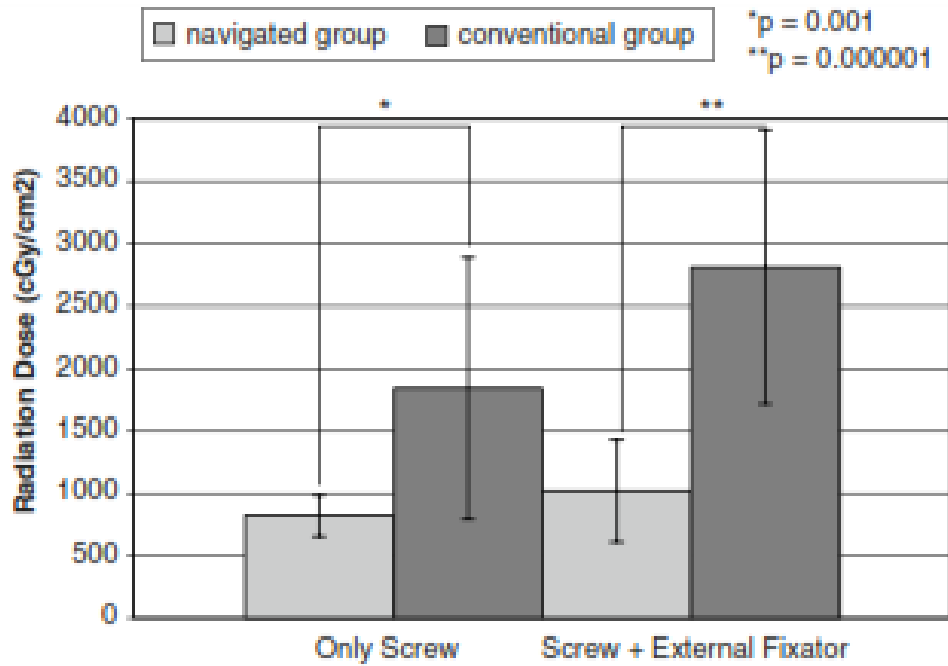
Applications of CAOS include pre-surgical planning, intra-operative navigation and alignment, and precision cutting and reaming. Much work has been done to document the benefit of CAOS versus conventional techniques. One study comparing 40 conventional surgeon guided total knee arthroplasty (TKA) procedures to 40 controlled by infrared navigation using the Orthopilot® system found optimal implant alignment in 26 cases in the computer navigated group versus 12 cases in the control group ( $p < .01$ ) citing better coronal and sagittal orientation of the components (Jenny and Boer 2001). It has been shown that ideal positioning of components enhances their lifetime and decreases complications (Berend 2004, Stiehl 2010)

In addition to increasing accuracy of component placement, computer assisted guidance systems offer the possibility to decrease ionizing radiation exposures. Percutaneous iliac screw placement to treat unstable ring fractures of the pelvis decreases the rate of wound necrosis and infection associated with open procedures, however often exposes patients and personnel to a relatively high dose of radiation (Zwingmann et al. 2009). In a comparison of 61 percutaneous iliosacral screw insertions, 35 using conventional fluoroscopic technique and 26 using an additional navigation system it was found that the radiation exposure with additional navigation was significantly less than that with fluoroscopic guidance alone (822 +/- 164 cGy/cm<sup>2</sup> vs 1843cGy/cm<sup>2</sup> for insertion of screws alone, 1021+/-408 cGy/cm<sup>2</sup> vs 2814+/- 1099 cGy/Cm<sup>2</sup> for patients that required additional external fixator, p =.0000001) (Zwingmann et al. 2009).

Another study of 54 patients with 58 lower extremity fractures which examined the placement of the distal interlocking screw under fluoroscopy alone versus fluoroscopy with electromagnetic navigation, found that the total fluoroscopy time during distal interlocking was 18.29s in the fluoroscopy alone group, and 1.62s in the fluoroscopy with electromagnetic navigation group (Uruc et al. 2013).

Although some of the previous studies (Uruc et al. 2013 , Zwingmann et al. 2009) noted that total operative time was slightly longer, the most recent data indicates that the use of navigation systems can actually save operative time overall by reducing the learning curve for procedures (Kraus 2013). Two

surgeons each placed 20 k-wires, 10 under fluoroscopic guidance alone and 10 with additional computer navigation, for a total of 40 k-wires placed in artificial proximal femora covered in foam (Kraus 2013). The results were shocking, optimal guide wire placement was achieved in the first attempt in 60% of cases in the navigated group as compared to 5% for the control group, consequently both operative time and radiation exposure were significantly reduced with radiation time reduced by over 70% (Figure 1) (Kraus 2013).



**Figure 1 Intra-Operative Radiation Dose Comparison.** Intra-operative radiation dose measured in units of cGy/cm<sup>2</sup> received in the navigated group was lower than the conventional group (Figure taken from Kraus, 2013).

## **OBJECTIVES**

The potential benefits of CAOS are seemingly vast, with increased accuracy of component placement and enhanced surgical precision, less radiation exposure for both patient and surgeon, shorter operative times and more reproducible results (Stiehl 2010, Uruc et al. 2013, Zwingmann et al. 2009, Kraus 2013, Cobb and Andrews 2012). Yet in day to day practice, CAOS has not yet been widely embraced by the orthopedic community to the level that may be necessary for the ever growing demand (Cobb and Andrews 2012). The purpose of the current study is to provide a comprehensive review of computer assistance in orthopedic surgery (CAOS) to explore the various avenues by which the adoption of CAOS can be increased.

The first specific aim of the study will be to compile all available data to determine what the current evidence states regarding the benefits of CAOS as compared to conventional techniques. Further, the study will examine the current technologies which form the basis for CAOS, and also prospective technologies which are being developed. The study will examine the cost to benefit ratio of CAOS, the effect of CAOS on operator learning curve and surgical time, and how CAOS can be successfully incorporated into the orthopedic work flow. Finally, the study will utilize all of the collected data to propose questions that may remain regarding CAOS which require further study, and to make recommendations for future applications of CAOS.

## HISTORY

Surgery itself has a history that stretches back thousands of years. However the story of using tools to more precisely locate an anatomical target within the body, known as surgical navigation began much more recently with the advent of stereotactic neurosurgical techniques which were pioneered in the first stereotactic surgery on a human patient in 1947 by Drs. Edward A. Spiegel and Henry T. Wycis (Coffey 2009, Spiegel et al 1952). Over the next 5 years they operated on over 100 patients and continued to perfect their technique to calculate an exact position of the electrode based on two principles: (1) determination of a reference point by means of a radiograph taken under definite standard conditions, and (2) an exact knowledge of the position of the area to be destroyed in relation to the reference point (Spiegel et al 1952). They performed studies on cadavers with brains fixed *in situ* as quickly as possible after death, where they would attach a stereotactic frame to the skull and pass a series of metal rods directly through the skull and brain itself at known distances and positions from each other, so that correction could be made for shrinkage as a result of fixation and/or freezing of the specimens. They would then section the brains and assign coordinates to structures of interest within the brain in order to create an atlas. However, they quickly realized the limitations inherent in defining a system of coordinates relative to only one point; for example their initial reference, the readily identifiable calcification at the center of the pineal gland,



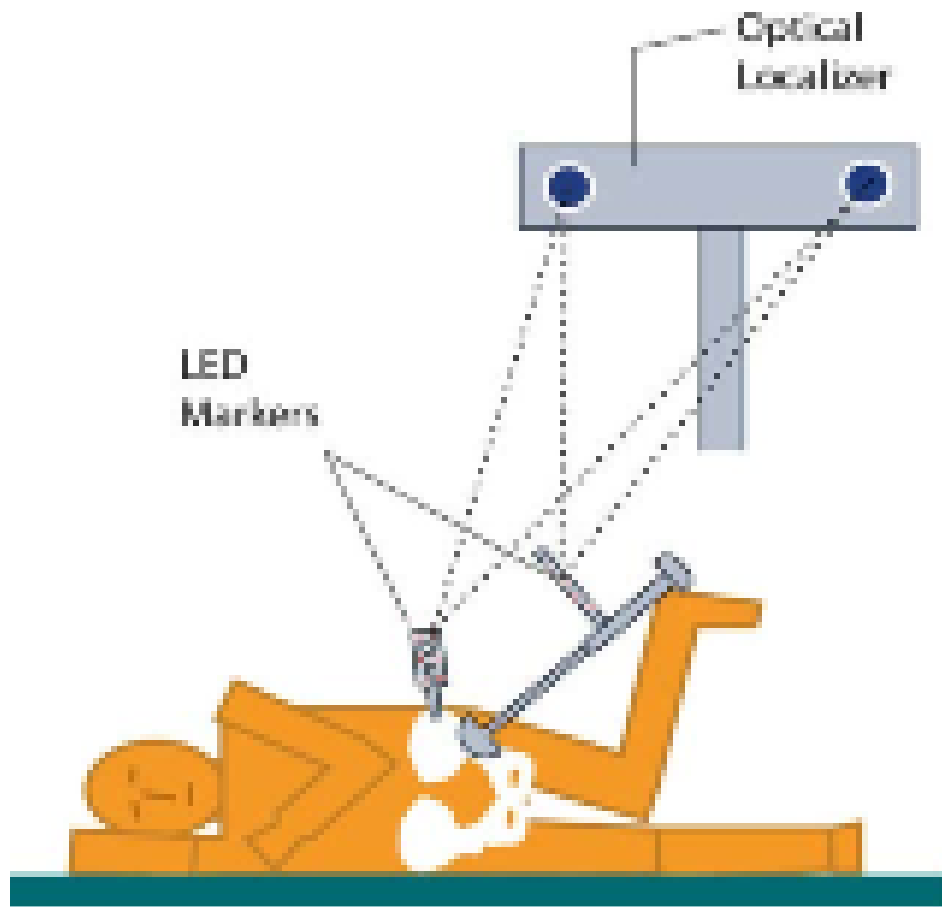
could vary by as much as 16mm in the mediolateral plane and 12mm or more in the anterolateral point (Coffey 2009). They began a systematic search for reference points which were easily identifiable and reliably positioned within the human brain relative to important anatomical targets. Their work was pioneering in the field of surgical navigation because it established the not only the principles of stereotactic surgery, but also the use of cadaveric and post-mortem variability studies to determine the accuracy of their system. Future investigators would expand on these initial investigations to produce more precise atlases based on more advanced planes of reference.

As technology has progressed we now have the capability to produce high quality three dimensional images through the use of magnetic resonance imaging (MRI)'s and computed tomography (CT) scanners, and we also have the ability to process the data produced by these medical imaging techniques to locate anatomical targets during surgery more precisely than ever before. The process begins by obtaining a pre-operative image which is stored within a computer as a data set which, for a 3-dimensional model for example a CT of the spine, would have a numeric value representing the brightness at each point within a typical x,y,z coordinate system . By establishing a separate reference coordinate system which is representative of the physical reality of the patient in the operating room, and then imposing the data from the pre-operative image onto that coordinate system, we can come up with a useful navigation image. This process is known as registration and it is an important component of any navigation system reliant

on preoperative imaging (Table 1) (Tjardes et al. 2010)). In order to understand this concept, a useful analogy can be found in modern day GPS (global positioning system) navigation systems. Here, the coordinate system which represents the physical reality would be the area map, and the data set representing the patient's anatomy would be the route which we are plotting on that map. The surgeon's instruments are marked with optical trackers which allow their position relative to the patient's anatomy to be displayed, similar to how the GPS navigation system displays the position of a vehicle (Figure 2).

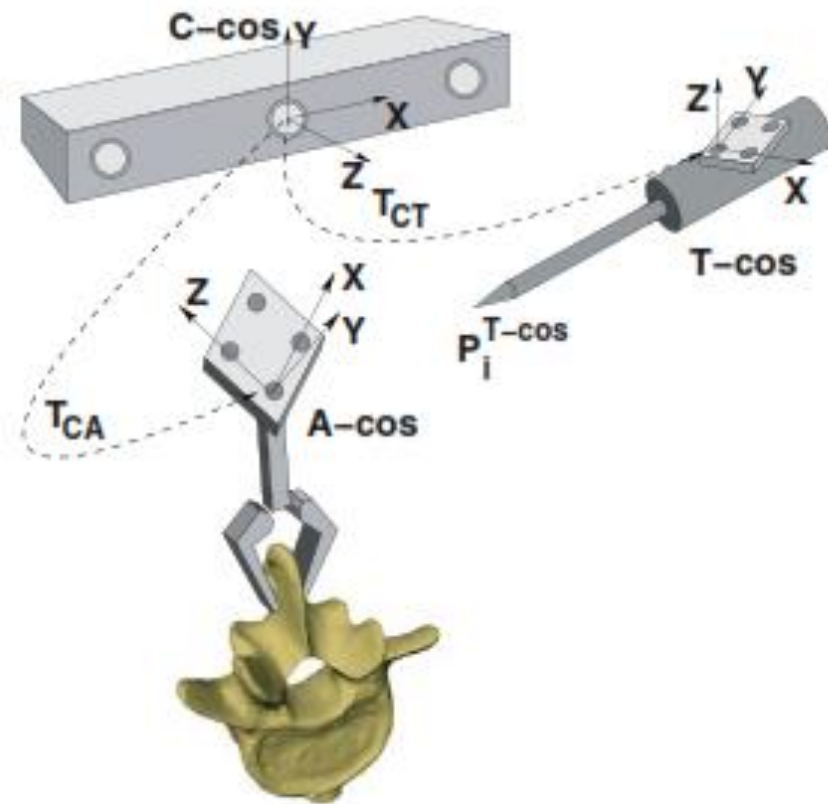
**Table 1: Overview of Steps involved in Surgical Navigation.** (Adapted from Hebecker 2004)

	3-D Navigation based on pre-operative imaging (CT)	Navigation based on intra-operative imaging
Step 1	Image Transfer	Tracking
Step 2	Tracking	Referencing
Step 3	Referencing	Image Acquisition and transfer
Step 4	Registration	Navigation
Step 5	Navigation	



**Figure 2 Image guidance system for navigated hip surgery.** There is a reference body composed of LED markers rigidly attached to the patient's body, and another set of markers attached to the surgeons tool (Figure taken from Jaramaz 2004).

Once the pre-operative image is transferred to the system, the next step in the process is the tracking of the surgical instruments, and the reference array. In order to track the position of the surgical instruments optical tracking systems are commonly used. An optical localizer, consisting of two or three CCD (charged coupled device) cameras is used to track the position of infrared markers rigidly attached to the instrument (Nolte and Langlotz 2004, Tjardes et al. 2010). The markers are composed of 3 or more elements which reflect, in a passive system, or emit, in an active system, infrared light back towards the CCD detectors (Nolte and Langlotz 2004). By determining the position of three or more non-collinear points we can establish a coordinate system for that marker, as well as precisely determine its position in the coordinate system of the detector. Once this has been determined, it is trivial to transform the coordinate data from any of the points which are defined in the coordinate system of the tool, for example the position of the tip, into position data in the coordinate system of the detector. A reference body rigidly attached to the anatomical target, usually to the spinous process of the vertebra in question as seen in Figure 3, allows for the position of the anatomical target to be established in the same manner. These are the tracking and referencing steps (Nolte and Langlotz 2004).

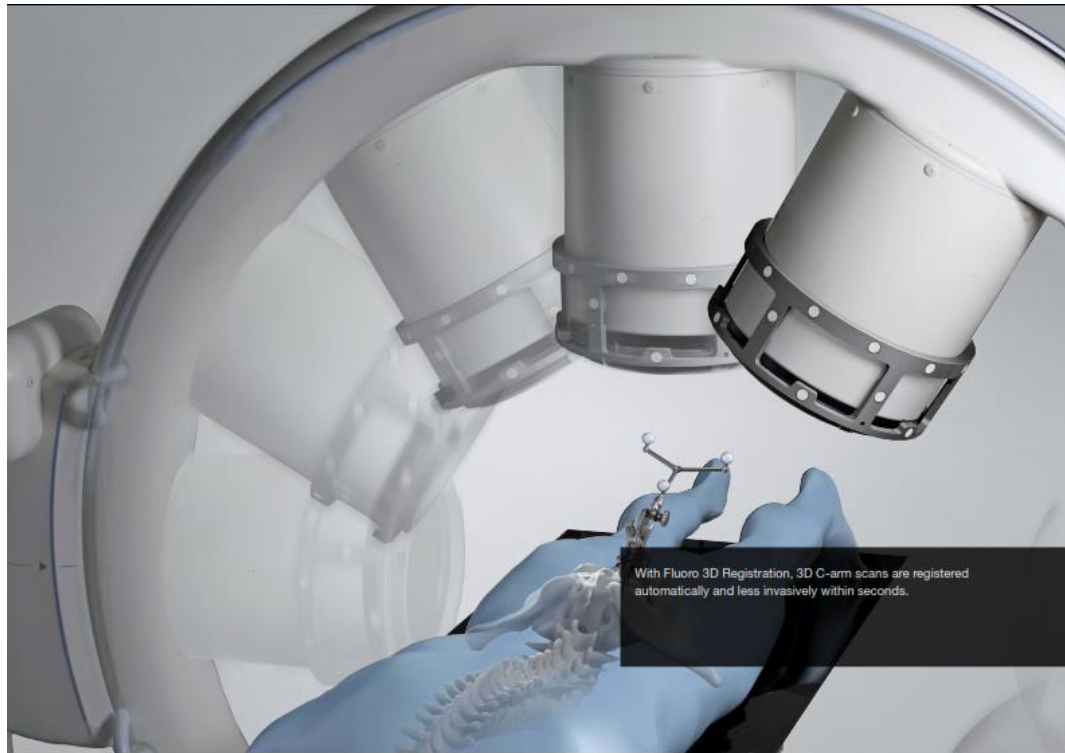

**Figure 3: Optical Tracking System.** An optical localizer consisting of several CCD (charged couple device) cameras is used to detect the position of IR(infrared) markers rigidly attached to a surgical tool and a vertebra. This allows for coordinate data from the local tool coordinate system, T-cos, and the anatomical coordinate system, A-cos, to be transformed into position data in the cameras coordinate system, C-cos (Figure taken from Nolte and Langlotz 2004)

Once this is complete registration can occur via several mechanisms. One of these would be pair-point registration, in which three points not on a straight line are identified in the preoperative data set and in situ during surgery, allowing the data set to be imposed onto the “real” coordinate system. Another mechanism of registration would be surface registration, which matches no single points but portions of the bony surface to surfaces in the preoperative (Tjardes et al 2010)

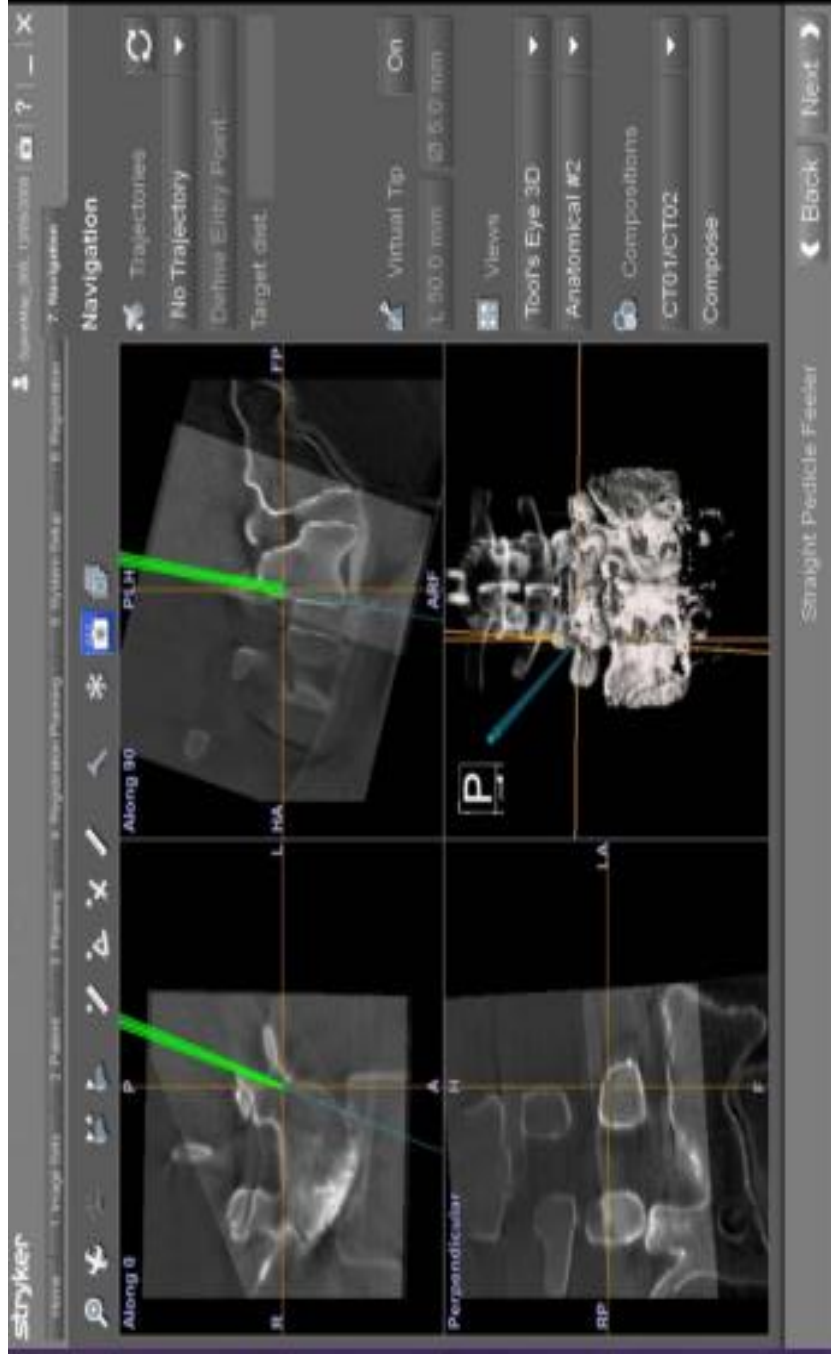
A third mechanism of registration, seen in Figure 4, is automated registration through the use of an intraoperative fluoroscopic image or series of images in conjunction with the placement of a single reference point on the spinous process of the vertebra in question (Grzeszczuk et al 2000, Tjardes et al. 2010) .

Any of these registration processes requires some element of interaction, whether it is manual feature extraction of anatomical features from the data set using a computer mouse or intraoperative identification of features using a tracked instrument or fluoroscopic imaging. Thus, in order to minimize errors in registration which would negatively impact the accuracy of the navigation, it is necessary to perform this step carefully, and to validate the result , and then useful navigation images seen in Figures 5 and 6 can be obtained (Nolte and Langlotz 2004).

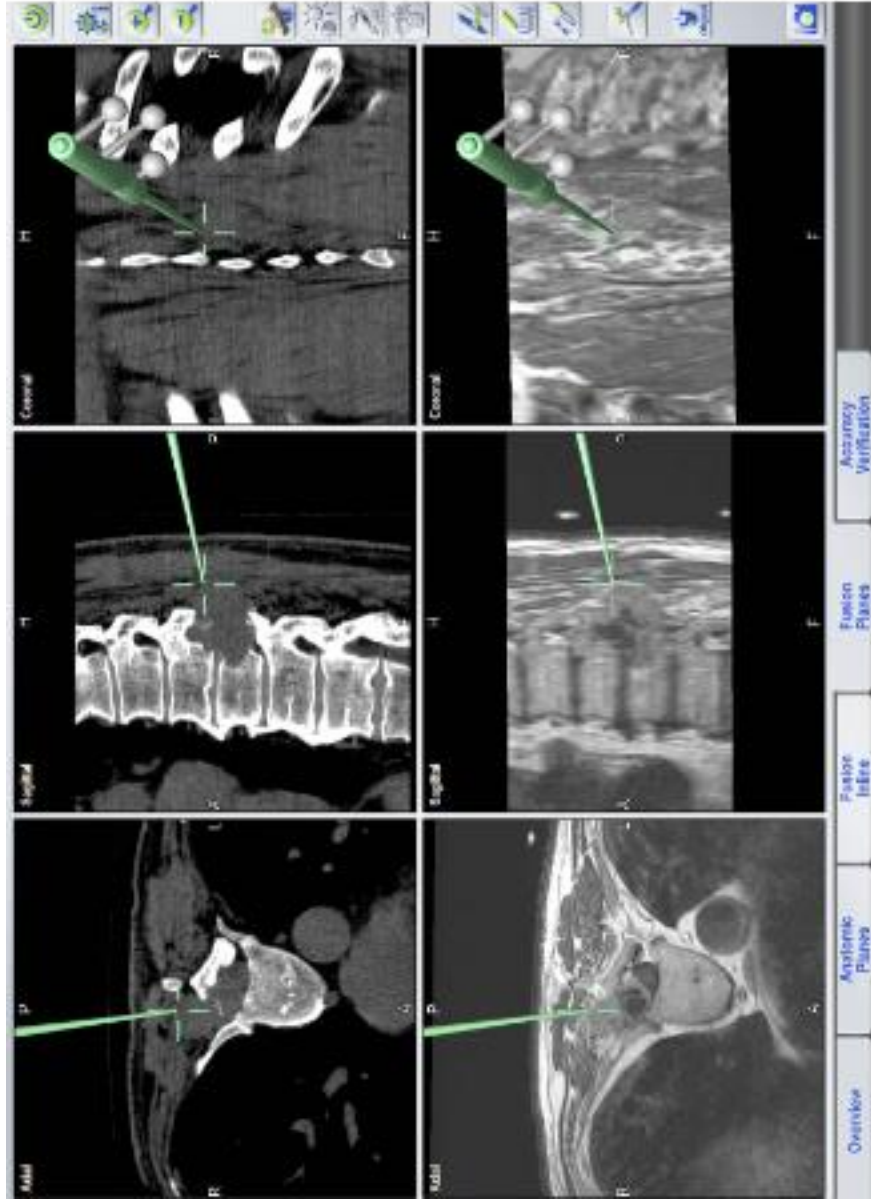


**Figure 4 Three-Dimensional Fluoroscopy.** Three-dimensional fluoroscopy allows for taking numerous intra-operative images in quick succession from different angles. These images can then be merged with pre-operative data from a CT or MRI to greatly enhance image quality (Figure taken from Brainlab Spine Navigation 2013)





**Figure 5 Sample view of final navigation display.** Here we see a tracked instrument, in this case a straight pedicle feeler, represented by the green indicator in axial, lateral, and oblique views of the spine, and in the bottom corner is a 3-d representation of the patient's anatomy with the pedicle feeler indicated in blue. (Figure taken from Stryker. )Spinemap Quick Reference Guide 2010)



**Figure 6 Image Quality.** Image quality can be drastically enhanced by merging pre-operative CT (top) or MRI (bottom) data with intra-operatively acquired three-dimensional fluoroscopy. This is an example of automatic registration (Figure taken from Brainlab Spine Navigation 2013)

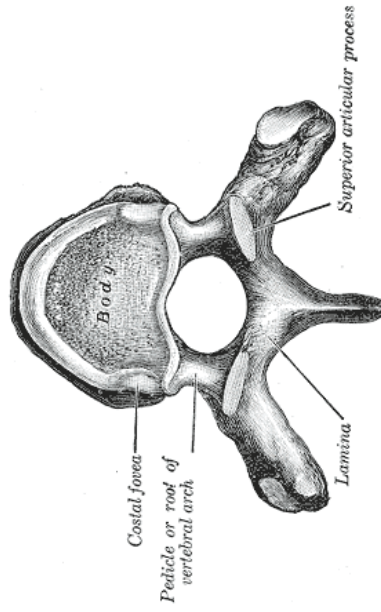
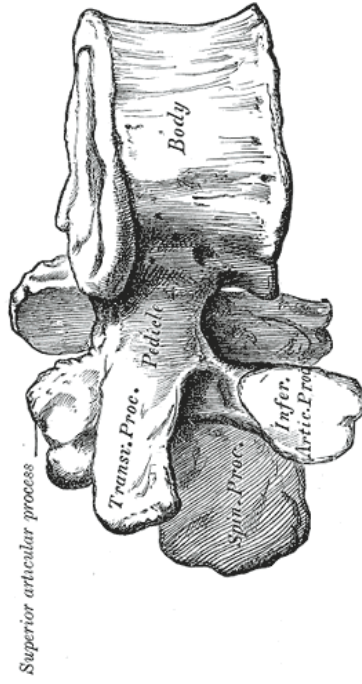
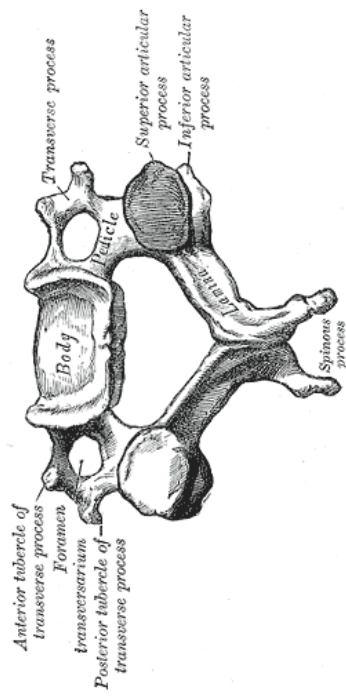
## APPLICATION

Computer assisted orthopedic surgery may offer several important benefits included increased precision of implant placement, decreased operative time and blood loss, as well as decreased radiation exposure for both the patient but also for the surgeon and operating room staff. However these benefits must be weighed against the acquisition and maintenance costs of such systems, as well as other issues surrounding their implementation, to provide a rational basis for their use.

By examining a specific application of computer aided surgical navigation, for the placement of pedicle screws in instrumented spinal fusion surgery, it is possible to gain a better understanding of the specific need for this technology, and how it might be improved upon in the future. Spinal navigation has come to be widely adopted; in a survey of 128 German neurosurgical departments in 2007, 64% of respondents had access to spinal navigation equipment (Schroder and Wassman 2014). Yet at the same time, there has been a lack of consensus regarding whether or not it should be considered a standard of care; with 98% of respondents in that same survey rejecting the notion that insertion of pedicle screws without navigation would constitute medical malpractice (Schroder and Wassman 2014).

Spinal fusion is a common procedure in spinal surgery that is used for the treatment of many spinal conditions including trauma, tumors, a wide range of

deformities including kyphotic and scoliotic disorders, as well as degenerative diseases of the spine (Mobbs et al 2011). Metal screws, usually made of titanium, are drilled into the pedicles of adjacent thoracic or lumbar vertebra, and are then connected with rods to provide stability and support during the fusion process. Pedicles, which can be seen in Figure 7, are the strongest part of the vertebra and pedicle screw fixation affords multidimensional control which results in an improved fusion rate and affords the greatest degree of deformity correction (Rajasekaran et al. 2007, Hicks et al 2010). After fixation, bone tissue and synthetic material are grafted into the region to allow for bony ingrowth to “fuse” the two adjacent vertebral segments into one solid construct.



**Figure 7 Vertebral Anatomy.** Lateral (right) and axial (left) views of vertebrae. Placing a screw within the pedicle of a vertebra can be made especially challenging by variations in anatomy at different levels, for example cervical (top left), and thoracic (bottom left) (Figure taken from Gray 1918)

Proper placement of a pedicle screw can be technically challenging. The goal is to place the pedicle screw perfectly within the cortical borders of the pedicle and the vertebral body (Stauff 2013). This is complicated enough when considering placement of a screw at one vertebral level, however it becomes even more difficult when placing screws at multiple levels due to the variations in anatomy that occur at different regions of the spine. The lumbar spine presents the least challenge due to the large size of the vertebra and historically has been the most common target for surgery. In the thoracic and cervical regions there is a decrease in size of the pedicle and vertebral body, and a corresponding decrease in cord to canal ratio as a result, which makes placement of a screw at this levels more difficult and therefore less frequently performed, especially in the cervical region (Rajasekeran et al 2007). In one study of 2,905 pedicle measurements, the size of the pedicles in the L5 segment were measured to be 18mm on average in transverse diameter as compared with 4.5mm on average the T5 vertebrae (Zindrick et al 1987).

Additionally, the increased risk of an undesirable outcome presented by the decrease in pedicle size has hampered the implementation of pedicle screw fixation in adolescent and pediatric populations. Another common target for pedicle screw fixation is the first sacral segment (Mirkovic et al 1991). Here the large interpedicular distance and desire to place the tip of the screw into the

dense bone at the promontory of the segment means that the ideal screw placement should have a very medial trajectory. In those patients with large iliac crests, commonly men, the ideal path for the screw may be blocked (Kim et al 2013).

Errors in pedicle screw placement occur when a portion of the screw breaches the cortex of the pedicle which can result in dyesthesias, neural injury, vascular injury, or early implant failure (Manbachi et al 2014) . The extent of the breach is usually graded according to the classification by Laine et al, (2000) which proposes 4 categories according to the length of threading exposed: grade 1 is 0-2mm, grade 2 2-4mm, grade 3 4-6mm, and grade 4 is more than 6mm of exposed screw (Laine et al 2000, Hicks et al 2010). Additionally it is necessary to classify breaches as having occurred in directions medial, lateral, superior, or inferior to the pedicle, as well as anterior breach of the tip of the screw to the pedicle or vertebral body (Laine et al 2000) .

The potential ramifications of a cortical breach vary depending on the pathology being addressed, the regional anatomical considerations, and the grade and direction of the breach. Medial breaches are considered to be the most clinically significant, because the pedicles form the lateral border of the vertebral canals thus pedicles breaches in this direction violate the canal space.

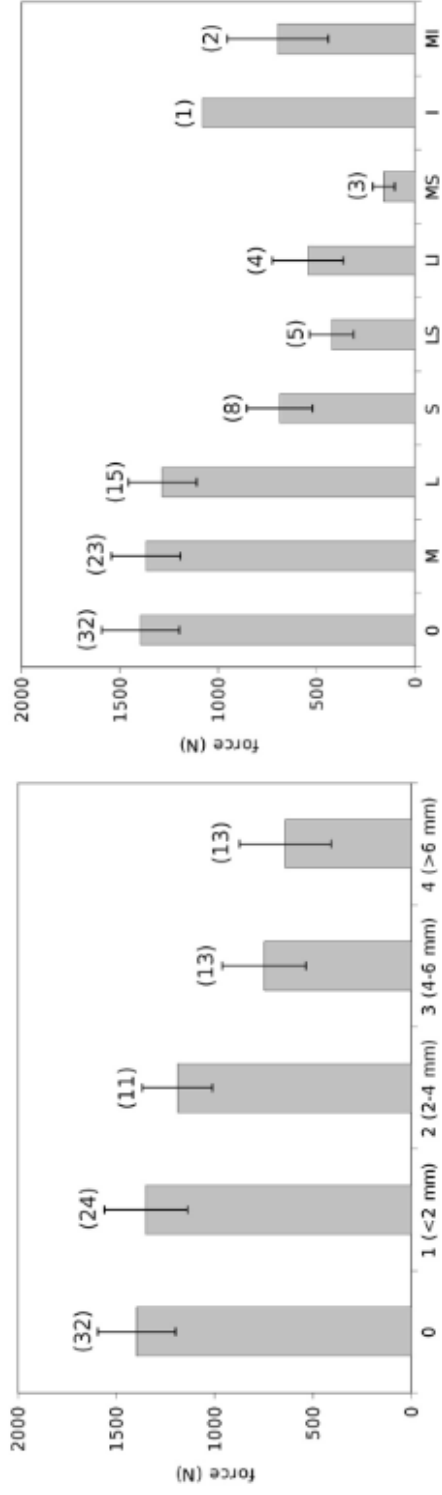
Intrathecal somatosensory and motor nerve roots follow closely along the medial aspect of the pedicle therefore this type of breach carries the highest

possibility of neurological damage (Manbach et al 2014, Mirkovic et al 1991)

Breaches in the anterior and lateral directions pose a risk to vascular structures, for example the descending aorta and inferior vena cava which lay directly over the anterior surface of the vertebral bodies, as well as their branches and tributaries in close proximity to the cord (Manbachi et al 2014). Inferiorly the spinal nerves exit the intervertebral foramina directly inferior to the pedicles, and afterwards run near to the lateral cortex of the pedicle of the next vertebral body (Mirkovic et al 1991).

Misplacement of a pedicle screw can also have a great effect on the primary stability of the screw. A 2013 study by Costa et al. analyzed the pullout strength of 88 pedicle screws implanted into the pedicles of porcine lumbar vertebral bodies. As seen in Figure 7 pullout strength can be markedly reduced with large cortical violation. Additionally the magnitude of the cortical violation is dependant on the direction of the breach with those in the inferior and superior directions resulting in more significant reduction in pullout strength than breaches in the medial and lateral directions (Costa et al 2013).

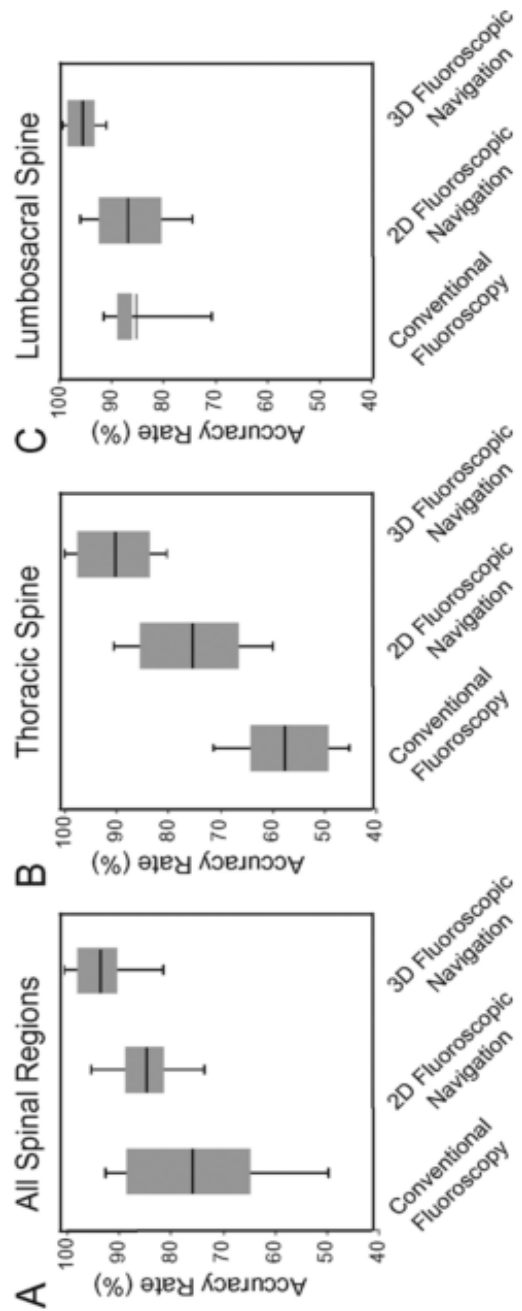




**Figure 8 Pullout strength.** Pullout strength is reduced when breeches occur. Left: mean and 95% confidence interval pullout strength (N) versus grades of breach according to length of exposed screw (mm) Right: mean and 95% confidence interval pullout strength vs direction of breach, m = medial, l = lateral, s = superior, I = inferior (figure taken from Costa et al 2013).

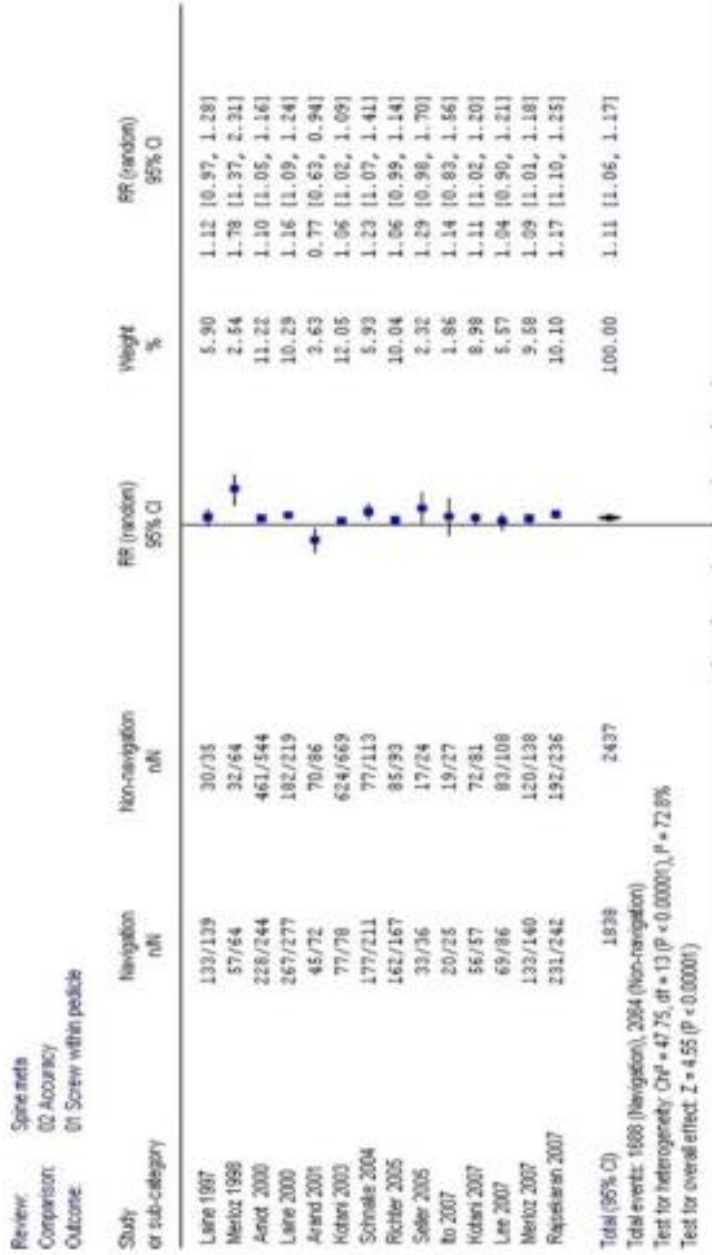
## **Accuracy**

To increase the accuracy of pedicle screw placement, intraoperative navigation is often used for the insertion of pedicle screws. A 2014 meta-analysis which compared the accuracy of navigated screw placement to conventional screw placement was conducted by Mason et al in 2013. In total, 30 studies were included in the analysis including 1973 patients in whom 9310 pedicle screws were inserted. Their findings, seen in figure 8, were that “with conventional fluoroscopy, 2532 of 3719 screws were inserted accurately (68.1% accuracy); with 2D fluoroscopic navigation, 1031 of 1223 screws were inserted accurately (84.3% accuracy); and with 3D fluoroscopic navigation, 4170 of 4368 screws were inserted accurately (95.5% accuracy)” (Mason et al 2013).

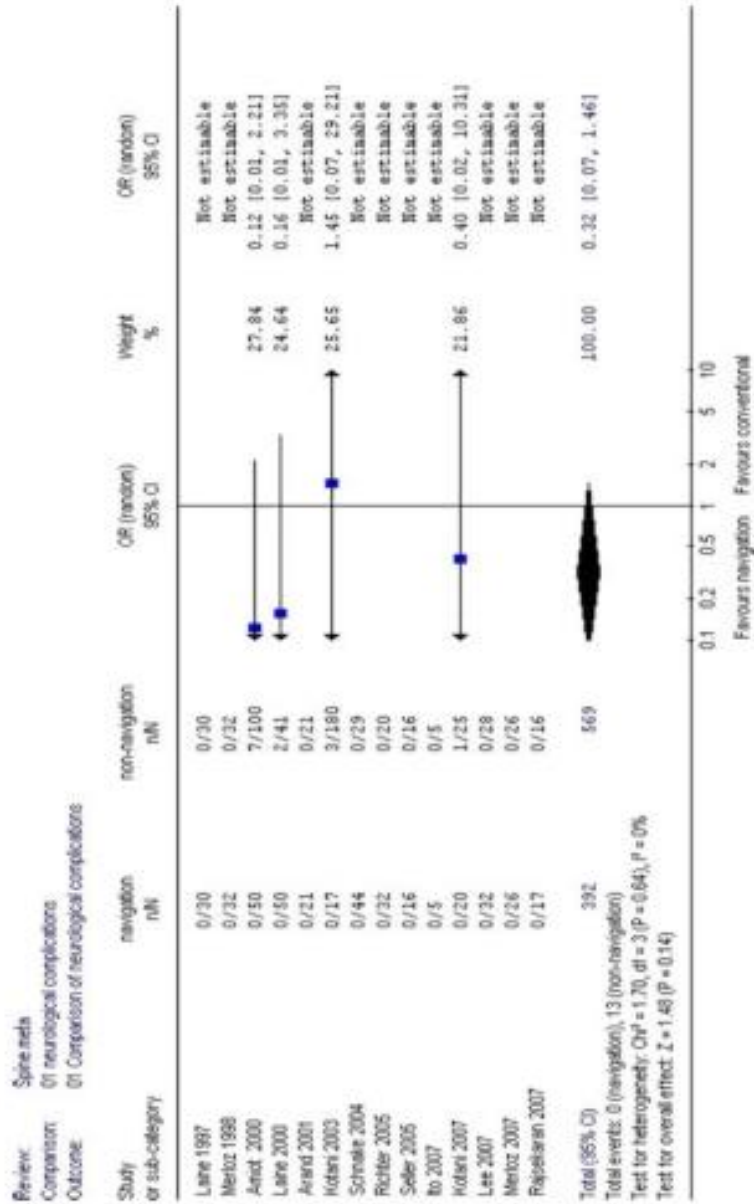


**Figure 9 Accuracy meta-analysis** Meta-analysis of accuracy using either conventional technique or computer aided navigation (taken from Mason et al 2013)

A previous meta-analysis from 2010 by Verma et al. examined 23 studies, 14 of which directly compared navigated to non-navigated controls. There was a statistically significant increase in accuracy in screw placement with navigation , 91.8% (n/N = 1,688/1,838) screws placed correctly, versus conventional techniques, 84.7% (n/N = 2,064/2,437) ( $P < .00001$ ). Additionally, there were fewer patients experiencing neurological complications, 0% 0/392 navigated versus 2.3% 13/569 non-navigated ( $P = .07$ ), although this result did not reach the level of statistical significance. (Verma et al. 2010) The data from these studies also agrees with previous meta-analyses, reviews, and many other studies which show that navigation provides a clear benefit in accuracy compared to conventional fluoroscopy (Tjardes et al. 2010, Liu et al 2005, Seller et al 2005, Laine et al 2000, Rajasenkarán et al 2007, Ravi et al 2010)



**Figure 10 Accuracy Meta-Analysis II.** Forest plot depicting accuracy of screw placement in 14 studies which compared navigated screw placement with a control group receiving non-navigated screw placement (Figure taken from Verma et al. 2010).



**Figure 11: Forest plot depicting neurological complications.**  
 Complications in 14 trials which compared navigated screw placement to conventional non-navigated placement (Figure taken from Verma et al. 2010).

## **Radiation Exposure**

Radiation exposure is a potential hazard for surgeons and operating staff who routinely use fluoroscopy in their practice. There have been reports of increased incidence of thyroid carcinoma among orthopedic surgeons (Dewey and Incoll 1998). Observed radiation dose rates in pedicle screw insertion surgery have been significantly higher than during other orthopedic procedures (UI Haque et al 2006). In one observational study, a spinal surgeon's yearly exposure to radiation was projected to be 13.49 milliSieverts of whole body radiation per year (UI Haque et al 2006). Although this does fall under the limits for exposure according to the National Council on Radiation Protection's guideline of 50 milliseiverts of whole body radiation per year, this is more than 13 times the exposure of the general public. This projection was based on the exposure of a surgeon with 30 years of experience, a young trainee would likely take longer to perform each procedure and thus be exposed to even more radiation. Additionally, those operating staff on the side of the table ipsilateral to the scanner, usually the first assist and nursing staff, can receive a dose 25 times greater than the operating surgeon (UI Haque et al 2006). Studies have shown a statistically significant association between working as an orthopedic surgeon and increased risk of tumours (Mastrangelo et al). Because computer assisted navigation can cut down drastically on fluoroscopy time, it can greatly reduce the exposure of the

operating staff and surgeon to radiation. In a cadaver study of 48 screws placed, 24 under conventional fluoroscopic technique and 24 using computer aided navigation via three-dimensional fluoroscopy with automatic registration, a statistically significant reduction in radiation exposure was found (Smith et al 2008). The reduction was drastic, mean radiation exposure to the torso was 4.33 +/- 2.66 mRem with standard fluoroscopy, and 0.33+/- .82 mRem with navigation (Smith et al 2008). With the use of three-dimensional fluoroscopy with automatic registration, the surgeon and operating staff can stand outside the room or behind a protective covering while the scan is performed. Additionally, because guidance allows for screws to be placed more accurately and reduces the chance of negative outcomes, there will be an even greater reduction in exposure because of the reduction in need for revision surgery.



## **COST-BENEFIT ANALYSIS**

Although it can be seen that navigation offers a benefit in terms of increased accuracy, its adoption has met resistance for several reasons, one of which is the high cost of the systems themselves, which can range in the hundreds of thousands of dollars (Hodgson 2008). However, by reducing the need for revision surgery as well as reducing operating room (OR) time, navigation may provide a considerable cost savings. In a prospective case series of 100 patients undergoing navigated pedicle screw placement as compared to the previous group of 100 patients who had underwent conventional screw placement, a cost savings of \$71,286 per 100 patients was estimated based on a reduction from a revision rate of 3% to 0% with navigation (Watkins et al. 2010). The initial cost of the system they used was \$475,000, which means they would need to do six hundred and sixty six cases before recouping the cost of the machine. In a separate study on cost-effectiveness, another hospital group was able to reduce their revision rate from 1% to 0%, projecting a cost savings of \$17,750 per 100 patients, and approximately \$40 million dollars nationwide (Hodges et al 2012). This is a much more modest savings when considering the authors report that some modern navigation systems can cost up to \$1 million dollars (Hodges et al 2012).

Cost savings can also be generated by reducing operative times. One study reported a significant ( $P < .001$ ) decrease in operative time when using image

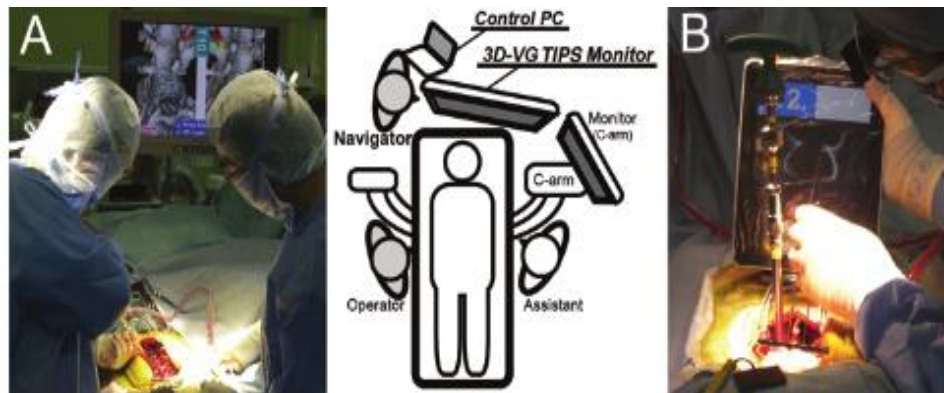
navigation compared to conventional fluoroscopy, with an average of 40 minutes less per case (Sasso and Garrido 2007). One minute of time in the operating room costs an average of \$62 (Macario 2010). At that rate, 40 minutes less time per case would generate a savings of approximately \$2480, however this simplistic analysis does not account for fixed costs, and also assumes that those time savings would be filled with additional cases. Additionally, it should be noted that in the first year of adoption, there may actually be an increase in time per case due to the learning curve of the new system (Sasso and Garrido 2007).

## **FUTURE DIRECTION**

Although both the software and hardware of modern day navigation systems has improved dramatically over the years, there has yet to be a substantial change in the way that the image data is utilized by the surgeons because the data is still displayed on a 2D monitor. By displaying the image data in a different manner, there is a chance to increase the effectiveness of the navigation system, without dramatically increasing the costs. To illustrate this point it is useful to revisit the earlier example of the GPS navigation system. Imagine if, in order to use your car's GPS system, you had to type on a keyboard in the passenger seat, and have the data displayed on the roof of your vehicle. This would necessarily be burdensome and limit the utility of the system overall. Because you need to keep your hands on the wheel, you would need a second person to operate the GPS system, and even then you would need to remove your eyes from the road to look at the navigation monitor. Clearly, your car's navigation system would be much more efficient if it could display information in your field of view, and ideally even take voice activated direction; and both of these are standard features of modern navigation systems.

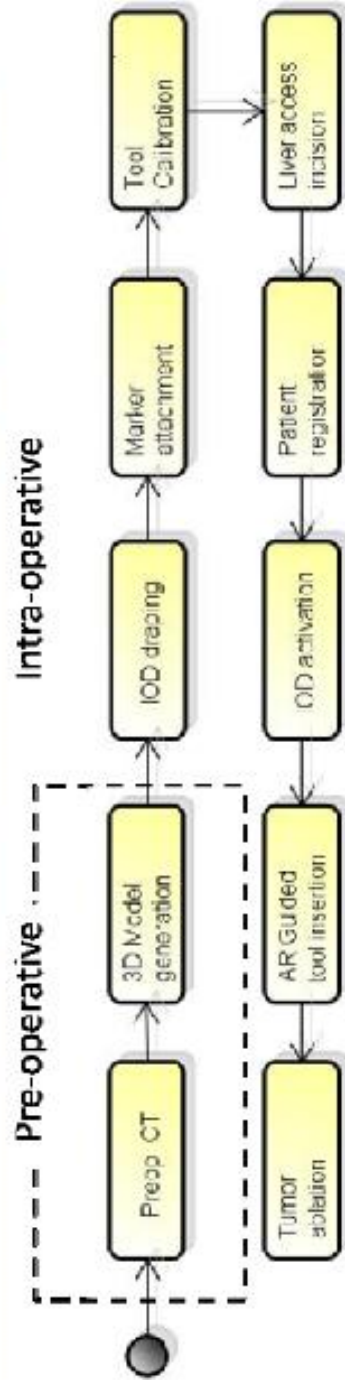
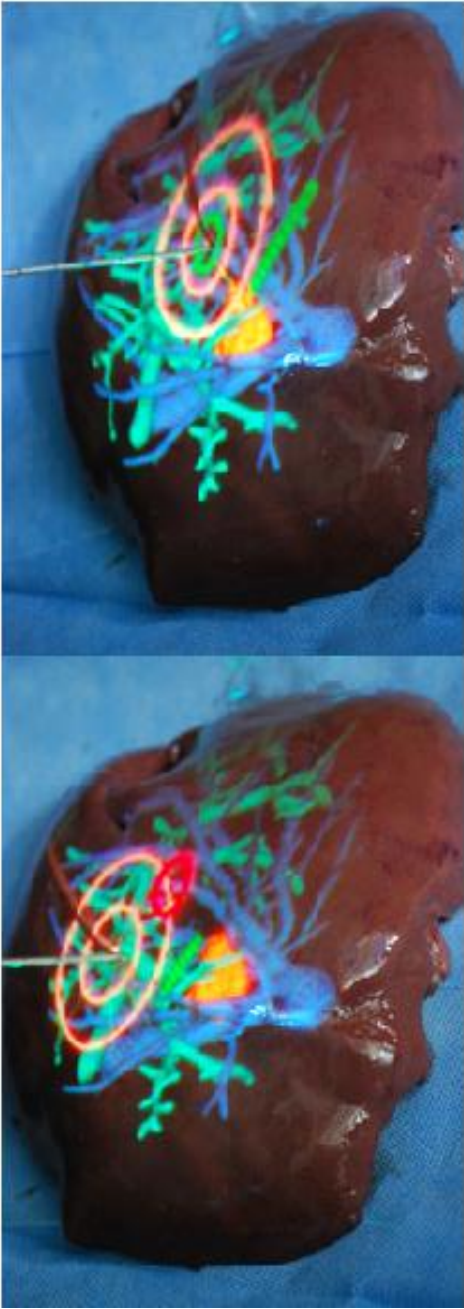Abe et al. in 2011 performed a study comparing the use of a simple visual guide to conventional fluoroscopy. Rather than use a tracking and navigation system, the proximity of the device to the anatomy allows the surgeon to view the

imaging without moving his head from the field of view, and thus he can place the screw more accurately than under fluoroscopy alone. In the study performed by Abe et al. they found an incidence of malpositioning in 23/199 (11.6%) screws which were placed with a conventional fluoroscopic guidance technique versus 9/198 (4.5%) screws placed with the 3D visual guidance technique ( $p=0.017$ ) (Abe et al 2011). However, as can be seen in the Figure 10, the Ipad® still has limited utility because it requires a set of hands to operate, and isn't fully in the field of view.



**Figure 12 Ipad® Display** In this simple setup, a pre-operative CT scan is taken of the patient's spine, marked up using preoperative planning software, and displayed on a portable display (Figure taken from Abe et al 2011)

One solution which seeks to utilize pre-operative imaging and surgical navigation by uniquely displaying the information on the target tissue itself, is that of augmented reality overlay projection. Seen in Figure 11, CT data is used to compile a 3D image of the vascular structure of the liver, as well as the targeted tumor, and is projected directly onto the surface of the liver using a specialized RGB laser (Gavaghan et al 2012) Additionally, a green “target” is imposed which will stay green if the ablation tool is lined up properly, or will otherwise turn red. This system could prove useful however, it does have its own complications. Projecting onto the surface of a porcine liver is one thing, but projecting into a body cavity, onto a very uneven surface such as that of the spinal anatomy, could prove very challenging. Additionally, it is necessary to compensate for the parallax error that would arise from the surgeons viewing angle. Overcoming these hurdles would no doubt add to the expense of the system, further limiting its utility.



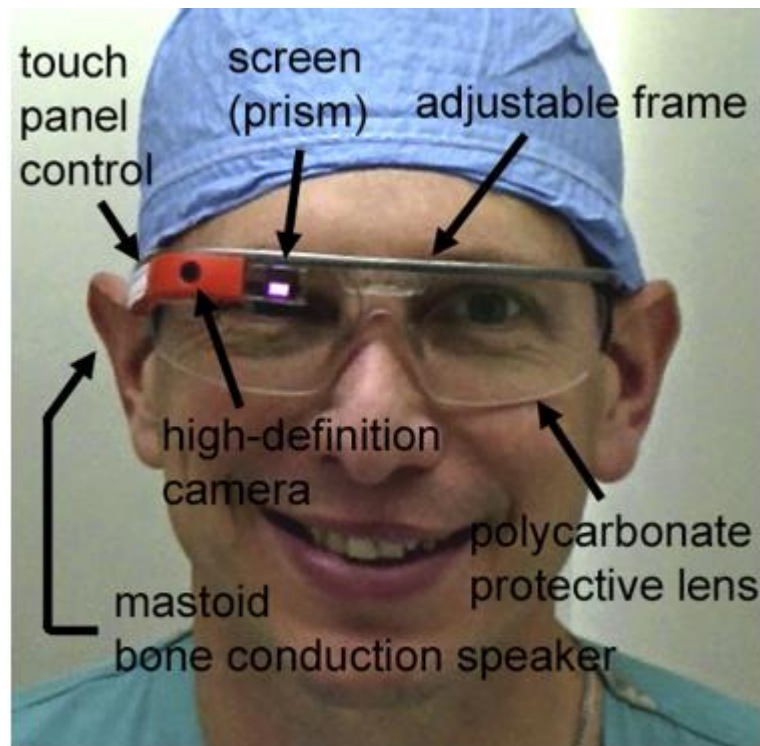
**Figure 13 Augmented Reality.** Top, Augmented reality overlay projection for tumor ablation. The vasculature of the liver, as well as the targeted tumor are projected onto the surface of the liver via a specialized RGB laser. Bottom, workflow schematic. (Figures taken from Gavaghan et al 2012)

In order to solve these issues without adding undue expense, Google Glass®, or a similar type of display, could be considered for surgical navigation applications. Google Glass® is a wearable display that also incorporates voice control, a speaker, and a high definition video camera. It has recently found its way into the healthcare setting, with hopes that it will allow doctors to multitask, for example interview their patient face to face, while at the same time reviewing their labs or imaging. In the operating room, it has been used for telementoring because it can be used to shoot hands free video while the surgeon operates and narrates the procedure, to teach physicians at remote locations (Muensterer 2014). It is comparatively cheap, with a current price of \$1500 USD. Although there would certainly be some cost involved in developing the applications, these would likely be outweighed by the reduced need for ancillary staff in the operating room due to the hands-free nature of the device. Because it is worn rigidly on the head, there is no need to correct for parallax error and it also eliminates the pitfalls of projecting onto an uneven surface.

Recently, Glass® has been Dr. Brion Benninger to view ultrasound images, obtained using a fingertip-worn ultrasound probe during physical examination (Benninger 2014). This serves as an extremely useful proof of concept for several reasons. Ultrasound images are typically stored in the same DICOM (Digital Imaging and Communications in Medicine) file format, and viewed using a PACS (picture archiving and communication system) viewer. Because data from CT, MRI, and X-ray examinations are all stored and viewed



using the same file formats and viewers, it is likely that Glass® would be able to display these file formats as well. Additionally, he has demonstrated the ability for this device to display these types of images acquired in real time, a property which would hopefully carry over to the ability to display a useful navigation image with a tool tracked in real time (Benninger 2014).



**Figure 14 Components of a Google Glass® .** The Google Glass® device has a small screen which allows it to display images in the surgeons field of view unobtrusively. Additionally it is equipped with a high definition camera and a speaker which enable telementoring and a microphone which allows for hands-free voice control (Figure taken from Muensterer et al 2014)

## CONCLUSIONS

Surgical navigation is rapidly evolving and it is now possible to combine advanced 3-D pre-operative imaging with intra-operative imaging and optical tracking to provide surgeons with real time navigation that allows them to operate with greater accuracy than ever before. By improving accuracy, navigation decreases the likelihood of negative outcomes, reduces radiation exposure to both the patient and staff, decreases OR time, and produces cost savings. As such, in the field of spine surgery, specifically in the placement of pedicle screws for spinal fusion, navigation should be utilized whenever possible. As technology continues to advance, opportunities abound for innovation to make surgical navigation a more effective and more widely adopted tool by lowering costs, and increasing utility.

To date, great progress has been made in developing new innovative medical imaging devices for acquiring data. Similarly, data processing techniques for integrating that data into a useful navigation tool have become well adopted. However, the way that the final result, the navigation display is presented, has yet to change substantially over many years. If augmented reality devices such as Google Glass® could be used to display navigation data, they would be a

substantial advancement over current technologies because they allow for hands free operation while maintaining the surgeon's vision in the surgical field, allowing for the data to be accessed more readily and therefore enhancing its utility.

## REFERENCES

- Abe, Y., Ito, M., Abumi, K., Kotani, Y., Sudo, H., & Minami, A. (2011). A novel cost-effective computer-assisted imaging technology for accurate placement of thoracic pedicle screws. *Journal of Neurosurgery. Spine*, 15(5), 479–485. doi:10.3171/2011.6.SPINE10721
- Arslan, M., Cömert, A., Açar, H. İ., Özdemir, M., Elhan, A., Tekdemir, İ., ... Uğur, H. Ç. (2011). Lumbosacral intrathecal nerve roots: an anatomical study. *Acta Neurochirurgica*, 153(7), 1435–1442. doi:10.1007/s00701-011-0952-2
- Benninger, B. (2014). Google Glass, ultrasound and palpation: The anatomy teacher of the future? *Clinical Anatomy*, n/a–n/a. doi:10.1002/ca.22480
- Berend, M. E., Ritter, M. A., Meding, J. B., Faris, P. M., Keating, E. M., Redelman, R., ... Davis, K. E. (2004). Tibial component failure mechanisms in total knee arthroplasty. *Clinical Orthopaedics and Related Research*, (428), 26–34.
- Brainlab. Spine Navigation. 2013 Retrieved from <https://www.brainlab.com/wp-content/uploads/2014/01/Brochure-Spine-Navigation.pdf>
- Chappell, E. T., Pare, L., Dolich, M. O., Lekawa, M. E., & Salepour, M. (2005). Frameless stereotaxy to facilitate anterolateral thoracolumbar surgery: technique. *Neurosurgery*, 56(1 Suppl), 110–116; discussion 110–116.
- Cobb, J. P., & Andrews, B. L. (2012). Are robots taking over orthopaedic surgery? *Bone and Joint* 360, 1(3), 2–4. doi:10.1302/2048-0105.13.360038
- Coffey, R. J. (2009). Printed Stereotactic Atlases, Review. In A. M. Lozano, P. L. Gildenberg, & R. R. Tasker (Eds.), *Textbook of Stereotactic and Functional Neurosurgery* (pp. 345–371). Springer Berlin Heidelberg. Retrieved from [http://link.springer.com/referenceworkentry/10.1007/978-3-540-69960-6\\_25](http://link.springer.com/referenceworkentry/10.1007/978-3-540-69960-6_25)
- Costa, F., Villa, T., Anasetti, F., Tomei, M., Ortolina, A., Cardia, A., ... Galbusera, F. (2013). Primary stability of pedicle screws depends on the screw positioning and alignment. *The Spine Journal*, 13(12), 1934–1939. doi:10.1016/j.spinee.2013.03.046

Dede, O., Ward, W. T., Bosch, P., Bowles, A. J., & Roach, J. W. (2014). Using the Freehand Pedicle Screw Placement Technique in Adolescent Idiopathic Scoliosis

Dewey, P., & Incoll, I. (1998). Evaluation of thyroid shields for reduction of radiation exposure to orthopaedic surgeons. *The Australian and New Zealand Journal of Surgery*, 68(9), 635–636.

Surgery: What Is the Incidence of Neurological Symptoms Secondary to Misplaced Screws? *Spine*, 39(4), 286–290.  
doi:10.1097/BRS.0000000000000127

Gavaghan, K. A., Anderegg, S., Peterhans, M., Oliveira-Santos, T., & Weber, S. (2012). Augmented Reality Image Overlay Projection for Image Guided Open Liver Ablation of Metastatic Liver Cancer. In C. A. Linte, J. T. Moore, E. C. S. Chen, & D. R. H. III (Eds.), *Augmented Environments for Computer-Assisted Interventions* (pp. 36–46). Springer Berlin Heidelberg. Retrieved from [http://link.springer.com/chapter/10.1007/978-3-642-32630-1\\_4](http://link.springer.com/chapter/10.1007/978-3-642-32630-1_4)

Gray, Henry. *Anatomy of the Human Body*. Philadelphia: Lea & Febiger, 1918; Bartleby.com, 2000. Retrieved from [www.bartleby.com/107/](http://www.bartleby.com/107/).

Grzeszczuk, R., Chin, S., Fahrig, R., Abassi, H., Holz, H., Kim, D., ... Shahidi, R. (2000). A Fluoroscopic X-Ray Registration Process for Three-Dimensional Surgical Navigation. In S. L. Delp, A. M. DiGoia, & B. Jaramaz (Eds.), *Medical Image Computing and Computer-Assisted Intervention – MICCAI 2000* (pp. 551–556). Springer Berlin Heidelberg. Retrieved from [http://link.springer.com/chapter/10.1007/978-3-540-40899-4\\_56](http://link.springer.com/chapter/10.1007/978-3-540-40899-4_56)

Ul Haque, M., Shufflebarger, H. L., O'Brien, M., & Macagno, A. (2006). Radiation exposure during pedicle screw placement in adolescent idiopathic scoliosis: is fluoroscopy safe? *Spine*, 31(21), 2516–2520.  
doi:10.1097/01.brs.0000238675.91612.2f

Hebecker, A. (2004). C-Arm-Based Navigation. In *Navigation and Robotics in Total Joint and Spine Surgery* (pp. 17–23). Springer Berlin Heidelberg. Retrieved from [http://link.springer.com/chapter/10.1007/978-3-642-59290-4\\_3](http://link.springer.com/chapter/10.1007/978-3-642-59290-4_3)

Hicks, J. M., Singla, A., Shen, F. H., & Arlet, V. (2010). Complications of pedicle screw fixation in scoliosis surgery: a systematic review. *Spine*, 35(11), E465–470. doi:10.1097/BRS.0b013e3181d1021a

Hodges, S. D., Eck, J. C., & Newton, D. (2012b). Analysis of CT-based Navigation System for Pedicle Screw Placement. *Orthopedics*, 35(8), e1221–e1224. doi:10.3928/01477447-20120725-23

Jaramaz, B., & Iii, A. M. D. (2004). CT-Based Navigation Systems. In *Navigation and Robotics in Total Joint and Spine Surgery* (pp. 10–16). Springer Berlin Heidelberg. Retrieved from [http://link.springer.com/chapter/10.1007/978-3-642-59290-4\\_2](http://link.springer.com/chapter/10.1007/978-3-642-59290-4_2)

Jenny, J.-Y., & Boeri, C. (2001). Navigiert implantierte Knie totalendoprothesen - Eine Vergleichsstudie zum konventionellen Instrumentarium. *Zeitschrift Für Orthopädie*, 139(2), 117–119. doi:10.1055/s-2001-15041

Kraus, M., Weckbach, S., Jones, A., Krischak, G., Gebhard, F., & Schöll, H. (2013). Image guidance shortens the learning curve for K-wire placement – an experimental study. *The International Journal of Medical Robotics and Computer Assisted Surgery*, 9(1), 52–57. doi:10.1002/rcs.1476

Laine, T., Lund, T., Ylikoski, M., Lohikoski, J., & Schlenzka, D. (2000). Accuracy of pedicle screw insertion with and without computer assistance: a randomised controlled clinical study in 100 consecutive patients. *European Spine Journal*, 9(3), 235–240. doi:10.1007/s005860000146

Liebergall, M., Mosheiff, R., & Segal, D. (2003). Navigation in orthopaedic trauma. *Operative Techniques in Orthopaedics*, 13(2), 64–72. doi:10.1053/otor.2003.0179

Liu, Y., Tian, W., Liu, B., Li, Q., Hu, L., Li, Z., ... Sun, Y. (2005). [Accuracy of CT-based navigation of pedicle screws implantation in the cervical spine compared with X-ray fluoroscopy technique]. *Zhonghua Wai Ke Za Zhi [Chinese Journal of Surgery]*, 43(20), 1328–1330.

M R Zindrick, L. L. W. (1987). Analysis of the morphometric characteristics of the thoracic and lumbar pedicles. *Spine*, 12(2), 160–6. doi:10.1097/00007632-198703000-00012

Macario, A. (2010). What does one minute of operating room time cost? *Journal of Clinical Anesthesia*, 22(4), 233–236. doi:10.1016/j.jclinane.2010.02.003

Manbachi, A., Cobbold, R. S. C., & Ginsberg, H. J. (2014). Guided pedicle screw insertion: techniques and training. *The Spine Journal: Official Journal of the North American Spine Society*, 14(1), 165–179. doi:10.1016/j.spinee.2013.03.029

Mason, A., Paulsen, R., Babuska, J. M., Rajpal, S., Burneikiene, S., Nelson, E. L., & Villavicencio, A. T. (2013). The accuracy of pedicle screw placement using intraoperative image guidance systems. *Journal of Neurosurgery: Spine*, *20*(2), 196–203. doi:10.3171/2013.11.SPINE13413

Md, J. Z., Md, G. K., Md, E. K., Prof, N. P. S., & Md, M. O. (2009). Computer-navigated Iliosacral Screw Insertion Reduces Malposition Rate and Radiation Exposure. *Clinical Orthopaedics and Related Research*, *467*(7), 1833–1838. doi:10.1007/s11999-008-0632-6

Mirkovic, S., Abitbol, J. J., Steinman, J., Edwards, C. C., Schaffler, M., Massie, J., & Garfin, S. R. (1991). Anatomic consideration for sacral screw placement. *Spine*, *16*(6 Suppl), S289–294.

Mobbs, R. J., Sivabalan, P., & Li, J. (2011). Technique, challenges and indications for percutaneous pedicle screw fixation. *Journal of Clinical Neuroscience: Official Journal of the Neurosurgical Society of Australasia*, *18*(6), 741–749. doi:10.1016/j.jocn.2010.09.019

Muensterer, O. J., Lacher, M., Zoeller, C., Bronstein, M., & Kübler, J. (2014). Google Glass in pediatric surgery: An exploratory study. *International Journal of Surgery*, *12*(4), 281–289. doi:10.1016/j.ijisu.2014.02.003

Nolte, L.-P., & Langlotz, F. (2004). Basics of Computer-Assisted Orthopaedic Surgery (CAOS). In *Navigation and Robotics in Total Joint and Spine Surgery* (pp. 3–9). Springer Berlin Heidelberg. Retrieved from [http://link.springer.com/chapter/10.1007/978-3-642-59290-4\\_1](http://link.springer.com/chapter/10.1007/978-3-642-59290-4_1)

Ochs, B. G., Gonser, C., Shiozawa, T., Badke, A., Weise, K., Rolaufts, B., & Stuby, F. M. (2010). Computer-assisted periacetabular screw placement: Comparison of different fluoroscopy-based navigation procedures with conventional technique. *Injury*, *41*(12), 1297–1305. doi:10.1016/j.injury.2010.07.502

Oh, H. S., Kim, J.-S., Lee, S.-H., Liu, W. C., & Hong, S.-W. (2013). Comparison between the accuracy of percutaneous and open pedicle screw fixations in lumbosacral fusion. *The Spine Journal*, *13*(12), 1751–1757. doi:10.1016/j.spinee.2013.03.042

Rahmathulla, G., Nottmeier, E. W., Pirris, S. M., Deen, H. G., & Pichelmann, M. A. (2014). Intraoperative image-guided spinal navigation: technical pitfalls and their avoidance. *Neurosurgical Focus*, *36*(3), E3. doi:10.3171/2014.1.FOCUS13516



Rajasekaran, S., Vidyadhara, S., Ramesh, P., & Shetty, A. P. (2007). Randomized clinical study to compare the accuracy of navigated and non-navigated thoracic pedicle screws in deformity correction surgeries. *Spine*, 32(2), E56–64. doi:10.1097/01.brs.0000252094.64857.ab

Ravi, B., Zahrai, A., & Rampersaud, R. (2010). Clinical Accuracy of Computer-Assisted Two-Dimensional Fluoroscopy for the Percutaneous Placement of Lumbosacral Pedicle Screws: *Spine*, 1. doi:10.1097/BRS.0b013e3181cbfd09

Reinhold, M., Magerl, F., Rieger, M., & Blauth, M. (2007). Cervical pedicle screw placement: feasibility and accuracy of two new insertion techniques based on morphometric data. *European Spine Journal*, 16(1), 47–56. doi:10.1007/s00586-006-0104-1

Sasso, R. C., & Garrido, B. J. (2007). Computer-assisted spinal navigation versus serial radiography and operative time for posterior spinal fusion at L5-S1. *Journal of Spinal Disorders & Techniques*, 20(2), 118–122. doi:10.1097/01.bsd.0000211263.13250.b1

Schröder, J., & Wassmann, H. (2006). Spinal navigation: an accepted standard of care? *Zentralblatt Für Neurochirurgie*, 67(3), 123–128. doi:10.1055/s-2006-942146

Seller, K., Wild, A., Urselmann, L., & Krauspe, R. (2005). [Prospective screw misplacement analysis after conventional and navigated pedicle screw implantation]. *Biomedizinische Technik. Biomedical Engineering*, 50(9), 287–292. doi:10.1515/BMT.2005.043

Smith, H. E., Welsch, M. D., Sasso, R. C., & Vaccaro, A. R. (2008). Comparison of Radiation Exposure in Lumbar Pedicle Screw Placement With Fluoroscopy Vs Computer-Assisted Image Guidance With Intraoperative Three-Dimensional Imaging. *The Journal of Spinal Cord Medicine*, 31(5), 532–537.

Specht, L. M., & Koval, K. J. (2001). Robotics and computer-assisted orthopaedic surgery. *Bulletin (Hospital for Joint Diseases (New York, N.Y.))*, 60(3-4), 168–172.

Spiegel EA, Wycis HT, & Freed H. (1952). Stereoencephalotomy: Thalamotomy and related procedures. *Journal of the American Medical Association*, 148(6), 446–451. doi:10.1001/jama.1952.02930060028009

Stauff, M. P. (2013). Pedicle screw accuracy and the ramifications of imperfect screw placement. *The Spine Journal*, 13(12), 1758–1759. doi:10.1016/j.spinee.2013.09.040

Stiehl, J. B. (2010). Computer-Assisted Orthopedic Surgery (CAOS): Pros and Cons. In G. R. Scuderi & A. J. Tria (Eds.), *Minimally Invasive Surgery in Orthopedics* (pp. 603–612). Springer New York. Retrieved from [http://link.springer.com.ezproxy.bu.edu/chapter/10.1007/978-0-387-76608-9\\_73](http://link.springer.com.ezproxy.bu.edu/chapter/10.1007/978-0-387-76608-9_73)

Stryker. Spinemap 3D Software Quick Reference Guide. 2010. Retrieved from: <http://strykerneurospine.com/sites/default/files/pdf/information/9100-001-375.pdf>

*Surgical Anatomy and Techniques to the Spine* by Daniel H. Kim, Alexander R. Vaccaro, Curtis A. Dickman, Dosang Cho, Sangkook Lee, and Ilsup Kim | eBook on. (n.d.). Retrieved from <https://www.inkling.com/store/book/surgical-anatomy-techniques-spine-kim-2nd/?chapterId=d54f1322a0e8478b8910e9ac39d79095>

Tjardes, T., Shafizadeh, S., Rixen, D., Paffrath, T., Bouillon, B., Steinhausen, E. S., & Baethis, H. (2010). Image-guided spine surgery: state of the art and future directions. *European Spine Journal*, 19(1), 25–45. doi:10.1007/s00586-009-1091-9

Uruc, V., Ozden, R., Dogramaci, Y., Kalacı, A., Dikmen, B., Yıldız, O. S., & Yengil, E. (n.d.). The comparison of freehand fluoroscopic guidance and electromagnetic navigation for distal locking of intramedullary implants. *Injury*. doi:10.1016/j.injury.2012.12.009

Verma, R., Krishan, S., Haendlmayer, K., & Mohsen, A. (2010). Functional outcome of computer-assisted spinal pedicle screw placement: a systematic review and meta-analysis of 23 studies including 5,992 pedicle screws. *European Spine Journal*, 19(3), 370–375. doi:10.1007/s00586-009-1258-4

Warth, L. C., Callaghan, J. J., Liu, S. S., Klein, G. R., & Hozack, W. J. (2007). Internet Promotion of Minimally Invasive Surgery and Computer-Assisted Orthopedic Surgery in Total Knee Arthroplasty by Members of American Association of Hip and Knee Surgeons. *The Journal of Arthroplasty*, 22(6, Supplement), 13–16. doi:10.1016/j.arth.2007.03.026

Watkins, R. G., Gupta, A., & Watkins, R. G. (2010). Cost-Effectiveness of Image-Guided Spine Surgery. *The Open Orthopaedics Journal*, 4, 228–233. doi:10.2174/1874325001004010228

Zheng, Z., Zhang, Y., Hou, Z., Hao, J., Zhai, F., Su, Y., & Pan, J. (2012). The application of a computer-assisted thermoplastic membrane navigation system in screw fixation of the sacroiliac joint – A clinical study. *Injury*, 43(4), 495–499. doi:10.1016/j.injury.2011.12.022

## CURRICULUM VITAE

### SHERWIN AZAD

20117 Via Medici  
Porter Ranch, CA 91326  
(818) 625-7676 (cell) [sazad@bu.edu](mailto:sazad@bu.edu)  
Born: 1986

#### Education

Candidate, M.S. in Medical Sciences, Boston University. School of Medicine  
Degree Expected Jan 2015

B.S. in Biomedical Engineering; optional specialization in Biophotonics.  
University of California, Irvine, Sept. 2009.

#### Work Experience

(Aug 2013 – Jun 2014)

New England Baptist Hospital  
Medical Assistant/ Student Intern  
Contact: James Bono, MD 617-754-5901  
Marilyn Griffin MD 617-754-6199  
Eric Woodard, MD 617-754-6576

Los Angeles Orthopaedic Hospital  
Implant Retrieval Laboratory  
Implant Biomechanics Laboratory  
Contact: Pat Campbell, PhD (213)742-1134,  
[pcampbell@mednet.ucla.edu](mailto:pcampbell@mednet.ucla.edu)

(Sept 2011- Aug 2012)

Los Angeles Orthopaedic Hospital  
Urgent Care  
Contact: Tigran Avoian, MD, PhD  
[tavoian@mednet.ucla.edu](mailto:tavoian@mednet.ucla.edu)

(April 2012 August 2012)

#### Volunteer

Valley Presbyterian Hospital  
Clinical Care Extender Internship

(Jan 2011- Dec 2011)

## **Publications**

Azad, S, Charles, N, Campbell, P, & Amstutz, H. C. (2013). Implant Retrieval Analysis of Bilateral Hip Resurfacings Obtained at Autopsy: A Case Report. *The Journal of Bone & Joint Surgery Case Connector*, 3(2), e51 1–7.  
doi:10.2106/JBJS.CC.L.00245

Campbell, P., Ebramzadeh, E., Azad, S., Billi, F., Lu, Z., & McKellop, H. (2013). Analysis of Comprehensive Measurements from Retrieved Implants to Determine Factors Contributing to Failure Modes and Wear. In S. M. Kurtz, A. S. Greenwald, W. H. Mihalko, & J. E. Lemons (Eds.), *Metal-On-Metal Total Hip Replacement Devices* (pp. 193–208). 100 Barr Harbor Drive, PO Box C700, West Conshohocken, PA 19428-2959: ASTM International.