

2016

Multidisciplinary treatment craniofacial anomalies and its effects on children's oral cavity, psychology, and speech

<https://hdl.handle.net/2144/19485>

Downloaded from DSpace Repository, DSpace Institution's institutional repository

BOSTON UNIVERSITY
SCHOOL OF MEDICINE

Thesis

**MULTIDISCIPLINARY TREATMENT OF CRANIOFACIAL ANOMALIES
AND ITS EFFECTS ON CHILDREN'S ORAL CAVITY, PSYCHOLOGY, AND
SPEECH**

by

LEMMA M. SALEM

B.S., Boston University, 2015

Submitted in partial fulfillment of the
requirements for the degree of
Master of Science

2016

© 2016 by
LEMMA SALEM
All rights reserved

Approved by

First Reader

Theresa A. Davies, Ph.D.
Director, M.S. in Oral Health Sciences Program
Assistant Professor of Medical Sciences & Education

Second Reader

Maura A. Kelley, M.D.
Clinical Instructor, Department of Medicine

ACKNOWLEDGMENTS

I would like to thank my parents, Raedah and Munal Salem, and brothers, Ghanim and Faris Salem, for always supporting me in my future endeavors.

I would also like to thank my director, Dr. Therese Davies, in encouraging me to work my hardest and guiding me through my Master's program, and my professor, Dr. Maura Kelley, for sparking this topic of interest and assisting me with this paper.

**MULTIDISCIPLINARY TREATMENT OF CRANIOFACIAL ANOMALIES
AND ITS EFFECTS ON CHILDREN'S ORAL CAVITY, PSYCHOLOGY, AND
SPEECH**

LEMMA SALEM

ABSTRACT

There are many craniofacial anomalies that exist in the oral mucosa, gingiva, lips, tongue, maxilla, mandible, floor of the mouth, palate, and teeth. These anomalies cause secondary issues such as airway obstruction, respiratory problems, feeding problems, ear disease, distal systemic issues, and speech and communication problems. Children that experience craniofacial anomalies and subsequent problems are often at a disadvantage with medical and dental related consequences, and especially speech, communication, and often present with psychosocial concerns. This paper explores such anomalies, consequential problems, and emphasizes the importance of having a multidisciplinary team when treating patients with craniofacial anomalies.

Multidisciplinary teams consist of otolaryngologists, plastic surgeons, general dentists, prosthodontists, orthodontists, oral surgeons, pediatricians, neurologists, geneticists, social workers, psychologists, audiologists, and speech therapists. Based on past studies and data, multidisciplinary treatment has shown not only to provide the best options to correct an anomaly, but also to optimize the overall health and well-being of an individual as well. Multidisciplinary treatment of craniofacial anomalies outlines a coherent, inclusive, and revolutionized way on how to holistically treat a patient. This approach is present in the healthcare realm, but often underrated and not adopted by all

healthcare professionals; this paper will demonstrate how such an approach will advance healthcare.

Surgery removes, corrects, or improves a condition that exists in the oral cavity or oropharynx. Nevertheless, surgery often causes subsequent conditions and may even not be successful. Among the many disciplines exercised in treating patients with craniofacial anomalies and conditions, this paper highlights the importance of speech and language pathologists, psychologists, dentists, orthodontists, and geneticists to be included in the treatment plan. Studies demonstrated that each discipline's responsibility, when implemented in a coordinated and timely fashion, can improve the outcomes, possibly prevent ensuing conditions, and therefore, optimize an individual's health and quality of life.

TABLE OF CONTENTS

TITLE.....	i
COPYRIGHT PAGE.....	ii
READER APPROVAL PAGE.....	iii
ACKNOWLEDGMENTS	iv
ABSTRACT.....	v
TABLE OF CONTENTS.....	vii
LIST OF TABLES	viii
LIST OF FIGURES	ix
LIST OF ABBREVIATIONS.....	x
INTRODUCTION	1
LITERATURE REVIEW	4
Oral Tumors and Cancers:	4
Craniofacial Anomalies:	14
Secondary Problems:	26
PRESENTATION OF PUBLISHED RESULTS	31
DISCUSSION.....	44
REFERENCES	48
CURRICULUM VITAE.....	51

LIST OF TABLES

Table	Title	Page
1	Summary of Tongue Anomalies & Abnormalities	20
2	Surgical Treatment & Intervention of Cleft Lip & Palate by Age	37
3	Findings in Parents' Perception of General Health in their Children	40
4	History & Growth of the Genetics' Realm	41

LIST OF FIGURES

Figure	Title	Page
1	Capillary Hemangioma of the Oral Cavity	5
2	Thick Leukoplakia	10
3	Erythroplakia for the Soft Palate	11
4	Oral Squamous Cell Carcinoma	13
5	Oral Mucosal Lesions	16
6	Hereditary Gingival Fibromatosis	18
7	Fissured Tongue	21
8	Types of Cleft Palate	24
9	Types of Cleft Lips	26
10	Acrylic Plates	35

LIST OF ABBREVIATIONS

ASHA	American Speech-Language-Hearing Association
BMS	Burning Mouth Syndrome
CCFA-IL	Center of Craniofacial Anomalies at University of Illinois
CL	Cleft Lip
CLP	Cleft Lip & Palate
CP	Cleft Palate
HPV	Human Papillomavirus
SLP	Speech & Language Pathologist
VP	Velopharyngeal
VPI	Velopharyngeal Insufficiency
WHO	World Health Organization

INTRODUCTION

There is an array of anomalies that take place in the oral cavity and the oropharynx. According to medical terms, an anomaly is something that deviates from the normal or out of the ordinary; often, anomalies are assumed to result from something abnormal prior to or at birth. There are several major causes of anomalies, and these categories of anomaly will be addressed. Many of these anomalies are genetic and/or congenital. Regardless of the cause, congenital anomalies are always present at birth and either categorized as hereditary or nonhereditary. Genetic anomalies do not necessarily appear at birth, but become detectable later on in life (Zalzal & Cotton, 1992). Thus, it makes sense that congenital anomalies can be secondary to genetic anomalies. However genetic anomalies are independent since a deviation can be presented later on in an individual's life.

Secondly, anomalies of the oral cavity and oropharynx can be identified separate from syndromes, which are medically and diagnostically coined when symptoms collectively indicate a disease, disorder, or condition. There are syndromes that have components that are craniofacial anomalies. In contrast, oral cancer arises from several risk factors, such as smoking and alcohol consumption, and is the sixth most common cancer (Neville & Day, 2002). Syndromes and cancers share many similarities with anomalies such as the type of treatments, subsequent care, and results. Nevertheless, the main focus of this paper is craniofacial anomalies and how multidisciplinary care can holistically optimize an individual's health.

Unfortunately, congenital anomalies impose many problems, especially among children (Zalzal & Cotton, 1992). Children dealing with these disorders do not only need a surgeon to correct the problem but also a multidisciplinary team to provide an accurate assessment, a correct diagnosis, and proper management. Many of these patients will immediately or eventually require dental, speech, or psychosocial care (Lindsay, 1976).

Multidisciplinary teams dealing with craniofacial anomalies include a wide range of professionals: otolaryngologists, plastic surgeons, general dentists, prosthodontists, orthodontists, oral surgeons, pediatricians, neurologists, geneticists, social workers, psychologists, audiologists, and speech therapists (Zalzal & Cotton, 1992; Lindsay, 1976). The range of craniofacial anomalies and abnormalities, the possible secondary problems that consequently arise, and proper assessments of such cases will be thoroughly discussed; in addition, based on past studies and data, multidisciplinary treatment of craniofacial anomalies is the optimal way of treatment, maximizing oral and psychosocial health of patients experiencing craniofacial anomalies.

SPECIFIC AIMS

There is agreement among the literature that multidisciplinary treatment of craniofacial anomalies is the best approach and optimizes the oral, mental, and social well-being of the individual. This paper aims to:

1. Explore benign tumors, malignant tumors, and cancers that can exist in the oral cavity and oropharynx; describe features and characteristics of such conditions and state their prevalence among the population.
2. Examine various craniofacial anomalies that can exist in the oral mucosa, gingiva, lips, tongue, maxilla, mandible, floor of the mouth, palate, and teeth; describe features and manifestations of these anomalies.
3. Explain how tumors, cancers, and anomalies of the mouth can cause secondary problems systemically, emotionally, and socially.
4. Elaborate further on the multidisciplinary treatment of craniofacial anomalies and assess studies and published results that have supported these treatments.
5. Describe several craniofacial institutions that exercise these treatment options and highlight certain attributes that should be adopted when treating craniofacial anomalies and other medical provinces.

This study hopes to propose recommendations based on the literature review and published results that will provide insight with regard to future multidisciplinary care and treatment principles.

LITERATURE REVIEW

Oral Tumors and Cancers:

The oral cavity and oropharynx are composed of the oral mucosa, gingiva, lips, tongue, maxilla, mandible, floor of the mouth, palate, and teeth. Abnormalities and some tumors that appear at birth can take place in any of these structures (Lindsay, 1976). A tumor or abnormality of the oral cavity and oropharynx can impose many problems as well as secondary problems involving other parts of the body. A tumor is an abnormal growth of cells that serve no particular purpose. Tumors can be benign or malignant. Unlike malignant tumors, benign tumors do not invade nearby tissues and other areas of the body. Malignant tumors are cancerous and have the potential to metastasize (Neville & Day, 2002). Examples of benign tumors that may exist in the oral cavity and/or oropharynx are the following: hyperplasias (fibroma and pyogenic granuloma), papillomas, pleomorphic adenoma, soft tissue tumors (lymphangioma, hemangioma, neurofibroma, granular cell tumor, and lipoma), and hamartomas (Canadian Cancer Society, n.d.).

Hyperplasias commonly appear in the oral cavity and result from an increase in the number of normal cells, often caused by injury or irritation of the oral cavity (Canadian Cancer Society, n.d.). Papillomas are benign tumors that develop from epithelial cells, which line the inner surface of the oral cavity. Pleomorphic adenomas develop from the minor salivary glands or from the major salivary glands. Soft tissue tumors begin their growth in soft tissues that lie beneath the lining of the mouth, such as

fat and blood vessels (Canadian Cancer Society, n.d.). These tumors include lymphangiomas which take place in lymphatic vessels, hemangiomas in dilated blood vessels (Figure 1), neurofibromas in nerve tissues, granular cell tumors in nerve cells, and lipomas in fatty tissues (Canadian Cancer Society, n.d.; Dilsiz, Aydin, & Gurson, 2009). Hamartomas are non-neoplastic lesions which may be unifocal or multifocal; they are developmental malformations composed of cytological normal mature cells and tissues that are indigenous to the anatomic location (Patil, Rao, & Majumdar, 2015). When hamartomas occur on the tongue, they pose complications; these complications are not only limited to the tongue and will be discussed collectively later (Patil et al., 2015). These benign tumors are often treated by conservative surgical excision, and studies have shown that the prognosis is excellent, with a very small chance of recurrence (Patil et al., 2015).

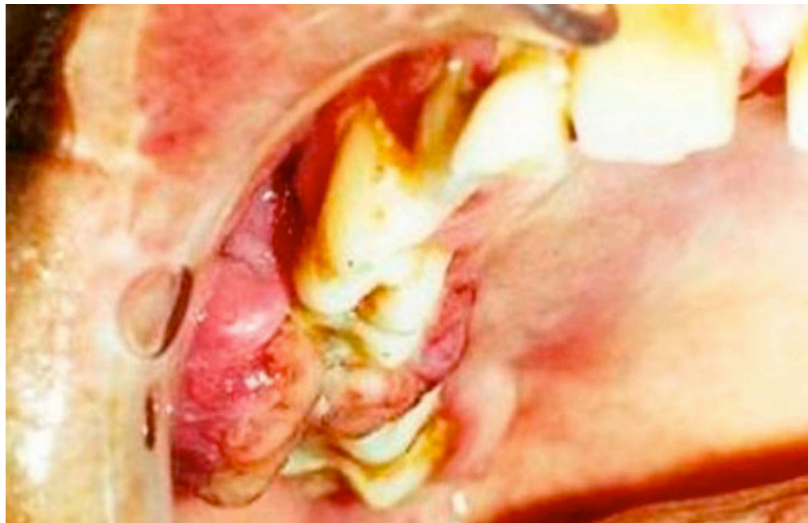

Figure 1: Capillary Hemangioma of the Oral Cavity. This oral tumor is presented as a mass on the buccal surface of the upper right molar region. This mass compromised two molars in this region and caused the development of periodontal pockets. This demonstrates how a tumor in the oral cavity imposes additional problems, especially dental-related ones. Figure is taken from Dilsiz, Aydin, & Gurson (2009).

Furthermore, oral cancer is a serious condition, its treatment is more integrated, and it is more rare compared to other conditions of the oral cavity and oropharynx. Cancer of the oral cavity and oropharynx is about 3% of all malignancies in men and 2% of all malignancies in women (Neville & Day, 2002). Over 90% of these malignant tumors that cause oral cancer are squamous cell carcinomas that arise from the oral mucosal lining. The etiology of oral squamous cell carcinoma is multifactorial and strongly correlated to lifestyle habits such as smoking, alcohol consumption, and diet. There are other biological factors that underlie cases of oral squamous cell carcinoma, but lifestyle choices are significantly stressed in studies. Oral squamous cell carcinoma is mostly seen on the lip or lateral tongue, and its appearance can range from an ulcer to a lump of a white, red, or pinkish color (Neville & Day, 2002).

Oral cancer can be categorized upon its location: carcinoma of the oral cavity proper, carcinoma of the oropharynx, and carcinoma of the lip vermilion (Neville & Day, 2002). Oral cancer is more common among men. However, this distribution is becoming less pronounced since women are becoming more equally exposed to risk factors such as oral carcinogens, like alcohol and tobacco (Chaturvedi, Engels, Pfeiffer, Hernandez, Xiao, Kim, & Liu, 2011). Lip tumors are most strongly associated with chronic sun exposure. The lip is regarded as one of the most common sites of oral cancer, but the prevalence of lip tumors has decreased over time because outdoor occupations are less common (Chaturvedi et al., 2011). Even though advances in treatment, surgery, radiation, and chemotherapy have been developed, the five-year survival rate for oral cancer is unfortunately not improving (Neville & Day, 2002).

Epidemiological studies have shown that the risk of developing cancer is 5-9 times greater for smokers and as much as 17 times greater for extremely heavy smokers (Neville & Day, 2002). Oral cancer patients that are treated and continue to smoke have a 2-6 times greater risk of developing a second malignancy of the upper aero-digestive tract. Marijuana has been shown to be a potential risk factor in studies and partially responsible for oral cancers detected in young adults. Chronic users of snuff and chewing tobacco have a 4 times greater risk of developing oral cancer. Interestingly, use of smokeless tobacco appears to be associated with a much lower cancer risk than that associated with smoked tobacco. Nevertheless, in smokeless tobacco users, there is a significant number of oral cancers which develop at the spot where tobacco is placed. Regarding alcohol, moderate-to-heavy drinkers have a 3-9 times greater risk of developing oral cancer. A study in France has shown that extremely heavy drinkers have a 30 times greater risk of developing cancer in the oral cavity and oropharynx. Jointly, heavy smokers and heavy drinkers can have over 100 times of a greater risk of developing oral malignancies (Neville & Day, 2002).

Strikingly, over 70% of cancers in the oropharynx are caused by human papillomavirus (HPV). HPV is a DNA virus, and there are over 150 types (Chaturvedi et al., 2011). This virus infects the epithelial cells in the skin and/or mucous membranes and spreads by means of sexual contact, skin or mucous membrane contact, and bodily fluids. The prevalence of HPV infection in oropharyngeal tumors increased from the 1980s to 2000s (Chaturvedi et al., 2011). Studies have shown that the increasing incidence of HPV-positive oropharyngeal squamous cell carcinomas probably arises from increased

incidence of oral sex and oral HPV exposure. Other factors that influence cancer risk are dietary habits, such as a low intake of fruits and vegetables (Neville & day, 2002). Iron deficiency anemia, along with dysphagia, are associated with an elevated risk for developing carcinoma in the oral cavity, oropharynx, and esophagus as well (Chaturvedi et al., 2011). Lastly, studies have also shown that immunosuppression appears to predispose individuals to an increased risk for oral cancer (Neville & Day, 2002).

Often, invasive oral squamous cell carcinoma is often preceded by the presence of identifiable pre-malignancies of the oral mucosa (Chaturvedi et al., 2011). More specifically, these lesions are known as leukoplakia and erythroplakia, both of which behold cancerous potential. When the cancer develops, there is the presence of a seemingly non-healing ulcer (Chaturvedi et al., 2011). Later on in the stages of cancer, symptoms that may consequently arise are: bleeding, teeth loosening, difficulty in wearing dentures, dysphagia, dysarthria, odynophagia, and development of a neck mass (Neville & Day, 2002). According to the World Health Organization (WHO), leukoplakia is a white patch or plaque that cannot be characterized clinically or pathologically as any other disease. Therefore, leukoplakia is only used as a clinical term; if an oral white patch can be diagnosed as some other condition, then the lesion should not be diagnosed as leukoplakia. To further verify, biopsy is highly recommended and reveals the specific diagnosis (Neville & Day, 2002).

Leukoplakia is often seen in older men and the prevalence increases to 80% in men over the age of 70 (Villa & Abtahi, 2011). The most common sites where leukoplakia takes place are the buccal mucosa, alveolar mucosa, and lower lip.

Leukoplakia is also specified regarding its appearance, especially regarding texture, color, and appearance. Early or thin leukoplakia appears as gray or white plaque, may be slightly elevated, and may blend into the surrounding normal mucosa, causing its presence to not be easily seen. This lesion often progresses and becomes a thicker white lesion with a leathery appearance and surface fissures. Some leukoplakias can even develop granular or nodular appearances on their surface (Villa & Abtahi, 2011). Some lesions develop a papillary surface and are subsequently labeled as verrucous or verruciform leukoplakia.

In several studies, the frequency of dysplastic or malignant alterations in oral leukoplakia has ranged from 16-40% (Neville & Day, 2002). The location of oral leukoplakia has significant correlation with the frequency of finding dysplastic or malignant changes at the biopsy (Neville & Day, 2002). Based on several studies, evidence shows that the floor of the mouth is of high-risk for malignancies; the tongue and lip also respectively, but more so for the floor of the mouth. Generally, clinical findings and studies have shown that the thicker the leukoplakia, the greater the chance of malignancies (Figure 2). Some leukoplakias occur in combination with red patches or erythroplakia – this is called speckled leukoplakia or erythroplakia. Leukoplakias with this intermixed red component are at the greatest risk for showing dysplasia or carcinoma. Lastly, leukoplakias that do not demonstrate findings of carcinoma initially are at risk for future malignant transformations; several studies have shown rates of malignant transformation ranging from 9-18% (Neville & Day, 2002).

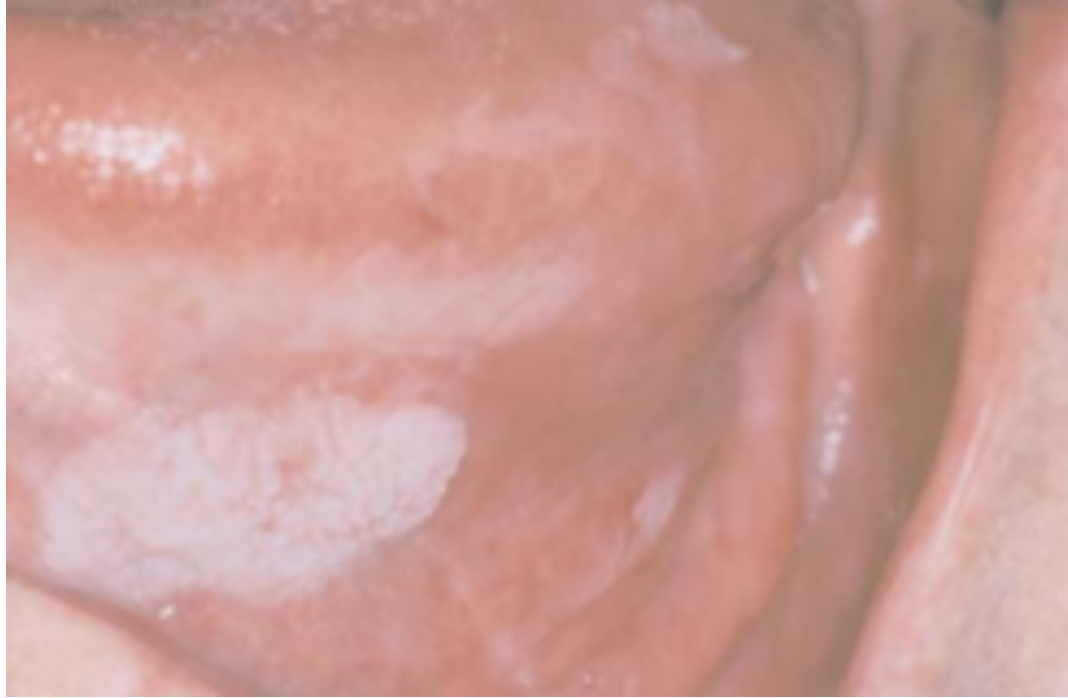

Figure 2: Thick Leukoplakia. The white lesion on the lateral and ventral surface of the tongue demonstrates moderate epithelial malignancy or dysplasia. The thickness and elevation of this leukoplakia demonstrates its evolution into cancer. Figure is taken from Neville & Day (2002).

Erythroplakia is a clinical term used to describe a red, precancerous lesion on the oral mucosa (Villa & Abtahi, 2011). This term refers to a red patch and is similar to leukoplakia in that it cannot be defined clinically or pathologically as any other condition. Therefore, comparable inflammatory conditions are excluded (Neville & Day, 2002). It occurs most frequently in older men, consisting of an appearance of a red macule or soft plaque of velvety texture. The floor of the mouth, lateral tongue, retromolar pad, and soft palate are the most common sites of involvement (Figure 3). Sometimes erythroplakia is

gradually blended into the surrounding mucosa (Neville & Day, 2002). Also, some lesions may be intermixed as well with white lesions. Erythroplakia is asymptomatic and not as common as leukoplakia, but much more likely to show malignancy or carcinoma (Villa & Abtahi, 2011). In a similar study of that conducted regarding leukoplakia, all of the erythroplakia cases show some degree of epithelial malignancy (Neville & Day, 2002). Therefore, erythroplakia, although not as commonly seen, is a worrisome lesion (Villa & Abtahi, 2011).

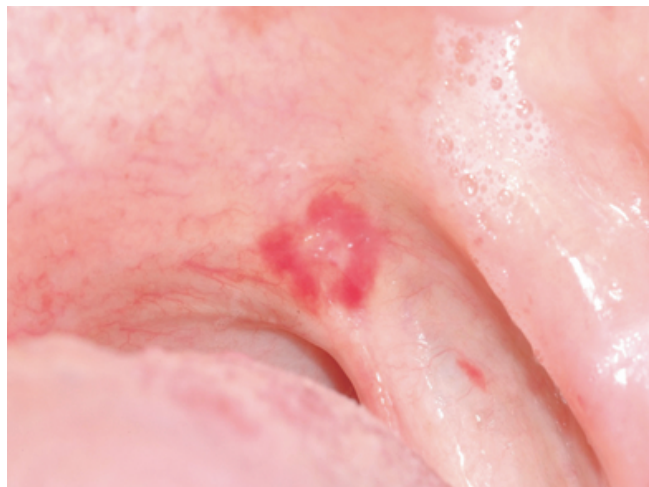

Figure 3: Erythroplakia of the Soft Palate. Erythroplakia is any lesion of the oral mucosa that presents a bright, red, velvety plaque and is not characterized as any other recognizable condition. It can be flat, depressed, or intermixed with leukoplakia. Figure is taken from Villa & Abati (2011).

Early in the stages of squamous cell carcinoma, there are often white patches (leukoplakia), red patches (erythroplakia), and or an intermixed lesion (erythroplakia). Over time, the superficial ulcer of the mucosa can develop and the lesion grows, becoming an exophytic mass with a papillary surface (Villa & Abati, 2011). Similar to leukoplakia and erythroplakia just discussed, many oral cancers will be asymptomatic or

the patient with oral cancer may possibly experience some mild discomfort. The most common sites for intraoral carcinoma is the tongue, accounting for 40% of oral cancer cases. The tumors usually occur on the posterior lateral border and ventral surfaces of the tongue. The second most common oral site for cancer is the floor of the mouth (Neville & Day, 2002).

It has been stated that the lateral tongue and floor of the oral cavity is the greatest risk for cancer development because carcinogens will mix with saliva, pool on the bottom of the mouth, and continuously bathe these sites. Also, the floor of the mouth and tongue are covered by thinner, non-keratinized mucosae, which provide less protection against carcinogens (Figure 4) (Neville & Day, 2002). Squamous cell carcinomas also develop on the lip vermilion and oropharynx. Vermilion carcinomas usually arise from a lesion in actinic cheilosis, which is a premalignant condition that is akin to actinic keratosis of the skin. Atrophy of the vermilion border is commonly seen, and if the condition progresses, ulcerated sites may appear. This evolving cancer becomes a crusted, nontender, indurated ulcer (Neville & Day, 2002).

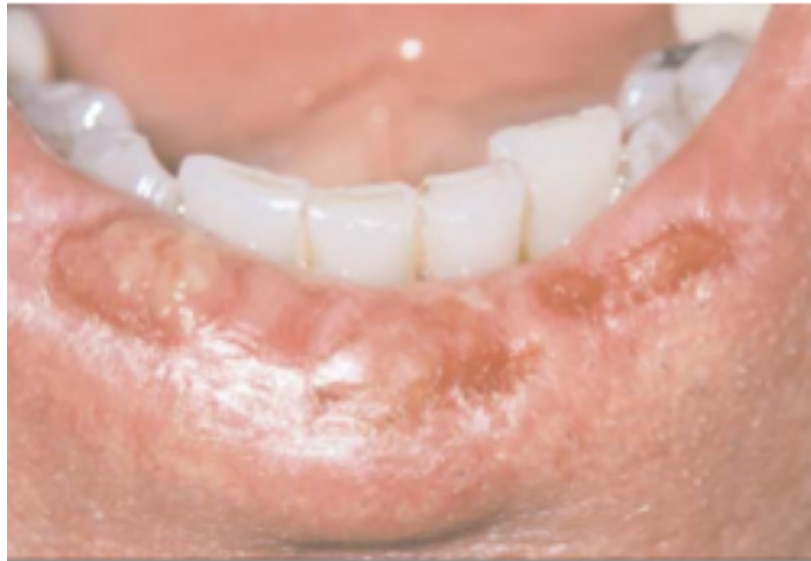
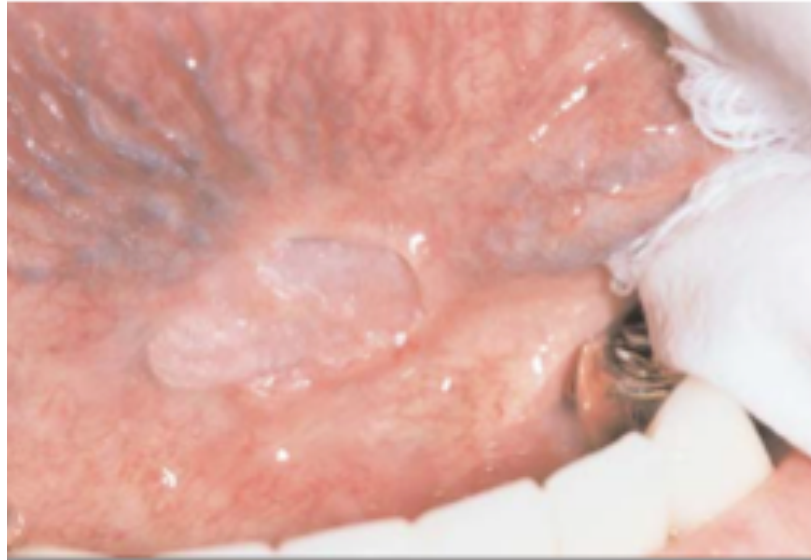
Figure 4: Oral Squamous Cell Carcinoma. This demonstrates squamous cell carcinoma in two common sites of occurrence: ventral tongue and floor of mouth (above), and lip vermilion (below). The above picture depicts an ulcerated lesion and the below picture is actinic cheilosis, resulting in atrophic and ulcerated changes of the lower lip vermilion. Biopsy of actinic cheilosis concluded that the condition is of invasive squamous cell carcinoma. Figure is taken from Neville & Day (2002).

Craniofacial Anomalies:

The oral mucosa, as earlier discussed, is the mucous membrane that lines the inside of the mouth. It consists of stratified squamous epithelium and lamina propria, which is an underlying connective tissue (Zalzal & Cotton, 1992). The oral mucosa, as seen in the tumor and cancer review, can be an indicator of disease and/or deficiency in an individual. There are several abnormalities and anomalies that manifest in the oral mucosa. Witkop's disease is a lesion manifested by cream-colored plaque that involves the tongue and floor of the mouth. It is an asymptomatic and benign disease. Hereditary mucoepithelial dysplasia is a red, flat micropapillary lesion that is usually found on the palate and gingiva (Zalzal & Cotton, 1992). White sponge nevus, a genetically linked anomaly, consists of white-spongy plaques which are asymptomatic. Fordyce granules are atopic sebaceous glands and are manifested as small, flat or slightly elevated, yellow and brown spots that are either singular or occur in groups in the buccal mucosa and labial mucosa (Figure 5) (Chiang, Hsieh, & Tseng, 2014).

The labial mucosa is a more common site for the granules. They are more common in adults than in children, and studies have shown that this anomaly is one of the most commonly seen ones in dental practices (Chiang et al., 2014). When detected in children under 18 years, the most common site of Fordyce granules was the buccal mucosa at the mouth angles (Chiang et al., 2014). Leukoedema consists of gray or white colored folds in the buccal mucosa which disappear when the mucosa is stretched. Studies have shown that this mucosal anomaly is five times more likely to occur in black infants than in white infants (Friend, Harris, Mincer, Fong, & Carruth, 1990).

Palatal cysts take on the appearance of white nodules at the junction of the hard and soft palate. Most of the lesions are found on the hard-soft palate junction, but studies have shown that cysts can exist adjacent to the midpalatal raphe or in the median raphe of the hard palate. Additionally, a palatal cyst is 2.5 times more common in white infants than in black infants (Friend et al., 1990). The maxilla and mandible are of great importance cosmetically, functionally, and structurally. Therefore, anomalies that exist in these locations cause devastating abnormalities (Friend et al., 1990). Anomalies of the maxilla and mandible are known to cause severe upper airway obstruction and consequently life-threatening issues.

Cherubism, which can start early in childhood, is a painless, hard, symmetric enlargement of the mandible. Using radiographic measures, multilocular lesions can be detected. Exostoses of the maxilla and mandible exist, which are benign and cartilaginous outgrowths of tissue on these bones. Buccal exostoses are more prevalent in males than in females and are more commonly symmetric than asymmetric (Figure 5) (Chiang et al., 2014). Torus palatinus, an anomaly that occurs more frequently in women (Figure 5) (Chiang et al., 2014), is a bony exostosis along the suture line of the hard palate, which can be flat, spindle, nodular, or lobular. Torus mandibularis is a unilateral or bilateral exostosis on the lingual aspect of the mandible in the region of the premolars. Tori can be either single or multiple (Zalzal & Cotton, 1992; Lindsay, 1976). The mean age of torus mandibularis and palatinus is around 40 years old (Chiang et al., 2014).

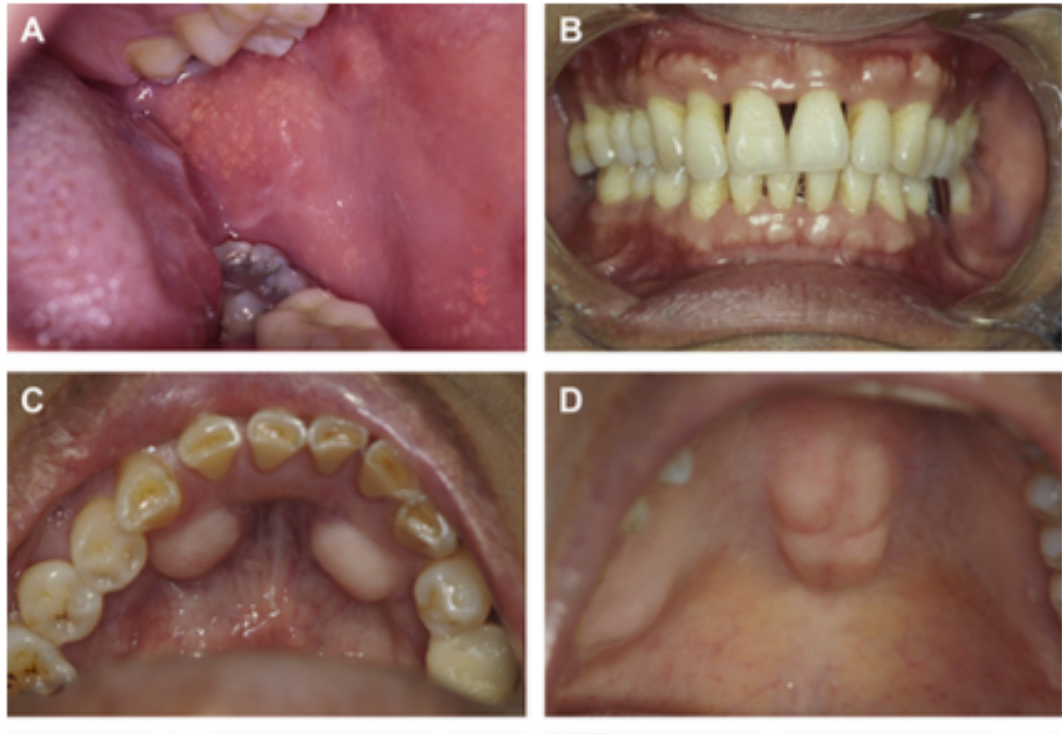

Figure 5: Oral Mucosal Lesions: This figure demonstrate some of the oral mucosal lesions discussed such as Fordyce granules (A), exostoses at the labial and buccal plate of alveolar bone (B), Torus mandibularis (C), and Torus palatinus (D). Figure is taken from Chiang, Hsieh, & Tseng (2014).

Gums, clinically known as gingiva, and teeth may be involved in several anomalies as well. Gingiva is made of mucosal tissue, covering and sealing the alveolar processes of the maxilla and mandible, finishing at the neck of each tooth (Friend et al., 1990). Gingival fibromatosis, usually genetically linked, is a firm, painless, and pink enlargement of the gums, which slowly progresses but is nonhemorrhagic. It is further characterized by its presentation of firm nodular enlargements with pink to red inflamed but smooth surfaces; sometimes, the gingiva may be very firm to the point where it feels like bone on palpation, (Figure 6) (Katz, Guelman, & Barak, 2002). Studies have shown that gingival fibromatosis can also be caused by inflammation, leukemic infiltration, and

use of medications like phenytoin, cyclosporine, and vigabatrin. Gingival fibromatosis can be either unilateral or bilateral and either generalized or localized (Friend et al., 1990). Furthermore, studies have shown gingival fibromatosis may be associated with hearing loss, cherubism, and psychomotor retardation; the idea of secondary systemic problems arising will be further elaborated later on (Katz et al., 2002).

Mucopolysaccharidosis II, also known as inclusion disease, is a gingival enlargement that can possibly affect mouth closure. This disease is associated with a delay in the eruption of teeth due to the possibility of inclusion in hypertrophic gingival tissue (Friend et al., 1990). Congenital epulis, a rare gingival anomaly, is usually located in the anterior region of the maxilla and is a firm, non-tender mass covered with pink-colored smooth mucosa. Teeth anomalies mostly consist of abnormalities in morphology and structure. Some teeth anomalies are: atypical teeth count and eruption time, widely-spaced teeth, anterior teeth that are flared, tapered posterior teeth with pointed cusp tips, enamel and dentin hypoplasia, hypocalcified and hypomature enamel defects, dentinogenesis imperfecta, anodontia, hyperdontia, and more (Friend et al., 1990).

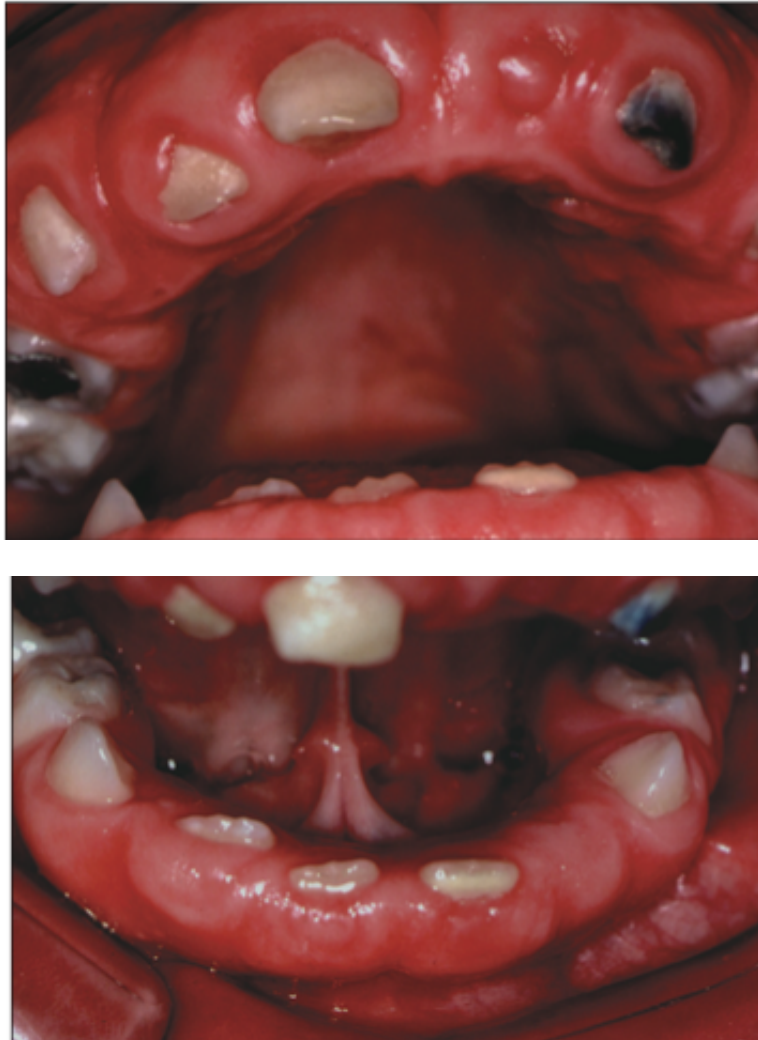


Figure 6: Hereditary Gingival Fibromatosis. This is a picture of a 9 year-old boy with gingival fibromatosis. His gums are greatly inflamed, affecting the eruption of his teeth. Top shows the upper anterior region with severe inflammation and bottom shows the lower anterior region. Figure is taken from Katz, Guelman, & Barak (2002).

There are a few anomalies of the lips that exist as well. Lip nodules are genetically linked and painless; these yellow nodules may be found intramucosally over the lower lip, palate, and tonsillar areas. Commissural lip pits, also genetically linked, are 1- 4 mm deep depressions at the corners of the mouth (Friend et al., 1990). A lip frenulum is a fibrous band, which connects the upper or lower lip in the midline to the back of the gingiva. If the frenulum is thick, partial lip immobility may result. Alveolar cysts are gray or white nodules that commonly exist along the crest of the alveolar mucosa and to a lesser extent on the lingual or facial borders. This anomaly has a higher occurrence in whites than in blacks (Friend et al., 1990).

There is a wide array of tongue anomalies and abnormalities that are summarized in Table 1. Abnormal development of the tongue or failure of development of structures in the oropharynx region, such as the thyroid, can cause tongue anomalies (Reamy, Derby, & Bunt, 2010). The thickening and enlargement of the side of the tongue is known as tongue asymmetry, and this is noted at birth because infants with this anomaly are likely to have feeding problems. Bifid tongue results from failure of the lateral tubercle of the tongue to fuse at the midline, resulting in a median cleft of the tongue (Reamy et al., 2010). Fissured tongue is a benign condition where the top surface of the tongue has grooves in it of varying length, mostly fissured in the middle of the tongue. This malformation is congenital, but it can also be acquired (Figure 7) (Reamy et al., 2010).

Table 1: Summary of Tongue Anomalies and Abnormalities

Table amended from Reamy, Derby, & Bunt, 2010

<i>Condition</i>	<i>Clinical presentation</i>	<i>Treatment</i>	<i>Comments</i>
Median rhomboid glossitis	Smooth, shiny, erythematous, sharply circumscribed, rhomboid shaped plaque; usually asymptomatic, but burning or itching possible; dorsal midline location	Topical antifungals	Often associated with candidal infection
Atrophic glossitis	Smooth, glossy appearance with red or pink background	Treat nutritional deficiency or other underlying condition	Caused by underlying disease, medication use, or nutritional deficiencies (e.g., iron, folic acid, vitamin B ₁₂ , riboflavin, niacin)
Fissured tongue	Deep grooves, malodor and discoloration may occur with inflammation or trapping of food	Usually no treatment; gentle brushing of tongue if symptomatic inflammation occurs	Associated with Down syndrome, psoriasis, Sjögren syndrome, Melkersson-Rosenthal syndrome, geographic tongue
Geographic tongue	Bare patches on dorsal tongue surrounded by serpiginous, raised, slightly discolored border	No treatment necessary, but topical steroid gels or antihistamine rinses can reduce tongue sensitivity	Associated with fissured tongue, inversely associated with tobacco use
Hairy tongue	Hypertrophy of filiform papillae, tongue discoloration (white, tan, black)	No treatment necessary, but gentle brushing or scraping of tongue may be helpful	Associated with tobacco use, poor oral hygiene, antibiotic use
Oral hairy leukoplakia	White, hairy appearing lesions on lateral border of tongue	Antiviral medications	Epstein-Barr virus super infection; associated with immunocompromise, human immunodeficiency virus infection
Lichen planus	Manifests as reticular, white, lacy pattern on dorsal tongue or as shallow, scattered, erythematous ulcerations	No treatment if asymptomatic, topical steroid for symptomatic ulcerative lesions	Consider evaluation and treatment for coexisting candidal infection; biopsy needed for definitive diagnosis of lichen planus
Linea alba	Thin white line of thickened epithelium on lateral borders of tongue	No treatment necessary	Caused by chewing trauma to lateral tongue
Leukoplakia	White adherent patch or plaque	Close observation, biopsy to rule out malignancy	Strongly associated with tobacco use, but higher malignant potential when occurring in never smokers
Squamous cell carcinoma	Thickened white or red patch or plaque, may develop nodularity or ulceration, usually on lateral tongue	Surgical excision, radiation	Associated with tobacco use, alcohol use, older age
Papilloma	Single, isolated pedunculated lesion with finger-like projections	Surgical excision or laser ablation	Associated with human papillomavirus type 6 or 11 infection
Burning tongue	Daily pain that worsens throughout the day, tongue has normal appearance	Alpha-lipoic acid, clonazepam (Klonopin), cognitive behavior therapy; treatment of any underlying condition	Underlying systemic or local disorders (e.g., nutritional deficiency, endocrine, hyposalivation, infection, allergic reaction) should be excluded
Tongue-tie (ankyloglossia)	Shortened frenulum limiting tongue protrusion, breastfeeding difficulties	Surgical division in infants having difficulty breastfeeding	Associated with poor breastfeeding, including nipple pain
Macroglossia	Enlarged tongue with scalloping of lateral margin	Treat underlying condition	Associated with various underlying conditions

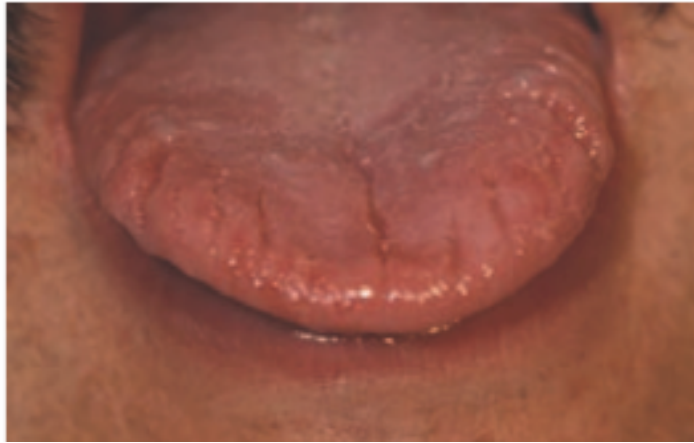

Figure 7: Fissured tongue: This figure depicts the tongue anomaly, fissured tongue, and shows the grooves associated with it. Figure is taken from Reamy, Derby, & Bunt (2010).

Median rhomboid glossitis consists of a red area that takes place in the middle of the tongue and the area is devoid of papillae (Zalzal & Cotton, 1992; Lindsay, 1976).

Ankyloglossia, also known as tongue-tie, is characterized by the presence of the lingual frenulum. The lingual frenulum can vary in presentation from a mucous membrane band to a short or thick band to fusion of the tongue to the floor of the mouth. Studies have demonstrated statistical significance of ankyloglossia with respect to gender: males exhibit a higher incidence of this anomaly (Friend et al., 1990). Another tongue anomaly is geographic tongue. Also known as benign migratory glossitis, geographic tongue affects 1-14% of the U.S. population and has a higher prevalence among whites (Reamy et al., 2010). It has a sharply defined demarcation of inflammation, and the dorsal tongue develops areas of papillary atrophy. Regions of atrophy spontaneously resolve and migrate. Hairy tongue results from an accumulation of excess keratin on the filiform papillae of the dorsal tongue, leading to the formation of elongated strands that resemble hair. Hairy tongue's color can grow darker from trapping debris and bacteria in the

elongated strands; this is common among people who smoke and/or have poor oral hygiene. This abnormality is asymptomatic and can be treated with antibiotic medications and gentle, daily debridement with a toothbrush or tongue scraper in order to remove keratinized tissue (Reamy et al., 2010).

Lingual thyroid is a rare, developmental anomaly that originates from abnormal embryogenesis when the thyroid gland passes through the neck (Toso, Colombani, Averno, Aluffi, & Pia, 2009). The thyroglossal duct is a narrow tube connecting the developing thyroid gland to the tongue. The foramen caecum is the opening of the thyroglossal duct in the tongue, and the thyroid gland descends to the lateral ultimobranchial bodies. All in all, the fusion of these elements results in a mature and functional thyroid gland (Toso et al., 2009). The lingual thyroid is the most frequent ectopic location of the thyroid gland; ectopic thyroid denotes the presence of thyroid tissue in locations other than the normal anterior neck region (Akamnu & Olusegun, 2011). Signs and symptoms of lingual thyroid are dysphagia, dyspnea, and dysphonia (Zalzal & Cotton, 1992). Burning Mouth Syndrome is a chronic condition that is characterized by a burning sensation of the mucosa, lips, and especially tongue (Reamy et al., 2010). Studies demonstrates that 60% of the patients with Burning Mouth Syndrome (BMS) were 45 year or older. Commonly associated symptoms are burning tongue, xerostomia, and dry eyes. Frequent systemic diseases associated with BMS are rheumatoid arthritis, diabetes mellitus, and hypothyroidism (Chiang et al., 2014).

There are many anomalies that involve structures and features of the oral cavity and oropharynx. Among the many described, cleft lip and palate, along with accompanying deformities are domains extensively reviewed, stressed, and treated in the medical, dental, and scientific realm. The palate mainly serves as the roof of the mouth and it separates the oral cavity from the nasal cavity. There are two portions of the palate: hard and soft (Tewfik, 2015). The hard palate is the anterior portion that is bony and immovable. The palatine processes of the maxillae fuse together in the midline and with palatine bones horizontally. The soft palate, which is the posterior portion, consists of muscles that are flexible, and is suspended between the oral and nasal pharynx. The soft palate can be elevated to isolate the oral cavity from the nasal pharynx during swallowing (Tewfik, 2015).

The muscles that are associated with the soft palate and their functions are: tensor veli palatini (tenses the soft palate), levator veli palatini (elevates the soft palate and most important for velopharyngeal competence), palatopharyngeus (elevates the larynx), palatoglossus (elevates the base of the tongue), and musculus uvulae (elevates and retracts the uvula). Cleft lip (CL) is caused by the partial or complete failure of fusion of the maxillary and nasal segments (Tewfik, 2015; Kos, 2004). CL can be categorized by being either: unilateral incomplete, unilateral complete, and bilateral complete. This anomaly is more common among boys. Cleft palate (CP) is the failure of either fusion between the maxilla or the fusion between maxilla and palatine bones. This anomaly is more common among girls (Tewfik, 2015; Kos, 2004). Cleft palate can be categorized as unilateral, bilateral, or isolated (Figure 8). Isolate cleft palate is carefully examined in

order to detect if there are manifestation of the Pierre Robin sequence (Hopper, Cutting, & Grayson, 2007). The etiopathogenesis of the cleft palate in the Pierre Robin sequence is thought to be obstruction of the palatal shelves as they swing from a vertical to horizontal orientation during palate fusion. Patients with cleft lip and/or cleft palate are divided into CL, CP, or CLP (Hopper et al., 2007).

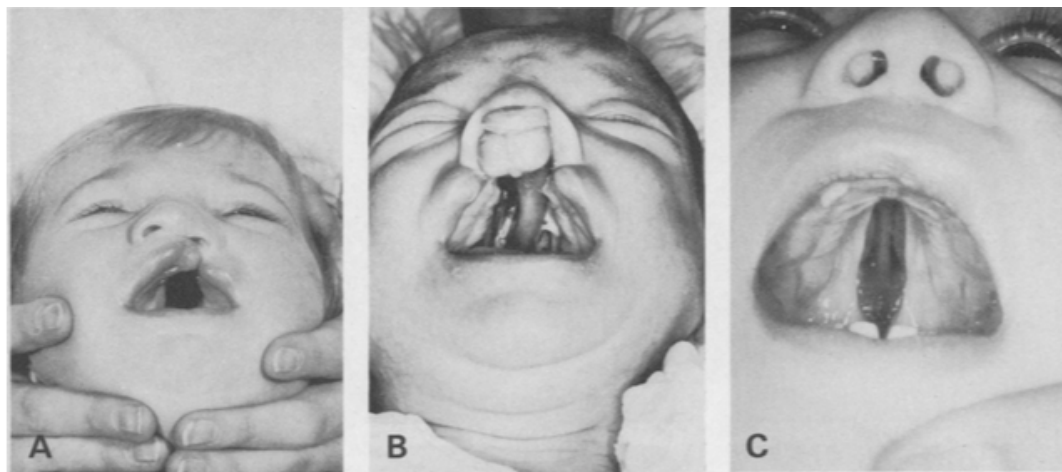


Figure 8: Types of Cleft Palate: This figure demonstrates the types of cleft palate which are unilateral cleft palate (A), bilateral cleft palate (B), and on the isolated cleft palate (C) Figure is taken from Lindsay (1976).

The most common diagnosis is cleft lip and palate (46%), followed by isolated cleft palate (33%), and isolated cleft lip (21%). The majority of bilateral cleft lips and unilateral cleft lips are associated with a cleft palate (Hopper et al., 2007). Unilateral clefts are 9 times more common than bilateral clefts and are 2 times more frequent on the left side. Males are more commonly affected by cleft lip and palate, whereas females are more commonly affected by isolated cleft palate. Cleft is influenced by genetic factors as

well; genetic abnormalities can result in syndromes that include cleft as well. Studies have shown that more than 40% of isolated cleft palates are part of the malformation syndromes; the van der Woude syndrome is the most common syndrome that is associated with cleft lip and palate (Hopper et al., 2007). The risk of parents with a child having cleft and subsequent pregnancies depends on the status of the proband: CL, CLP, or CP. If one affected child or parent has CLP, the risk of having another child with CLP is 4%. If two children have CLP, the risk of another child having CLP is 9%. If one child and one parent are affected with CLP, the risk of having another child with CLP is 17% (Hopper et al., 2007).

Microform cleft lip is characterized by a scar transgressing the vertical length of the lip, a vermilion notch, and varying degrees of vertical lip shortness. Nasal deformity may also take place (Hopper et al., 2007). Unilateral incomplete cleft lip has varying degrees of vertical separation of the lip but has an intact nasal sill, also known as Simonart band. Unilateral complete cleft lip has a very visible disruption of lip, nostril sill, and complete primary plate. There is no nasal sill connecting the alar base to the footplates of the lower lateral cartilages of the nose. Therefore, abnormal attachments of the orbicularis oris muscles (muscle in the lip that encircles the mouth) cause the lower lateral cartilage framework to collapse and more nasal deformity. Complete bilateral cleft lip is characterized by a protruding maxilla; there is a lack of connection of the premaxilla with the lateral palatal shelves. Incomplete bilateral cleft lip is characterized by a normal nose, normally positioned premaxilla, nasal sill across the nasal floors, and

clefts involving only the lip (Hopper et al., 2007). Figure 9 depicts each one of these cleft lips.

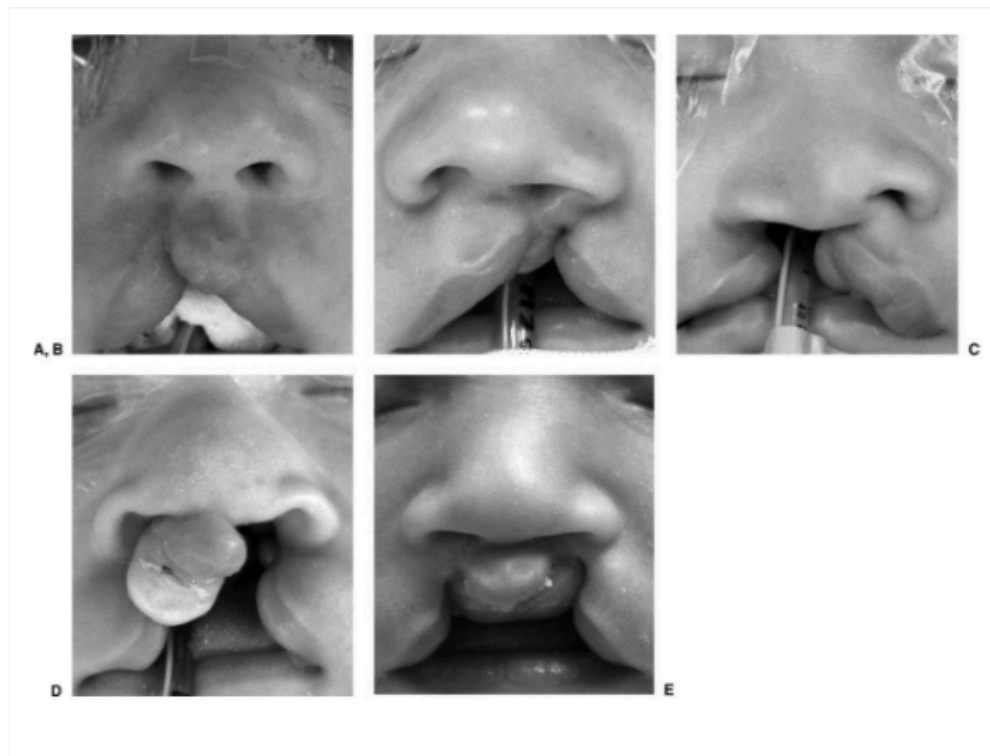


Figure 9: Types of Cleft Lips. There are several ways to classify cleft lips. The first row of pictures demonstrates microform cleft lip (left), unilateral incomplete cleft lip (middle), unilateral complete cleft lip (right). The second row shows: complete bilateral cleft lip (left) and incomplete bilateral cleft lip (right). This figure is taken from Hopper, Cutting, & Grayson (2007).

Secondary Problems:

Craniofacial abnormalities, as well as tumors and cancer, almost always impose others issues or acute problems. In addition, if one has a congenital anomaly, there is a greater than average chance of having a second anomaly (Lindsay, 1976). Many of these

accompanying problems involve the airway, sucking and swallowing issues, risk of aspiration, speech deficits, and psychosocial disturbances (Lindsay, 1976). Distal areas may be involved in secondary problems as well, such as the myocardium (Lindsay, 1976). Secondarily, parents impose a greater weight on the issue; they are concerned about the cause of the condition and why it happened to their child, and they internalize the issue, concerned that the problem was due to something they had done wrong (Pilemer & Cook, 1989).

Among these problems, many who suffer from oral abnormalities are at higher risks of having speech problems. Therefore, a speech-language pathologist must perform an adequate speech assessment, highlighting how a multidisciplinary approach is necessary for optimal treatment and results. An important and widely studied example is velopharyngeal insufficiency (VPI) (Johns, Rohrich, & Awada, 2003). Patients with VPI most commonly are affected by cleft palate and are expected to have speech problems. After the speech therapist adequately assesses such an anomaly, a mandatory examination prior to treatment must be done with a flexible nasopharyngoscope and documentation via videotaping and multi-view videofluoroscopic speech studies (Johns, Rohrich, & Awada, 2003).

VPI occurs when the velum, lateral, and posterior pharyngeal walls fail to separate the oral cavity from the nasal cavity during speech and deglutition. Velopharyngeal (VP) closure refers to the normal apposition of the soft palate, or velum, with the posterior and lateral pharyngeal walls. The upward and backward movement of the velum, coupled with mesial movement of the lateral pharyngeal walls and semi-

movement of the anterior part of the posterior pharyngeal walls, separates the oral and nasal cavities during deglutition and speech (Johns, Rohrich, & Awada, 2003). The etiology of VPI consists of structural deficits, neurogenic impairment, and mechanical interference to VP closure. The functional goals of cleft palate surgery are to facilitate hearing and normal speech without interfering with a child's facial growth. Nonetheless, there is a 20% chance that primary palatoplasty can result with patients having unsatisfactory speech results, requiring secondary management because of insufficient VP closure (Johns, Rohrich, & Awada, 2003).

Airway obstruction can be secondary to oral anomalies as well. Macroglossia, enlargement of the tongue, can result in secondary airway obstruction. Airway obstruction, especially that in the upper airway, can be life threatening and dangerous to the cardiac as well as pulmonary status (Zalzal & Cotton, 1992). Airway obstruction must be vigorously treated along with treatment of the anomaly in order to achieve optimal health results for the diagnosed patient. Congenital lingual cysts, which are rare congenital tumors of the oropharynx that cause a massive appearance of the tongue in infants, have been reported to cause respiratory distress as well (Zalzal & Cotton, 1992). Craniofacial dystosis, from Apert-Crouzon syndrome, has been suspected to reduce the size of the nasopharyngeal airway, causing cor pulmonale, which is enlargement of the right side of the heart due to compromised pulmonary status (Zalzal & Cotton, 1992). Feeding problems, especially among neonates, is not a common problem. However, if encountered, it is more of a nuisance. Scenarios that may be encountered are weak sucking ability, poorly coordinated swallowing, and aspiration, which is when food,

liquid, and possibly other substances are breathed into the airways. Neonates with cleft lip or palate are at a higher risk of experiencing this secondary problem (Lindsay, 1976).

Ear disease can also be secondary to anomalies in the oral cavity and oropharynx, mainly in the Eustachian tube, which connects the nasopharynx to the middle ear. The abnormalities that cause secondary ear disease usually take place in Eustachian tube formation. In most cases, such abnormalities are caused by the mispositioning of the Eustachian tube and inadequate function of the tensor veli palatini and levator palatini muscles (Lindsay, 1976). Additionally, children experiencing craniofacial anomalies have effusion problems with otitis media. Treatment of such anomalies must be treated carefully along with their secondary diseases and complications; monitoring the ear's function and assessment for recurrent ear infections must be done in order to avoid chronic complications, such as hearing loss. (Zalzal & Cotton, 1992).

As extensively assumed by professionals and greatly demonstrated in literature, a variety of dental-related cases exist along with craniofacial anomalies and abnormalities. Poor dental occlusion can be associated with severe temporomandibular joint problems. Poor oral hygiene, mostly ensued from neglect, usually exists with children experiencing craniofacial anomalies, causing even more problems (Lindsay, 1976). All in all, a dental team is mandatory in managing such cases. Other secondary problems that may arise are those seen in maxilla and mandible anomalies. A short, soft palate can cause velopharyngeal insufficiency and poor speech (Rutrick, Black, & Juriewicz, 1984). Maxillary cysts and embryologic fusion lines can possibly predispose to infection and erosion of the surrounding maxillary bone. Ankyloglossia has several subsequent effects

such as speech defects, sucking restrictions, dental deformities, open bite, and prognathism.

PRESENTATION OF PUBLISHED RESULTS

Regardless of the craniofacial anomaly anticipated or identified in a patient, essential criteria for proper assessment must be implemented. Minimally, assessment should include a thorough physical examination, a detailed family history, radiologic studies of the skull and face, and chromosomal studies (Zalzal & Cotton, 1992). Many oral malformations can produce urgent and secondary problems, requiring crucial neonatal management by the physician as well as counseling and support for the distraught parents (Lindsay, 1976). The presence of oral lesions and craniofacial developmental anomalies are common reasons of why patients visit dental clinics (Chiang et al., 2014). Therefore, it is very important that dental practitioners have the knowledge of the type of oral lesions and anomalies that may be present and the prevalence of such cases as well (Chiang et al., 2014). Finally, the explained anomalies, abnormalities, and secondary problems that arise significantly demonstrate the need of multidisciplinary treatment. Several studies stressed the importance of the following specific disciplines: psychologists, orthodontists, speech and language pathologists, and geneticists.

The common key to correcting these craniofacial anomalies and resulting problems is the participation of a multidisciplinary team (Lindsay, 1976). Multidisciplinary care is essential for completing and continuing care of patients experiencing craniofacial anomalies (American Speech-Language-Hearing Association (ASHA), n.d.). Among the essential members of the multidisciplinary group that treat patients with craniofacial anomalies, speech-language pathologists (SLPs) are

fundamental members. SLPs are professionals that engage in the practice in areas of communication and swallowing, optimizing an individual's ability in these domains, and consequently improving one's quality of life. Communication includes speech, production, fluency, language, cognition, voice, resonance, and hearing (ASHA, n.d.).

Swallowing consists of components of feeding behaviors as well. SLPs work with professional practice and service delivery domains. Each domain varies based on the individual, and the SLPs cater to one's needs. Among the service delivery domains, assessment and treatment are essential in optimal treatment for individuals with craniofacial anomalies (ASHA, n.d.). Communication, speech language, and swallowing disorders can occur developmentally, as part of a medical condition, or with an underlying conditions; SLPs use their expertise in diagnosing and treating the swallowing and communicating aspects, regardless if the condition is a social, psychological, oral anomaly-related, or developmental condition. Potential etiologies of communication and swallowing include oral anomalies, respiratory compromises, pharyngeal anomalies, and laryngeal anomalies (ASHA, n.d.).

Additionally, the importance of psychosocial care to the patient and parents of the patient is crucial and often underestimated. Children experiencing a craniofacial anomaly, such as cleft lip or palate or an abnormality of the tongue, are likely to experience speech problems. Consequently, communication among their peers and family may also be hindered as well (Pilemer & Cook, 1989). Parents may be in a state of shock, guilt, or panic because of their child's situation, causing the parents to need psychosocial care as well (Pilemer & Cook, 1989). Because the surgeon, dentist, or SLP is aware of the

communication disadvantage a child may be experiencing, they have the expertise to recommend counseling or discuss the situation with a psychologist or social worker , provided the privacy and confidential principles of the matter are endorsed. The psychologist and/or social worker can help the patient have better thoughts and approach social settings better and help the parents deal with their concerns (Pilemer & Cook, 1989). Cooperatively, these professionals demonstrate how multidisciplinary treatment can optimize a patient's mental health and speaking abilities, and, as a result, can improve a patient's life.

Additionally, SLPs, psychologist, and social workers are not the only members of the multidisciplinary team that optimize treatment. Cleft lip, cleft palate, and VPI are corrected via invasive surgery (Johns et al., 2003). Nonetheless, to optimize the surgical process as well as the results of the surgery, other professional domains can intervene before or after operation, and studies have shown improved and more successful processes and outcomes. Dental treatment, particularly orthodontics, have greatly facilitated cleft lip repair. Pre-surgical orthodontic treatment facilitates repositioning of the palatal segments in normal alignment (Rutrick et al., 1984). Orthodontic appliances, such as adhesive tape, placed across the cheeks and pro-labium of bilateral clefts have greatly eased operative care (Rutrick et al., 1984).

Orthodontic appliances have the ability to convert wide, complete cleft lip to an incomplete lip. These pre-operative measures have shown to decrease tension on the wound and decrease incidence of wound dehiscence. Similarly, for bilateral cleft lip repair, orthodontics has also shown to help realign the maxillary arch and pre-maxilla and

to minimize the tension placed on the lip closure (Rutrick et al., 1984). Cohesively, in addition to the surgical correction of cleft lip, orthodontic treatment has shown to maximize the results, better the health and situation of the patient, and convey how multidisciplinary treatment is the optimal approach in correcting craniofacial anomalies (Rutrick et al., 1984).

According to Dr. Pahl-Andersen, orthodontic appliances have helped in the process of multidisciplinary care for children with cleft palate as well. Children with a cleft anomaly differ in facial morphology and dentition from normal, noncleft children (2000). Evidence shows that if early orthodontic plates are used, the lower incisors emerge earlier than the normal rate at which they emerge for patients with cleft palate. Many multidisciplinary teams use preoperative orthodontics during the first two phases of treatment. This study evaluated and concluded that acrylic plates are used to actively or passively diminish the cleft too (Figure 10). This process is accomplished by grinding the plates selectively at the cleft margins (Pahl-Andersen, 2000). Passive plates are grounded in order to allow spontaneous improvement of the displacement of maxillary parts where active plates are made on reconstructed models.

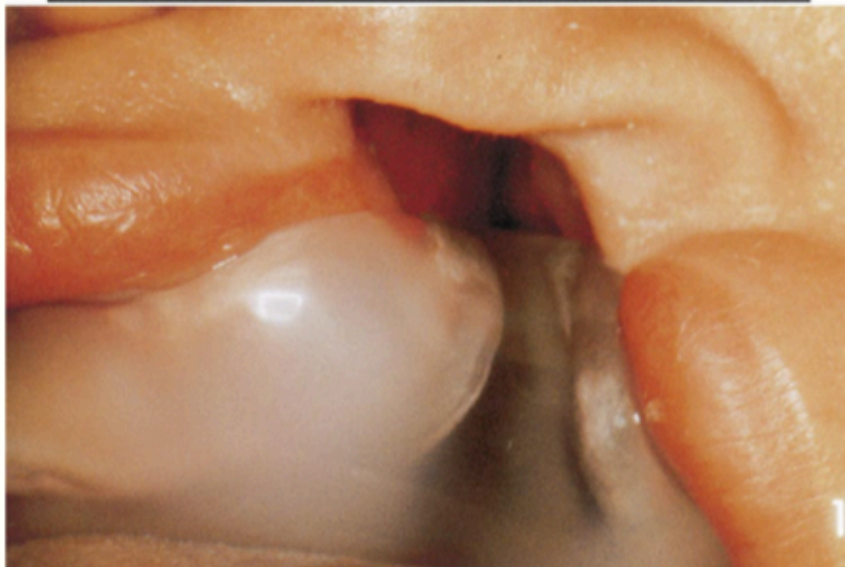
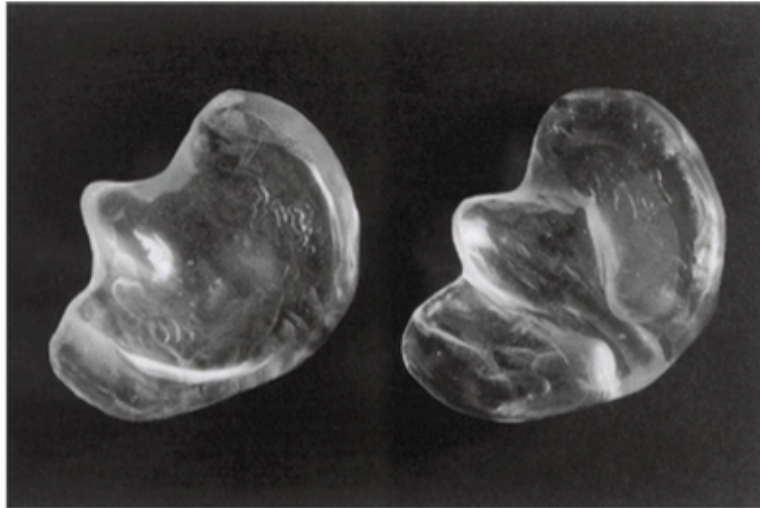

Figure 10: Acrylic Plates: Acrylic plates are modeled and constructed in order to be placed in a child's mouth that is affected by cleft palate to diminish the cleft palate and facilitate future craniofacial surgeries. Figure is taken from Prahl-Andersen (2000).

Conferring to this study and subsequent studies, benefits of orthodontic plates include facilitation of feeding, repositioning of the maxillary segments, normalization of tongue function, facilitation of surgery, better speech, and a positive psychological effect

on parents (Prahl-Andersen, 2000). Even though treated children may still demonstrate abnormal speech compared to normal, noncleft children, orthopedics has shown to positively influence speech and thus, facilitate the process of SLP care. On the other hand, Dr. Prahl-Andersen discussed that children with cleft anomalies are at risk for dental carries according to clinical trials and pure longitudinal studies done in Amsterdam during the year of 1985. The study shows that the highest incidence of manifested caries was found in the teeth adjacent to the oral cleft. Additionally, dental caries was significantly associated with preoperative orthopedic treatment. All in all, children treated with orthopedics should be subjected to a preventive program in order to maintain a healthy primary dentition (Prahl-Andersen, 2000).

Along with the orthopedic intervention in optimizing treatment and care for a patient with cleft, the prediction of the treatment outcome based on the interventions applied has demonstrated positive results. However, the success of these interventions needs to be continuously fostered (Prahl-Andersen, 2000). The reasoning behind not being able to predict such a principle is because there is vast variation found among cleft patients and because statistical analysis of such studies is very difficult (Prahl-Andersen, 2000). Nevertheless, this conveys that multidisciplinary treatment is necessary and effective, but must be tailored based upon each child's case. The measurement of performance and outcomes for each child should be processed and analyzed in order to improve and advance treatment. Table 2 demonstrates a time-line that should serve as a guideline in multidisciplinary treatment for patients with cleft anomalies.

Table 2: Surgical Treatment and Intervention of Clef Lip and Palate by Age
 Table amended from Hopper, Cutting, & Grayson, 2007.

Age	Treatment	Cleft Team Members
Prenatal	Prenatal imaging, diagnosis, and counseling	Multidisciplinary
Newborns	Feeding assessment, medical assessment, genetic counseling, treatment information	Orthodontist Plastic surgeon
0-3 months	Presurgical orthopedics	Plastic surgery
3 months (or after presurgical orthopedics)	Primary cleft lip repair and tip rhinoplasty ± gingivoperiosteoplasty	Plastic surgeon Otolaryngologist
12 months (delayed if airway or medical concerns)	Primary cleft palate repair with intravelar veloplasty ± bilateral myringotomy and tubes	Speech pathologist Plastic Surgeon, Otolaryngologist, Orthodontist
Diagnosis of velopharyngeal insufficiency (3-4 years)	Secondary palate lengthening or pharyngoplasty, speech obturator	Plastic surgeon
School-age years	Treatment of secondary lip and nasal deformities	Orthodontist
7-9 years (mixed dentition)	Secondary alveolar bone graft	Orthodontist Plastic surgeon Oral surgeon
Postalveolar graft	Presurgical orthodontics	Orthodontist
Puberty	Definitive open rhinoplasty	Plastic surgeon
Skeletal maturity	LeFort I ± mandible orthognathic surgery	Plastic surgeon Oral surgeon

A study of 54 children and adolescents from an outpatient craniofacial anomalies surgery clinic was evaluated for the basis of examining the parent's perception of the health-related quality of life of their child (Warschausky, Kay, Buchman, Halberg, Berger, & Farmer, 2002). In this study, 50% of the subjects have cleft lip and/or palate, and the rest have other craniofacial diagnoses. Health and health-related quality of life was assessed with the Child Health Questionnaire version PF28 that was completed by the parents and yielded physical and psychosocial status scale scores. Health-related quality of life is a rubric that includes several aspects of personal experience, including physical and psychological health, cognitive function, social role performance, and general life satisfaction. This study stressed the examination of parents' perception of their children's physical and psychosocial health as well as the perceived impact of children's health on parents' personal time, subjective distress, and family functioning. The key indicators of children's quality of life include psychological status and family and social functioning (Warschausky et al., 2002).

Many researchers agree that children with craniofacial anomalies seem to be at increased risk of social difficulties. Elucidating the association between craniofacial conditions, social skills, psychological adjustments, and family functioning is difficult because: there is a wide range of craniofacial conditions, a variable prevalence of developmental disabilities and learning disorders in children with craniofacial anomalies, and many effects of development on the course of childhood and adolescence (Warschausky et al., 2002). Children with craniofacial anomalies are at a risk for teasing and other forms of poor peer acceptance, which can contribute to an increase sense of

social isolation (Warschausky et al., 2002). Also, there have been some indications that parent-child attachment problems may occur with greater frequency for children with craniofacial anomalies. Parents often struggle with feelings of loss, anger, guilt, and anxiety after the birth of their child having such an anomaly. Additionally, such parents have been found to experience less social support and satisfaction with their social networks (Warschausky et al., 2002).

Results suggest that there is a significant relationship between perceptions of physical and psychosocial health in the subjects of children with craniofacial anomalies and a greater health concern associated with poorer adjustment (Table 3). Moreover, this study demonstrated a positive correlation between perceived physical and psychological health concerns and parents' self-reported stress. Parents of children with craniofacial anomalies tend to associate the mental and physical health of their children with behavior issues, family functioning, and their own feelings of stress (Warschausky et al., 2002). In summation, the psychosocial needs of children with craniofacial anomalies and their families may be addressed by having greater involvement with mental health professionals such as psychologists, social workers, and once again – multidisciplinary treatment teams (Warschausky et al., 2002). Additionally, it is critical to educate other members of the multidisciplinary team about common family, behavioral, and mental health concerns.

Table 3: Findings in Parents' Perceptions of General Health in their Children
 Table is amended from Warschausky, Kay, Buchman, Halberg, Berger, & Farmer, 2002

CHQ-28 Subscale*	Cleft Lip and/or Palate	Non-Cleft Lip and/or Palate	Normative
General Health	72.9 ± 20.7	59.6 ± 24.4	73.8 ± 20.2
Physical Functioning	91.8 ± 25.0	93.0 ± 16.3	94.4 ± 17.6
Role/Social- Emotional	97.5 ± 12.8	90.1 ± 25.8	92.1 ± 19.9
Role/Social- Physical	98.8 ± 93.4	92.6 ± 19.2	93.4 ± 20.6
Body Pain	80.7 ± 23.8	83.1 ± 26.9	79.9 ± 20.2
Behavior	66.6 ± 23.7	67.4 ± 21.8	70.3 ± 19.2
Mental Health	80.9 ± 15.3	80.4 ± 17.3	79.3 ± 15.0
Self Esteem	78.4 ± 24.3	85.5 ± 20.1	79.5 ± 18.4
Parent Impact- Emotional	72.2 ± 24.8	79.5 ± 25.5	80.1 ± 19.0
Parent Impact- Time	92.6 ± 13.3	87.2 ± 28.4	87.7 ± 21.6
Family Activities	85.1 ± 22.9	82.9 ± 28.6	90.7 ± 20.4
Family Cohesion	65.6 ± 26.0	74.6 ± 21.0	72.0 ± 21.2

CHQ-28, Child Health Questionnaire version PF28.
 * Range of subscale scores = 0-100 for all scales except Mental Health (16-100).

From 1969-1970, assessments of the cleft palate services team showed that only 3% of the teams in the U.S. included a medical geneticist as one of the disciplines. By 1976, 26% of the teams included one and 55% had some related genetics services such as biochemical testing (Rollnick & Pruzanksy, 1981). Ever since, there has been an increased availability of genetic services for patients with cleft anomalies. In the 1970s, the American Cleft Palate Association regarded inclusion of a geneticist in a multidisciplinary team as ideal, but not necessary (Rollnick & Pruzanksy, 1981). Research and studies have shown that genetic services are rather an essential component than an elective one. The record of the Center of Craniofacial Anomalies at University of Illinois (CCFA-IL) was assessed in order to formulate this principle (Table 4) (Rollnick

& Pruzanksy, 1981). Similar to orthodontic appliances, the need of geneticists depends on the individual with cleft anomalies because of the wide variations among the population.

Table 4: History and Growth of the Genetics' Realm
Table amended from Rollnick & Pruzanksy, 1981

<i>Event</i>	<i>Public Support</i>	<i>Private Support</i>
Service	1935 Social Security Act Crippled Children's Programs 1978: National Genetics Disease Act 1st federal funding of genetic services (Rollnick, 1979)	1938: 1st U.S. Cleft Palate Clinic, Lancaster, PA 1960's: National Foundation March of Dimes birth defects centers
Research	1958: NIH financial support (NIGMS, NIDR)*	1st CCFA: 1967 1958: National Foundation March of Dimes financial support
Scientific Conferences	1959: Gatlinburg Conference on Congenital Malformations of the Face and Associated Structures (Pruzansky, 1961)	1960: 1st annual conference on congenital malformations, sponsored by the National Foundation—March of Dimes

* NIDR—National Institute of Dental Research
NIGMS—National Institute of General Medical Sciences

TABLE 3. Formation of Societies in Genetics and Developmental Biology—U.S.A.

<i>Society</i>	<i>Founded</i>	<i>1st Meeting</i>	<i>Publication</i>
American Cleft Palate Association	1943	1943	1951 Cleft Palate Jour.
American Society of Human Genetics	1947	1948	1949 Amer. J. Hum. Genet. 1968
Teratology Society	1960	1961	1981 Teratology
Society for Craniofacial Genetics	1977	1978	1981 Craniofacial Genetics & Developmental Biology
National Society of Genetic Counselors, Inc.	1977	1979	1979 Perspectives in Genetic Counseling

Clinical genetics has flourished over the past few decades because of advances in cytogenetic, biochemistry, microbiology, and syndrome identification. Also, application of these advances to clinical medicine has been innovative (Rollnick & Pruzanksy, 1981). Another way genetics has become more established over the years is its development of professional training programs, formal organizations, increasing public awareness, and

demand for genetic services. By 1976, researchers identified and delineated a large number of syndromes associated with cleft anomalies and distinguished them etiologically from nonsyndromic facial clefts. Furthermore, federal and private sources provided support for genetic services to children with congenital malformations, research and research training in genetics, and scientific conferences on congenital malformations (Rollnick & Pruzanksy, 1981). Table 4 demonstrates the events and societies in fostering genetics and formalizing clinical genetics.

Most commonly, craniofacial anomalies are the result of multifactorial inheritance and the interaction of the child's genetic background with the environment. The geneticist's role and responsibility in the multidisciplinary team is to identify the etiology and/or pathogenesis of the child's craniofacial anomaly (Wornom & Will, 2007). This information is then used to discuss overall prognosis for the patient and the risk of disease in the parents and other family members. As with many other birth defects, craniofacial anomalies may result from chromosomal abnormalities, single gene disorders, and environmental factors. Since the 1970s and especially in the past 10 years, there has been great progress in identifying the causative factors of single gene disorders that lead to craniofacial anomalies. Molecular testing is now frequently used in clinical management. Mutations in different genes may produce the same phenotypes, and different mutations in the same gene may result in different phenotypes. The tissue distribution of a mutation can produce a wide range of phenotypes from a multisystem disorder to a tumor (Wornom & Will, 2007, n.d.).

Current areas in genetics that are under investigation for craniofacial anomalies and disorders are: genetic mutations that increase an individual's susceptibility for a given error in morphogenesis but produce a phenotype only through interaction with other genes or other factors; genetic mutations that produce phenotypes directly; genetic mutations that modify expansion of disease by producing genes and thereby altering the phenotype (Wornom & Will, 2007). Moreover, the geneticist's role in multidisciplinary team is essential because they aim to understand the molecular pathogenesis of a condition, which will hopefully translate into novel strategies for treatment by manipulation of cellular pathways. Also, recognizing the factors that impact susceptibility and risk can lead to effective strategies for prevention (Wornom & Will, 2007, n.d.). All in all, geneticists are crucial in the multidisciplinary treatment for patients with craniofacial anomalies. Their abilities to communicate with parents about why this malformation developed, to identify possible treatments to better the condition, and to predict future outcomes are noteworthy and optimize the patient's overall health.

DISCUSSION

There are many therapeutic options for members of the multidisciplinary team to contribute in the treatment of a patient with craniofacial anomalies and abnormalities. This paper thoroughly reviewed malformations, diseases, and cancers that can take place in the oral cavity and oropharynx, causative agents that prompt such an anomaly, a variety of secondary problems that arise from these conditions, and how studies of different disciplines in craniofacial treatment optimizes health. The importance of otolaryngologists, plastic surgeons, general dentists, prosthodontists, orthodontists, oral surgeons, pediatricians, neurologists, geneticists, social workers, psychologists, audiologists, and speech therapists are collectively stressed to better the overall health and quality of life of a patient with a craniofacial anomaly. More importantly, there have been several institutes that manifest this team-based approach.

The “Craniofacial Team” in Minnesota adopted a similar model with the focus of optimizing craniofacial treatment by multidisciplinary inclusions (Children's Hospitals and Clinics of Minnesota, n.d.). This establishment stresses “building confidence” in babies, children, and adolescents experiencing craniofacial abnormalities. They work to obtain the best results by including multiple disciplines of professionals and by implementing a set of principles which include tailoring a plan, never giving up, transforming lives, looking ahead, and answering questions (Children's Hospitals and Clinics of Minnesota, n.d.).

Similarly, Children’s Hospital in St. Louis (n.d.) has a “Cleft Palate and Craniofacial Institute” that encompasses a multidisciplinary approach in treatment.

Additionally, this model provides a domain on educating parents how to properly feed their babies that are experiencing craniofacial anomalies and greatly weigh the importance of physicians collaborating with speech and language pathologists. Mott Children's Hospital at the University of Michigan (n.d.) has one of the most experienced craniofacial anomalies program that greatly functions based on a multidisciplinary combined effort of professionals. Not only that, this program includes the domain of research, thereby studying how this implemented multidisciplinary approach can succeed and hopefully excel and innovate.

Nevertheless, not all craniofacial institutes and organizations highly embrace multidisciplinary principles such as the ones in Minnesota, St. Louis, and Michigan. Many programs include surgeons and dentists, but regard other specialties as supportive care (Mott Children's Hospital, University of Michigan Health System, n.d.). Even though there is an avenue in attaining disciplines of other care, studies and successful craniofacial programs have proven that an integrated, multidisciplinary team is the optimal way in treating patients with craniofacial anomalies and abnormalities.

After thoroughly reading about the types of tumors, cancers, anomalies, and abnormalities that can occur in the oral cavity and oropharynx and the associated systemic, social, and mental issues that can arise in these cases, multidisciplinary treatment and its implementation with craniofacial care is optimal. However, there is still need for advancement. Each discipline discussed in the published results section worked with several factors, whether it be constructive reformation of the anomaly, improvement of speech and communication, providing supportive care to the patient's parents, or

gathering information on whether a future sibling of the patient is at risk overlapped with another profession. There are many team members that need to work together in developing a plan catered to an individual's needs. Having a universal computer-based system or portal solely for craniofacial treatment including the domains of plastic surgeons, dentists, speech and language pathologists, psychologists, audiologists, geneticists, including up-to-date research regarding this matter, will advance the principle of multidisciplinary treatment and help future treatments of craniofacial anomalies. In this way, it will ease communication, provide information, and update all team members that are treating an individual with a craniofacial anomaly. Furthermore, it will be a novel, integrated, popular, and pioneering asset to the healthcare world, serving as a prime example for other treatments as well.

An example of a medical condition that could adopt a similar approach is acne. Although it is a much more common condition that affects the global population, whereby 50 million Americans are affected each year, such a skin condition almost always prompts additional problems and issues as well. Acne often causes significant physical and psychological problems, poor self-image, and even depression and anxiety. Since acne is a more common issue and not significantly associated with secondary problems, promoting interdisciplinary care and communication among the dermatologist, nurse practitioner, psychologist, and social worker could readily be achieved and improve the health of the affected individual, just as proven with those affected with craniofacial anomalies.

In summary, a multidisciplinary approach in treatment should be implemented when treating craniofacial anomalies. Yet, this process of including different disciplines of professionals and exchanging dialogue between professionals about a patient's treatment not only treats a patient's anomaly, disorder, and disease – but it also improves the overall well-being and quality of life of a person. Often, professionals in the healthcare system focus their efforts on a specific pathological area and forget other factors such as the patient's mental and social health. This principle, if implemented in many fields and professions, can transform the healthcare system for the better.

REFERENCES

Akamnu, I. N., & Olusegun, F. I. (2011). Ectopic thyroid: Etiology, pathology and management. *Hj Hormones*, 10(4), 261-269.

Canadian Cancer Society (n.d.) [Benign tumours and conditions of the oral cavity - \(n.d.\). Retrieved July 17, 2016, from http://www.cancer.ca/en/cancer-information/cancer-type/oral/oral-cancer/benign-tumours/?region=on](http://www.cancer.ca/en/cancer-information/cancer-type/oral/oral-cancer/benign-tumours/?region=on)

Chaturvedi, A. K., Engels, E. A., Pfeiffer, R. M., Hernandez, B. Y., Xiao, W., Kim, E., ... & Liu, L. (2011). Human papillomavirus and rising oropharyngeal cancer incidence in the United States. *Journal of Clinical Oncology*, 29(32), 4294-4301.

Chiang, M., Hsieh, Y., Tseng, Y., Lin, J., & Chiang, C. (2014). Oral mucosal lesions and developmental anomalies in dental patients of a teaching hospital in Northern Taiwan. *Journal of Dental Sciences*, 9(1), 69-77.

C.S. Mott Children's Hospital, University of Michigan Health System (n.d.) [Craniofacial Anomalies. Retrieved July 15, 2016, from http://www.mottchildren.org/conditions-treatments/pediatric-craniofacial-anomalies](http://www.mottchildren.org/conditions-treatments/pediatric-craniofacial-anomalies)

Dilsiz A, Aydin T, Gursan N. Capillary hemangioma as a rare benign tumor of the oral cavity: a case report. *Cases Journal*. 2009;2:8622. doi:10.4076/1757-1626-2-8622.

Friend GW, Harris EF, Mincer HH, Fong TL, Carruth KR. [Oral anomalies in the neonate, by race and gender, in an urban setting. *Pediatr Dent*. 1990 May-Jun;12\(3\):157-61.](#)

Hopper, R. A., Cutting, C., & Grayson, B. (2007). Cleft lip and palate. *Grabb and Smith's Plastic Surgery. 6th Edition. Philadelphia: Lippincott Williams and Wilkins, 201.*

Johns, D. F., Rohrich, R. J., & Awada, M. (2003). Velopharyngeal Incompetence: Plastic and Reconstructive Surgery, 112(7), 1890-1898.

Katz, J., Guelmann, M., & Barak, S. (2002). Hereditary gingival fibromatosis with distinct dental, skeletal and developmental abnormalities. *Pediatric dentistry*, 24(3), 253-256.

Kos, M. (2004). Head and neck congenital malformations. *Acta Clinica Croatica*, 43(2), 195-201.

Lindsay WK. Congenital Abnormalities of the Mouth. *Canadian Family Physician*. 1976;22:63-69

Neville, B. W., & Day, T. A. (2002). Oral cancer and precancerous lesions. *CA: a cancer journal for clinicians*, 52(4), 195-215.

Patil S, Rao RS, Majumdar B. Hamartomas of the oral cavity. *Journal of International Society of Preventive & Community Dentistry*. 2015;5(5):347-353. doi:10.4103/2231-0762.164789.

Pillemer, F. G., & Cook, K. V. (1989). The psychosocial adjustment of pediatric craniofacial patients after surgery. *Cleft Palate J*, 26(3), 201-7.

Prahl-Andersen, DDS, Ph. D, B. (2000). Dental treatment of pre dental and infant patients with clefts and craniofacial anomalies. *The Cleft palate-craniofacial journal*, 37(6), 528-532.

Reamy, B. V., Derby, R., & Bunt, C. W. (2010). Common tongue conditions in primary care. *Am Fam Physician*, 81(5), 627-34.

Rollnick, B. R., & Pruzansky, S. A. M. U. E. L. (1981). Genetic services at a center for craniofacial anomalies. *Cleft Palate J*, 18(4), 304-13.

Rutrick R, Black PW, Jurkiewicz MJ. Bilateral cleft lip and palate: presurgical treatment. *Ann Plast Surg*. 1984 Feb. 12(2):105-17.

Saint Louis Children's Hospital, Cleft Palate and Craniofacial Institute (n.d.) [Meet the Team. \(n.d.\). Retrieved June 15, 2016, from http://www.stlouischildrens.org/our-services/cleft-palate-and-craniofacial-institute/meet-the-team](http://www.stlouischildrens.org/our-services/cleft-palate-and-craniofacial-institute/meet-the-team)

Scope of Practice in Speech-Language Pathology. (n.d.). [Retrieved June 15, 2016, from http://www.asha.org/policy/SP2007-00283/](http://www.asha.org/policy/SP2007-00283/)

Tewfik, T. L., MD. (2015, April 17). Cleft Lip and Palate and Mouth and Pharynx Deformities. [Retrieved July 15, 2016, from http://emedicine.medscape.com/article/837347-overview](http://emedicine.medscape.com/article/837347-overview)

Toso A, Colombani F, Averono G, Aluffi P, Pia F. Lingual thyroid causing dysphagia and dyspnoea. Case reports and review of the literature. *Acta Otorhinolaryngologica Italica*. 2009;29(4):213-217.

Villa, A., Villa, C., & Abati, S. (2011). Oral cancer and oral erythroplakia: an update and implication for clinicians. *Australian dental journal*, 56(3), 253-256.

Warschausky, S., Kay, J. B., Buchman, S., Halberg, A., Berger, M., & Farmer, J. E. (2002). Health-related quality of life in children with craniofacial anomalies. *Plastic and reconstructive surgery*, 110(2), 409-414.

Wornom, IL and Will, LA (2007) American Cleft Palate-Craniofacial Association, [Core Curriculum for Cleft Palate and Other Craniofacial Anomalies](http://acpa-cpf.org/core_curriculum/genetics.html). Retrieved from http://acpa-cpf.org/core_curriculum/genetics.html

Zalzal GH, Cotton RT. Non-cleft disorders of the oral cavity and oropharynx. Cummings CWFredrickson JMHarker LAKrause CJSchuller DEeds. *Otolaryngology-Head and Neck Surgery*. 2nd ed. St Louis, Mo Mosby-Year Book Inc1992;1170- 1171

CURRICULUM VITAE

Lemma M. Salem
Cell: (781)-974-8522
lemsal93@bu.edu
4 Charlesgate East, Apt 304
Boston, MA 02215
Born: 1993

A. Education

- a. *Boston University*
 - i. B.S. in Human Physiology, 2015
- b. The Boston University College of Health and Rehabilitation Sciences: Sargent College
- c. *Boston University School of Medicine*
 - i. M.S. in Oral Health Sciences, 2016
 - ii. Division of Graduate Medical Sciences

B. Employment Positions

- a. *Front Desk Receptionist*
 - i. Alpha Dental Center P.C., Weymouth Family Dental Care
 - ii. As a front desk receptionist, my main responsibilities were to check-in and check-out patients for their appointments, evaluate and update medical charts, create treatment plans for patients, organize and enter in the computer the insurance checks and payments, and scan patient's information into the system
- b. *Dental Assistant*
 - i. Alpha Dental Center P.C., Weymouth Family Dental Care
 - ii. As a dental assistant, my primary responsibilities were to set up and clean the operatory, seat patient in chair, clean dental instruments, take impressions, occasionally create temporary bridges and crowns
- c. *Private Tutor*
 - i. Randolph, MA; Brookline, MA
 - ii. My responsibilities as a tutor were to help my students develop a proper work ethic, effective study habits, and go over concepts and topics they struggled with, especially in Spanish, Mathematics, and Writing.

C. School-Related Extracurricular Activities

- a. *Islamic Society of Boston University*
 - i. September 2012 – May 2015
 - ii. Helped raise money for charitable events, assisted in organizing intersectional events, helped students and members educate general public about Islam
- b. *Students for Justice in Palestine*
 - i. September 2012 – May 2015
 - ii. Cultural Night Coordinator 2013
 - iii. Treasurer, September 2014

- iv. Promote awareness about situations in Palestine and Israel, organize educational events, coordinate fundraising and cultural events, and spread awareness about past and current issues
- c. *BU Community Service Center*
 - i. January – May 2013
 - ii. Conversation Buddy
 - iii. Each week, I would dedicate 2-4 hours with students at the Center for English, Language, and Orientation Program (CELOP) by helping them improve their English language, writing, and conversational skills.
- d. *Boston University Global Medical Brigades*
 - i. January 2014
 - ii. Volunteer
 - iii. I traveled to Tegucigalpa, Honduras with fellow students, medical and dental professionals. We served and provided medical and dental care to El Obraje community for a week.

D. Non-School Related Activities

- a. *Islamic Society Boston Cultural Center (ISBCC), Roxbury, MA*
 - i. Religious/Community
 - ii. September – December 2013
 - iii. Volunteer
 - iv. During the fall semester of 2013, volunteers and myself would go to the ISBCC a few times each month to package and prepare food for the less fortunate families of the greater Boston area
- b. *Muslim Student Association Mentorship - MIT*
 - i. January – May 2014
 - ii. Volunteer Tutor
 - iii. Helped students from the greater Boston community with college resumes, essays, and standardized test taking skills
- c. *Red Crescent – West Bank, Palestine*
 - i. July – August 2014
 - ii. Volunteered with the Red Crescent in the West Bank at various sites; volunteers and I helped raise money for families in need, collect clothes, medications, and other necessary items for the unfortunate communities and refugee camps in the West Bank area, visit the sick and elderly in hospitals, and prepare and engage in activities for the youth

E. Clinical Experiences

- a. *Dental Shadowing & Assisting*
 - i. May – July 2014
 - ii. 100 Hours
 - iii. Dr. Jawad Shakarchi, Weymouth Family Dental Care (Weymouth, MA), Star Dental (Norwell, MA)
 - iv. Was able to see how crowns are delivered, various extractions (mostly on older patients), root canals, fillings, sealants, and several cases regarding cosmetic dentistry

b. Dental Shadowing & Assisting

- i. May – July 2013
- ii. 100 Hours
- iii. Dr. Larry Sarner, Alpha Dental Center P.C. (Franklin, MA)
- iv. Was able to see many procedures performed on younger patients and children such as fillings and sealants, learned skill sets that are necessary when working with children, observed and assisted with extractions and root canals

F. Research Experiences

a. Henry M. Goldman School of Dental Medicine: Department of Health Policy and Health Services Research

- i. Intern and Practicum
- ii. September 2014
- iii. Supervisor: Ms. Kathy Lituri, RDH, MPH, Oral Health Promotion Director
- iv. The main focus of this experience was oral and public health, where the goal was to educate the public about oral health and help children, adults, and underserved communities seek dental care and develop a better understanding of the importance of oral health