

1954

# Upper extremity amputees and their prostheses

---

<https://hdl.handle.net/2144/8577>

*Downloaded from DSpace Repository, DSpace Institution's institutional repository*

Ed.  
Grigsby, Hazel  
Service paper  
1954  
*stored*

BOSTON UNIVERSITY  
SCHOOL OF EDUCATION

Service Paper

UPPER EXTREMITY AMPUTEES  
AND THEIR PROSTHESES

Submitted by

Hazel Grigsby  
(A.B., University of Kentucky, 1941)

In Partial Fulfillment of Requirements for  
the Degree of Master of Education

1954

Boston University  
School of Education  
Library

EdM  
1954  
gri

Official Readers

First Reader: Leslie W. Irwin, A.M., Ph.D.

Professor of Education

Second Reader: Clem W. Thompson, M.A., Ph.D.

Assistant Professor of Education

## Introduction

The purpose in writing this dissertation, is to produce a source of information on rehabilitation of the upper extremity amputee, which can be used for teaching purposes and for clinical reference by the various people working with this phase of rehabilitation. The need for a reference, such as the one proposed, has become pronounced in the last ten years.

Until WWII, (World War II) the deficiencies of the upper extremity prosthesis, and consequent rehabilitation of the upper extremity amputee, were obscured by the fact that the number of these amputees in any one section of the country was not great enough to stimulate private industry to engage in expensive, scientific, research necessary to make an adequate prosthesis. The intricate motions of the hand are almost impossible to simulate. Consequently, little has been known about prostheses, physical therapy measures, training and use of the prosthesis, which has resulted in poorly trained personnel.

World War II brought great numbers of upper extremity amputees. Our government, which is dedicated to the task of rehabilitating every individual to normal or as near normal as possible, could not ignore the plea for needed research in prostheses, and as a result, a long and expensive research project, sponsored by The National Research Council was launched. Now, better prostheses is motivating personnel to participate in "better



know how."

Whenever possible, the writer has collected the technical material herein, which is resulting both directly and indirectly from the research mentioned earlier by personal contact. For the past three years, the writer has been privileged to be present at the Prosthetic Clinics held in the Regional Office of The Veterans Administration. Here, the surgeon, the prosthetists, the physiatrist, and the physical therapist, meet with the amputees to evaluate their problems and to prescribe prostheses. At a later date, the amputees receive physical therapy when indicated, and training in the use of their prostheses. The Boston Regional Office is one of the many distributing outlets throughout the country for prosthetic devices coming out of the research project.

During these past three years, 69 arm amputees have passed through this clinic for evaluation, prescription, and training. The writer was able to talk personally with most of this number about their particular needs, problems, and desires, and was permitted to make the photographs shown in this paper. Fifteen of these actual cases, with corresponding photographs on training, are included. This dissertation has been read by six people who are considered authorities on the subject of upper extremity amputees and their suggestions have been well taken. The writer has further augmented her store of technical information by: attending the Annual Conference on Upper Extremity Amputees, Kessler Institute for Rehabilitation, 1953; numerous meetings and panel discussions that featured speakers and demonstrations on upper extremity problems in the Boston area; saw the Veterans Administration Medical Film entitled,

"Upper Extremity Case Study Unit," 1952.

The review of literature has been limited to what has been written in English, and further limited by the fact that the writer was not able to procure some of the case study units of the research program.

Personal contact with professional people and amputees has been limited to those living in the eastern states and principally in the vicinity of Boston.

## TABLE OF CONTENTS

CHAPTER	Page
I. UPPER EXTREMITY AMPUTATIONS.....	1
Surgery.....	1
Open method.....	1
Closed method.....	2
Sites of Election.....	2
Hands and fingers.....	2
Wrist disarticulation.....	3
Krukenberg pincers.....	3
Below the elbow (BE).....	4
Above the elbow (AE).....	6
Shoulder disarticulation.....	6
Cineplasty.....	8
Cineplasty sites for muscle motors.....	8
Surgical aspects of the muscle motor.....	10
Summary.....	10
II. PHYSICAL THERAPY FOR UPPER EXTREMITY AMPUTEES.....	13
Approach to the amputee.....	13
Care of the Stump.....	14
Immediate post-operative physical therapy.....	14
Bandaging the stump for shrinking.....	15
Technique.....	16
Phantom limbs.....	17
Painful phantom.....	17
Painless phantom.....	18
Beneficial Modalities.....	18
Massage.....	18
Precautions.....	20
Infra red whirlpool and hot soaks.....	20
Ultra violet irradiation and ion transfer.....	20

## CHAPTER

Page

Conditioning the Stump.....	21
Hands and fingers.....	21
Below-elbow amputation stump.....	22
Above-elbow amputation stump.....	23

Physical Therapy for Cineplasty.....	25
Pre-operative.....	25
Post-operative.....	27
Care of the muscle tunnel.....	29

Summary.....	30
--------------	----

### III. PROSTHESES.....32

Selection.....	32
----------------	----

Conventional Below-Elbow Prostheses.....	34
Prostheses for wrist disarticulation.....	34
Prostheses for the long amputation.....	35
Prostheses for the medium length amputation.....	35
Prostheses for the short amputation.....	37
Prostheses for the very short amputation.....	37
Heavy duty below-elbow prostheses.....	38

Above-Elbow Conventional Prostheses.....	38
Prosthesis for the elbow disarticulation.....	38
Prosthesis for the standard or long amputation.....	39
Prosthesis for the short above-elbow amputation.....	41
Prosthesis for the shoulder disarticulation.....	42
Heavy duty above-elbow prostheses.....	42

Hands, Hooks.....	43
Hands.....	43
Hooks.....	44
Voluntary opening hands and hooks.....	44
Voluntary closing hands and hooks.....	45
Partial hands.....	46

Fabrication of Upper Extremity Prostheses.....	47
Materials.....	47
Outline of steps in making a single wall plastic socket.....	47

Harness and Control Systems.....	49
Materials used for harness and control cables.....	50
Conventional unilateral and bilateral below-elbow harness.....	50

## CHAPTER

Page

Heavy duty below-elbow harness.....	51
Above-elbow suspension and control.....	51
Leather dual control.....	52
Leather shoulder saddle triple control.....	52
Webbing shoulder saddle for dual control.....	52
Minimum Standard of Performance for Upper Extremity Prostheses..	53
Below-elbow.....	53
Above-elbow.....	55
Cineplasty.....	58
Prosthesis for trans-carpel disarticulation with cinetized biceps.....	60
Prosthesis for the disarticulation at the wrist with cinetized biceps.....	61
Prosthesis for the medium to long below-elbow amputation with cinetized biceps.....	61
Prosthesis for the short below-elbow amputation with cinetized biceps.....	62
Disarticulation at the elbow with cinetized biceps.....	63
Prosthesis for the long above-elbow amputation with cinetized biceps.....	63
Prosthesis for the medium above-elbow amputation with cinetized pectoral.....	63
Prosthesis for amputations about the shoulder with cinetized pectoral.....	65
Summary.....	65
IV. TRAINING.....	68
Psychological aspects of training.....	68
Prosthetic Controls.....	69
Single control.....	69
Dual control.....	69
Triple control.....	71
Approach and Grasp.....	72
Operation of the voluntary closing hand.....	72
Operation of the voluntary closing hook.....	77
Two Handed Activities.....	78
Unilateral.....	79
Prosthetic hand activities.....	80
Bilateral.....	80

## CHAPTER

## Page

Undressing in the morning.....	80
Showering.....	81
Dressing.....	81
Clothing.....	83
Shaving.....	84
Combing the hair.....	84
Women and Children.....	84
Women.....	84
Children.....	85
Prescriptions and Training.....	87
Below-Elbow.....	87
Above-Elbow.....	90
Summary.....	93
Further Research Needed.....	96
SELECTED ANNOTATED BIBLIOGRAPHY.....	98
Glossary.....	100

# LIST OF PLATES

Plates	page
1,2, 3,4. Below-elbow amputation stumps. Plates 1 and 2, front and side views of the long type stump, plates 3 and 4 show different musculature and sizes of the short stump.....	5
5,6, 7,8. Above-elbow amputation stumps and a biceps cineplasty. Plate 5, a long type stump, plate 6, a short type stump, plate 7, a very short type stump, and plate 8, a biceps cineplasty on a below-elbow stump.....	7
9,10, 11,12. Plates 9 and 10, steps in bandaging the above-elbow stump. Plate 11, an above-elbow, unilateral amputee with scoliosis, plate 12, back extension exercise.....	19
13,14, 15. Resistive exercise for the following movements. Plate 13, abduction, plate 14, horizontal adduction, plate 15, serratus anterior.....	24
16,17, 18. Post-operative cineplasty. Plate 16, first insertion of the tunnel pin, plate 17, active contraction against resistance, plate 18, heavy resistance to over develop weak brachialis and brachio-radialis.....	28
19,20, 21,22. Below-elbow prostheses. Plate 19, rotation socket with leather inner socket and heavy duty leather saddle type harness, plate 20, medium length BE prosthesis with figure-eight harness, plate 21, short BE prosthesis showing figure-eight harness from the rear, plate 22, split socket prosthesis with step-up flexion and full arm cuff.....	36
23,24, 25. Above-elbow prostheses. Plates 23, 24, front and back views of the standard or long AE prosthesis with webbing shoulder saddle harness, plate 25, prosthesis for the short AE amputation stump.....	40
26,27, 28. Hand hook and controls. Plate 26, voluntary closing hand and hook, plate 27, AE figure-eight harness, plate 28, AE leather shoulder saddle harness with shrug control.....	48

## Plates

## Page

- 29,30. Testing scales and a cineplastic prosthesis. Plate 29, scales used in testing mechanical performance of prostheses, plate 30, a biceps cineplasty on a BE amputation stump with prosthesis (Note the scar on the forearm where the insertion of the biceps was severed).....57
- 31,32. Approach and grasp activities. Plate 31, the thumb of the hand in open position to grasp the large object, plate 32, the thumb of the hand in closed position to grasp the small object.....70
- 33,34, 35. Two handed activities. Plate 33, taking a cigarette from the package, plates 34,35, tying a tie.....73
- 36,37, 38,39. Two handed activities. Plate 36, BE amputee cutting food, plate 37, AE amputee cutting food, plate 38, BE amputee using a telephone and writing a message, plate 39, AE amputee using a telephone and writing a message.....74
- 40,41, 42. Two handed and prosthetic hand activities. Plate 40, opening a beer can, plate 41, carrying a food tray, plate 42, using a button hook and buttoning a shirt with the prosthetic hand.....75



CHAPTER I  
UPPER EXTREMITY AMPUTATIONS

1. Surgery

To fully discuss the many causes for upper extremity amputations is not necessary in this article. However, the subject cannot be entirely ignored, since the site of election and the type of prosthesis recommended, very often, depend on the cause of the amputation.

The more common reasons for this type of surgery are: trauma, tumor, infection, nerve injury, peripheral vascular disease, congenital anomaly, and thermal injury. All amputations are performed either by the open or closed method of surgery.

Open method

The open method of surgery, <sup>1/</sup> which is known as the guillotine, consists of cutting directly across the part and leaving the whole section exposed. It is done in two stages. Surgery of this type is usually performed following shock, infection, or severe trauma. This method is often used on the battlefield. Plastic repair on the stump is necessary before a prosthesis can be fitted. Until recently, only a few specific sites of election were considered good for upper extremity amputations in view of function of the prostheses. With the recent developments in prosthet-

1/Rufus H. Aldridge, "Sites of Election and Stump Pathology," The Journal of OALMA, (May 1951), pp. 4-8.

ics, almost any site of amputation can be supplemented by an adequate prosthesis.

### Closed method

The closed method of amputation is performed on the upper extremity when circumstances are more favorable. Good healing usually results and complications are fewer. Skin flaps are cut in such a way that their combined lengths are equal to the diameter of the arm through which the incision is made. The bone end is shaped perfectly smooth and the covering is: (a) skin <sup>1/</sup> alone, (b) skin and fascia, (c) skin and myo-fascial flaps.

The site of election is the most distal part of the arm that will permit adequate skin flaps to cover the end wound. Tissue resection and the formation of skin flaps vary with the site of amputation.

## 2. Sites of Election

### Hands and fingers

When considering amputation of the hand and fingers, it is important to save all the parts that can be used for substitution of function. Whenever possible, two opposing poles consisting of thumb and finger elements should be retained in order that the basic functions, pinch, grasp and hook, are not destroyed.

Whenever amputations of the metacarpels of both index and middle fingers are considered, it is advisable to resect them at their base so that the cup of the hand now formed by the ring, little finger, and thumb, will be left intact to preserve the pinch, grasp, and hook actions.

<sup>1/</sup>Donald B. Slocum, An Atlas of Amputations, C. V. Mosby Company, Saint Louis, 1949, pp. 60-97, 158-159.

When performing amputations of the metacarpels of the middle, index, and ring fingers, each bone should be resected so that the web drops in a gradual arc from the 5th finger to the thumb which will make easier opposition of the little finger with the thumb.

When amputations of the metacarpels begin with the little finger, the zig zag arc is slanted in the opposite direction.

The thumb is absolutely vital in pinch, important in grasp, and can be used as a hook. Any portion that is lost results in a disability for the thumb is dependent on length, mobility, muscle power, and sensation for maximum function. When loss is inevitable, the surgeon should make every effort to reconstruct the remaining portion so that substitution of function can be made possible.

#### Wrist disarticulation

A true wrist disarticulation is severance of the hand from the radius and ulna at the radio-ulnar joint. When the radius and ulna are removed at any point between the radio-ulnar joint and the styloid process, from the standpoint of a prosthesis, this is also considered wrist disarticulation. A functional prosthesis, which supplements the residuals of wrist disarticulation is proving this to be a more popular site of election. The stump must be: <sup>1/</sup> (a) well padded with palmer skin with a thick layer of fat and a normal blood supply, (b) free from pain when pronation and supination are performed and, (c) bony prominences well protected.

#### Krukenberg pincers

This secondary operation is limited to a long forearm, amputation

1/Donald B. Slocum, op. cit., p. 153.

stump near the wrist. "All the muscles and interosseous membrane are separated longitudinally between the radius and ulna for a short distance."<sup>1/</sup> The musculature is then rearranged and plastic repair applied to the skin defect between the bones. Thus, a crude, natural mechanism is formed which can be used for grasping and holding. Its greatest advantage is the retention of tactile sensation which is not found in a prosthesis. Blind amputees find this invaluable for reading Braille. A bilateral, blind amputee, who has a Krukenberg on one side and a biceps cineplasty on the other side, is able to grasp the muscle pin and insert it into the tunnel with the Krukenberg pincers. Special appliances can be made for this bifid arm with which the amputee can perform light work.

Below the elbow (BE)

When an amputation below the elbow is performed, as much length is retained as possible. Since the arm acts as a crane for the terminal device, the natural arm is more functional than the prosthetic arm. Elections between the wrist and the elbow are classified as long, medium, short, and very short.<sup>2/</sup> Measuring from epicondyle to styloid, these levels are: the long amputation stump is from eight to ten inches, the medium length is from  $5\frac{1}{2}$  to eight inches, the short stump is from  $3\frac{1}{2}$  to  $5\frac{1}{2}$  inches, and the very short stump is  $3\frac{1}{2}$  inches in length or less (plates, 1, 2, 3, 4, page 5). Provision for rotation in the prosthesis to supplement the nat-

<sup>1/</sup>George G. Deaver, M. D., Earle H. Daniel, "The Rehabilitation of the Amputee," Archives of Physical Medicine. (October 1949), 30-10: 648-654.

<sup>2/</sup>R. Deane Aylesworth, Editor, Upper Extremity Prosthetics, Manual, 1952, Artificial Limbs Project, Regents of the University of California, Los Angeles, Section, 5.1.1.

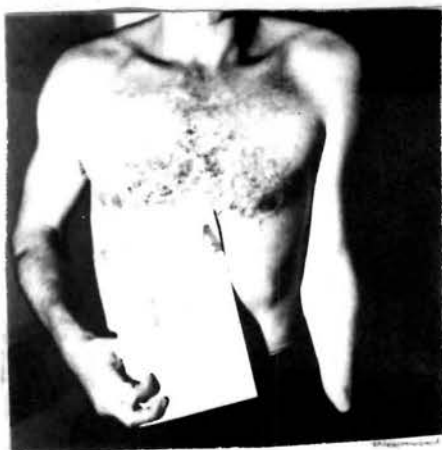

Plate 1



Plate 2



Plate 3

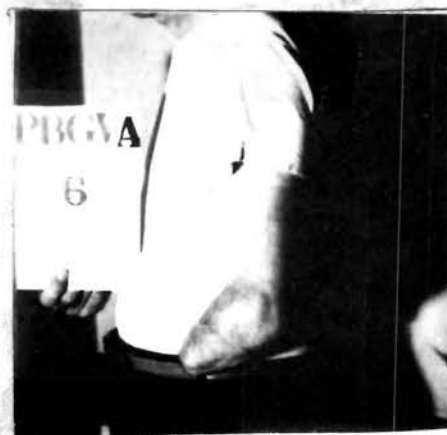

Plate 4

Below-elbow, amputation stumps. Plates 1 and 2, front and side views of the long type stump, plates 3 and 4 show different musculature and sizes of the short type stump

ural, residual pronation and supination has recently been developed. Improvement in prostheses has also made the short, below-elbow amputation stump advantageous over the above-elbow stump. The natural elbow can be utilized.

#### Above the elbow (AE)

Amputations above the elbow should be done as conservatively as possible. Elections from 90 to 50 per cent of acromion to epicondyle <sup>1/</sup> length are considered standard or long lengths and those elections from 50 to 30 per cent of acromion to epicondyle length are considered short, above-elbow lengths (plates, 5, 6, 7, page 7). Standard lengths are suitable for good prosthetic function. Short lengths are near the axillary fold of the arm and prosthetic function is limited.

#### Shoulder disarticulation

A true shoulder disarticulation is one which the humerus has been completely removed at the gleno-humeral joint. <sup>2/</sup> Cases ranging from the short, above-elbow to the interscapular-thoracic levels are considered shoulder disarticulation from the standpoint of prostheses, since shoulder motion is all that remains on the amputated side. Even shoulder motion is lost in the interscapular amputation. This election consists of surgical removal of the upper extremity between the scapula and thoracic wall and is usually performed following severe trauma, or malignant growths in the upper end of the humerus, scapula, or axilla.

<sup>1/</sup>R. Deane Aylesworth, op. cit., Section, 6.1.1.

<sup>2/</sup>Ibid., Section, 7.1.

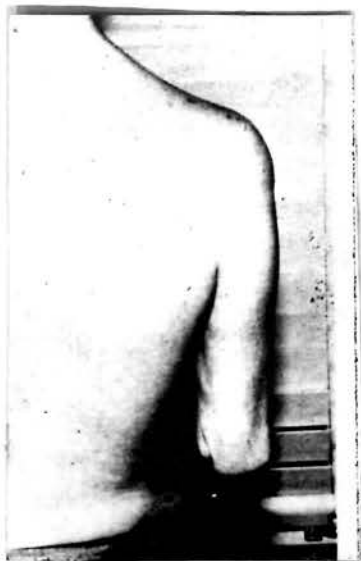

Plate 5



Plate 6

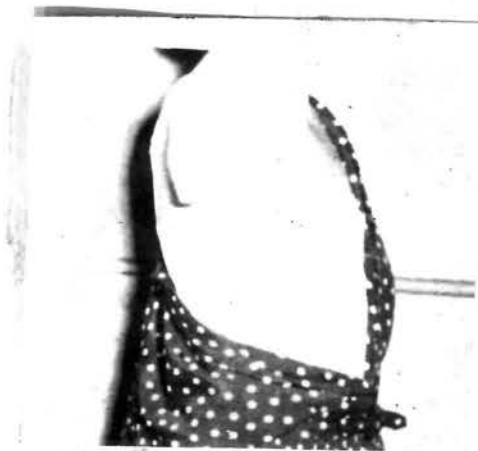

Plate 7

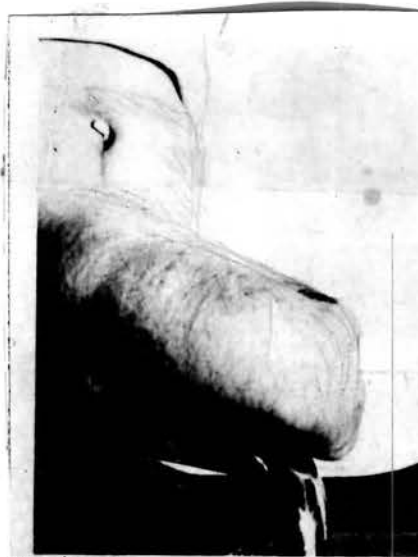

Plate 8

Above-elbow, amputation stumps and a biceps cineplasty. Plate 5, a long type stump, plate 6, a short type stump, plate 7, a very short type stump, and plate 8, a biceps cineplasty on a below-elbow stump

### 3. Cineplasty

The first cineplasty was performed in 1896 <sup>1/</sup> by Dr. Guliano Vanghetti in Italy. The number of soldiers left without hands as a result of war was so great, that Dr. Vanghetti conceived the idea of using the muscles of the stump to move the artificial appliance. The idea was good then and still is good but, until recently, it has not improved the working efficiency of the amputee. This has been due largely to the inadequacy of the prostheses.

Since World War II, considerable interest has been focused on the cineplastic method of controlling a prosthetic appliance in the United States. Many surgeons, engineers, prosthetists, physical therapists, occupational therapists, and trainers who are working with, and doing research with this method of control, are responsible for improving the techniques of surgery, stressing the significance of pre- and post-operative care of the muscle tunnel and, improvement of the prostheses.

#### Cineplasty sites for muscle motors

Choosing the best site for a muscle motor in view of the prosthetic controls is a basic consideration of the surgeon. An active muscle on a short, amputation stump is not considered good to use for a muscle motor, since the length of muscle largely determines the excursion of the muscle motor. Also, there may not be sufficient local skin on a short

<sup>1/</sup>Earle H. Daniel, Amputation Prosthetic Service, Williams and Wilkins, Baltimore, 1950, pp. 17-22.



stump to make a skin tube.

An above-elbow amputation stump that is shorter than 50 per cent of the upper arm is generally not used for a muscle motor. The site is chosen above the proximal joint. That is, if the above-elbow stump is too short for canalization of the biceps, the pectoralis major muscle is chosen. It has been the practice to canalize both the triceps and biceps muscles for opening and closing the prosthetic hand and/or hook. Sometimes the pectoral muscle is used for additional strength and control. Recent studies made with cineplasty at the University of California, Los Angeles <sup>1/</sup> and at Walter Reed General Hospital <sup>2/</sup> Washington, D. C., have made use of the biceps muscle alone on the below-elbow (plate 8, page 7), amputation stump, elbow disarticulation, and long, above-elbow amputation stump to control the motions of the prosthetic hand and/or hook. The pectoral muscle is used for the motor on amputations shorter than the long, above-elbow type. Cineplastic function described later in this dissertation is based on the results of these studies.

If the full length, biceps muscle is to be used for a motor, the skin flap is planned so that the first transverse cut will be placed three to  $3\frac{1}{2}$  inches above the external epicondyle. The base will be placed toward the medial side of the body. A short, wide flap is always considered best, and the base is always placed toward the side having the best

1/R. Deane Aylesworth, op. cit., Section, 10.0-11.5.

2/Col. August W. Spittler M. C., Lt. Col. Maurice J. Fletcher M. S. C., "Technique of Cineplastic Surgery and Prosthetic Appliance for Cineplasty," Off print, American Academy of Orthopaedic Surgeons Instructional Course Lectures, 1953, Volume 10, J. W. Edwards, Ann Arbor, Michigan, pp.378-394.

blood supply which is essential for good nourishment and consequent healing of the flap.

#### Surgical aspects of the muscle tunnel

When the desired level for the muscle motor is selected, the incision is placed squarely over this muscle in such a way that it will outline three sides of a square, each line of which is not less than three to  $3\frac{1}{2}$  inches. This flap is directed backward over its base, and the skin is inverted as the two free sides of flap are approximated. The outside of the skin becomes the inside of the tube, and the subcutaneous surface is outside the tube. The muscle belly is pierced transversely at right angles to the muscle fibers and the tunnel is made  $1\frac{1}{2}$  inches in diameter throughout. The skin tube is placed through the tunnel and sutured.

A four inch skin graft, which has been taken from the thigh or the abdomen of the amputee, is applied to the skin defect created by the formation of the skin tube.

The distal attachment of the biceps muscle is severed just below the myo-tendonous junction and then freed up to its lowest nerve supply. This will permit the tunnel to have greater excursion, and to prevent flexion of the forearm when tension is exerted on the muscle motor.

If a biceps muscle on an above-elbow amputation stump is to be used, the distal transverse cut is placed two inches above the amputated bone and the proximal transverse cut can be as high as  $\frac{1}{2}$  inch below the anterior axillary fold.

#### 4. Summary

Among the many causes for upper extremity amputations, the most

common are: trauma, infection, tumor, nerve injury, peripheral vascular disease, and thermal injury. Amputations are performed by the open method of surgery and consists of cutting directly across the part, or the closed method, which consists of making skin flaps, the combined lengths of which, are equal to the diameter of the arm through which the incision is made. The bone end is smoothed and covered with skin alone, or a combination of skin and fascia, or skin and myo-fascial flaps.

The hand and digits should be maintained as much as possible when considering amputation in order that pinch, grasp, and hook actions will not be lost. When amputation of the middle and index, or the middle, index, and ring fingers are considered, the metacarpels should be resected in such a way that they will drop in a gradual arc from the remaining finger or fingers to the thumb for better opposition. Amputations beginning with the little finger should have the metacarpels resected in a zig zag arc toward the remaining finger or fingers. Every effort should be made to save as much of the thumb as possible.

Elections for amputation above the elbow disarticulation are called standard or long, short, shoulder disarticulation, and inter-thoracic. A standard length stump is suitable for good prosthetic control. Prosthetic function of the short, shoulder disarticulation, and inter-thoracic level is limited.

The Krukenberg operation is secondary surgery performed only on a long, forearm stump. It consists of separating the two bones of the arm and re-arranging the musculature to make the arm bifid. It can then be used for grasping and is particularly useful because it retains its sense

of touch.

The cineplastic method consists of making a tunnel of skin which is inserted through the muscle belly on the amputated stump. A tunnel pin is inserted into the tunnel and attached to the controls of the prosthetic hand or hook.

The biceps and pectoral muscles are the most commonly used muscles for motors of the upper extremity. The surgeon chooses the best site for a motor in view of prosthetic function, good skin, and blood supply. A skin tube is formed and thrust through the hole which has been pierced transversely in the muscle belly and sutured. If a full length biceps muscle is used, the distal insertion is freed for better excursion of the motor. A skin graft is applied to the skin defect made by the formation of the skin tube.

## CHAPTER II

### PHYSICAL THERAPY FOR UPPER EXTREMITY AMPUTEES

#### Approach to the amputee

When a patient first learns of his proposed amputation, he immediately begins to think of all the things that could happen after he has lost this important part of his body. "Will I still be able to earn a living? How will my family accept me? Will people consider me a cripple? Will I be the object of pity?" These, and many other questions cause him great anxiety. It is now being recognized that this psychic trauma goes along with every amputation. Both the proficiency in performing tasks, and the ability to accept his limitations and live within them, require a healthy mental attitude. This attitude is not easily acquired. It must be nurtured throughout the course of amputation surgery and rehabilitation by careful guidance and insight into his emotional background by the physician in charge and various rehabilitation personnel who touch his daily life. There is no standard treatment which can be set for all amputees.

The physical therapist should visit the patient, whenever possible, before the scheduled amputation and begin to prepare him for the rehabilitation measures that will be necessary after surgery. She should explain the importance of good body alignment and correct positioning of the stump while he is a bed patient as well as when he becomes ambulatory. If there

are no complications, allow him to perform the ranges of motion and static muscle contractions that are necessary, and explain to him its importance. The therapist should be well informed on the subject of various prostheses, hands, hooks, and their functions and be able to describe them to the amputee. Begin immediately to stress the fact that with a prosthesis, he can perform all his daily tasks, but that much of his accomplishment will depend on his desire to be self-sufficient, his patience, and his effort. Stress the point that there will be a period of adjustment to the new limb, during which time, some discomfort may be experienced as with any prosthetic appliance. Encourage him to ask questions and answer them tactfully but truthfully. This confidence will do much to relieve the mental trauma caused by the expected amputation and it will make the job of rehabilitation an easier one.

### 1. Care of the Stump

#### Immediate post-operative physical therapy

A good fit and maximum dexterity of the prosthesis will depend <sup>1/</sup> largely on the musculature of the stump and the mobility of the surrounding joints. These areas must be given careful attention within a short time after surgery. If the patient has been visited by the physical therapist before surgery, he is aware of the proper positioning of the stump, the correct body alignment, and the initial exercises. Mild muscle contractions and gentle massage can be carried out, with due precaution of the suture areas, within a few days after surgery. This procedure will

1/R. Deane Aylesworth, op. cit., Section 8.0-8.4.

aid circulation, prevent adhesions, and reduce edema. The therapist should move all surrounding joints passively through the maximum range on the amputated side until the amputee is able to do this for himself. Limitation of motion of the joints that have been immobilized may be prevented by these simple measures.

A shoulder disarticulation amputee is dependent on both shoulders for the functioning of the prosthesis. Muscle contractions should be carried out on the muscles of the unaffected side, and all muscles of the amputated side that have not been separated and where there is no danger of disturbing the suture lines. Flexion, extension, elevation, and depression of both shoulders should be initiated.

#### Bandaging the stump for shrinking

A cylindrical shaped stump, free from excess tissue, is important for a good fit of the prosthesis. Experience has shown that the application of a shrinking bandage to the stump over a period of time will improve the shape of the stump. A bandage should not be applied until thorough healing has taken place.<sup>1/</sup> If it is correctly applied, it will prevent soft tissue swelling, and combined with disuse atrophy of the muscles, effective shrinkage will result without loss of circulatory efficiency.

The bandage should be applied first before the amputee becomes active in the morning while circulatory demands are at a minimum. An Ace type of bandage, two to three inches in width, is generally considered the best type of shrinking bandage. It should be applied snugly, under tension, to

---

<sup>1/</sup>Donald B. Slocum, op. cit., p. 464.



the entire length of the stump, making sure that the tension is lessened as the proximal portion of the stump is reached. It can be left on two to four hours and then removed. During these intervals the conditioning of the stump muscles can be carried out. The application of infra red, massage, and resistance exercise will re-establish the circulation and give a feeling of well being to the stump. A freshly laundered Ace bandage with good elasticity should be applied immediately following the exercise. The cycle of bandaging, followed by removal, should be kept up three or four times daily until adequate shrinkage has taken place.

A faulty technique in bandaging can make a poorly shaped stump. Care must be exercised to make the first spiral around the end firm but not tight enough to cause the skin to dimple. A very common fault in technique is to make the second and third spiral tighter than the first spiral, thus, creating a bulbous end which is a detriment to a good fit of the prosthesis.

#### Technique

Bandaging is started at the elbow of the below-elbow stump, and at the anterior deltoid of the above-elbow stump. It is then smoothed to the end of the stump, pulled over the end, brought back to the starting point posteriorly, and caught with the hand. When two or three of these recurrent turns have been executed over the end, they are anchored at the starting point by one loose turn around the circumference of the arm. The bandage is then brought diagonally to the end of the stump where it

<sup>1/</sup>  
1/Genevieve V. Reilly, "Pre-prosthetic Exercises for Upper Extremity Amputees," The Physical Therapy Review, (May 1949) 31-5: 183-188.



is reversed to start spiralling upward. The first turn is made very firm. Spiralling continues proximally and obliquely to the elbow or arm pit where it is anchored above the remaining joint to prevent slipping. Sometimes, it is necessary to add an extra Ace bandage over the first one for greater security. A few diagonal turns over the end and back to the starting point will prevent the first one from becoming loose and slipping (plates, 9, 10, page 19).

#### Phantom limbs

An extensive study <sup>1/</sup> has been completed recently at the University of California Medical School on painful and non painful limbs. No conclusive reasons were ascribed to the phantom limb as a result of this study, but some interesting points were brought out.

#### Painful phantom

Those parts of the phantom, which in life were endowed with the greatest skill and finest sensory pick-up, appear to be felt most. These parts are the fingers and toes and their seat of sensory origin is in the cortical area of the brain. Sensations have been described as: (1) "tingling" of the fingers when a certain portion of the stump is touched; (2) "a burning" sensation felt in the stump; (3) "phantom" limb brought on by weather, alcohol, wearing a prosthesis, or in some cases, may be present all the time. Other sensations are described as: "pressure," "gripping like a vise," or, "pounding as with a hammer." 10 to 20 per cent of all

<sup>1/</sup>Advisory Committee on Artificial Limbs, Studies Relating to Pain in the Amputee, Progress Report, Department of Engineering, Berkeley Medical School, San Francisco, California, 1952, Series 11, Issue, 23, pp. 1-116.

amputees have to face persistent, severe, and sometimes incapacitating pain. In a few cases, it has been reported that the pain went away when the prosthesis was worn. The use of an artificial limb with activity appears to have a beneficial rather than a detrimental effect on the phantom.

#### Painless phantom

Very often, the phantom limb is not painful and is felt only in certain positions or when called upon. The ordinary individual is not aware of his limbs unless some sudden movement or stimuli brings attention to it. He has a shadowy awareness. In the shadowy awareness of the amputee, he sometimes moves and feels the limb that is missing. This is interpreted to mean that the stump of the missing limb is having an abnormal sensation which makes him more aware of it than the normal limb. Many of these phantom limb sensations disappear as the date of the amputation recedes into the past.

### 2. Beneficial Modalities

#### Massage

As healing becomes complete, heavy massage can be done to start conditioning the stump for handling and pressure. Light tapping can give way to heavy tapping. Movement of the tissues in the suture line will prevent adherence of the scar to the underlying structures, prevent fibrosis, and reduce sensitivity of any nerve endings that may be exposed. This procedure should be carried out twice daily unless otherwise specified.

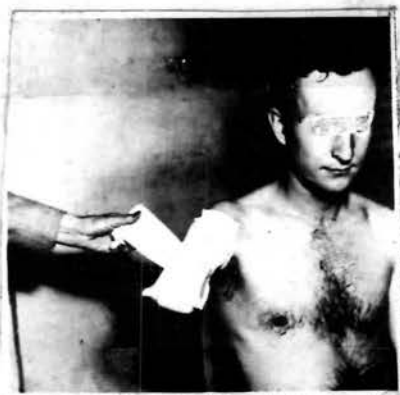

Plate 9

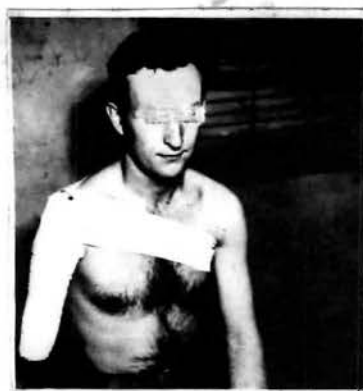

Plate 10

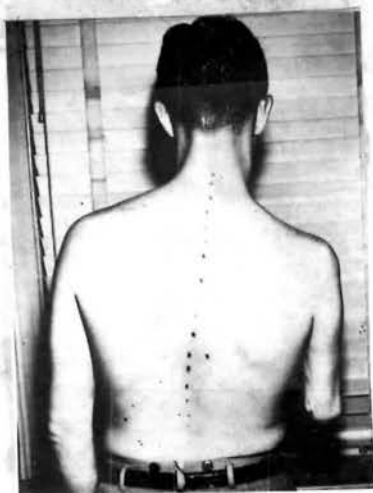

Plate 11

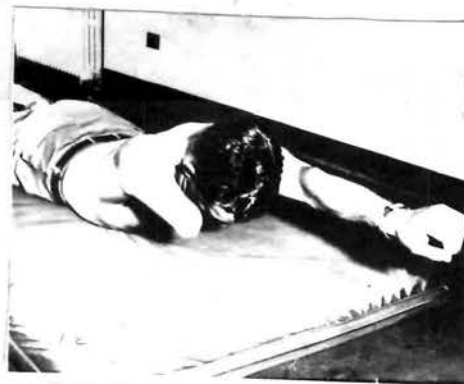


Plate 12

Plates 9 and 10, steps in bandaging the above-elbow stump. Plate 11, an above-elbow, unilateral amputee with scoliosis, plate 12, back extension exercise

### Precautions

Secondary infection in varying degrees is found in the tissues immediately adjacent to the site of the incision for some time after surgery. Great care must be exercised when stroking the stump not to come too near the region of infection, and to always keep the movement in the direction of the venous return. Contra-indications to massage are folliculitis, other infection, unexplained pain, and local areas of increased temperature in the soft tissues.

### Infra red whirlpool and hot soaks

Infra red is often given to the stump prior to massage and exercise to start peripheral circulation, to relieve soreness and stiffness in the muscles, and to promote a feeling of well being.

While the stump is being conditioned, from time to time, there may be minor complications that can be successfully treated with infra red, whirlpool, or hot soaks. Whirlpool and hot soaks should be given at a temperature of 105 degrees unless otherwise specified.

### Ultra violet irradiation and ion transfer

Ultra violet irradiation and zinc oxide ion transfer are sometimes effective means of healing sluggish and indolent appearing lesions.

Procaine ion transfer is often induced into slow healing suture areas of the stump to attempt to relieve pain.

Water cooled, ultra violet irradiation in carefully controlled doses, is often applied to excoriations on muscle tunnels for the purpose of healing and toughening the skin.

### 3. Conditioning the Stump

#### Hands and fingers

Restoration of function of the residuals of amputations about the hand and fingers is of the greatest importance. A crippled hand, free from pain, is often superior in function to a prosthetic hand. It is safe to assume that the surgeon has made every effort to save as much of the hand and fingers as possible. It now becomes the responsibility of the physical therapist and occupational therapist to restore and develop the residual function to a maximum.

Static contractions of the muscles, and cautious movement of all joints adjacent to the amputation should be initiated within a few days after surgery. When the bandages have been removed, active movement of all joints can be made more vigorous. Mild infra red, gentle massage, and movement of the suture lines and tissue around bony prominences may aid circulation, prevent adhesions, and overcome tenderness. This will also accustom the patient to the use of the remaining digits or portions of digits.

When sound healing has taken place, whirlpool or paraffin bath given before exercise will make the hand more supple for exercise. Scar areas and suture lines should be stretched and moved constantly. The value of making a fist, and strengthening opposition of residual fingers or portions that can be used for opposition must be emphasized. Occupational therapy that requires fine movements of the hand and fingers should go along with the physical therapy program. A simple prosthesis can be made that will give the amputee a working extremity if the hand

has one good digit remaining.

Below-elbow amputation stump

1/  
Initial exercises for the below-elbow amputation stump can be increased to maximum tolerance of the amputee as soon as sound healing has taken place. Heavy resistance of the DeLorme principle should be carried out whenever possible. A few motions will require manual resistance. A cuff or sling made especially for the upper extremity amputation stump is attached to the forearm and then to a cable which has been run through a pulley. With the elbow stabilized, and with graduated weights attached to the cable, the amputee performs flexion and extension of the forearm. Pronation and supination may be manually resisted. Maintaining and developing residual pronation and supination of the forearm stump must be emphasized. Early active exercise in pronation and supination may overcome cross union between the remaining sections of these two bones. The pronator teres can be developed and trained to take over the lost function of the pronator quadratus in both the long and the medium amputation stump.

It is also important that good range of motion at the humeral joint be maintained for good prosthetic control. Limitation of flexion of the forearm or humeral joint will hinder, and often prevent, the movement of the prosthesis to the mouth and chest.

1/R. Deane Aylesworth, op. cit., Section, 8.0-8.4.

### Above-elbow amputation stump

When any part of the body is lost,<sup>1/</sup> the center of gravity of the body is shifted due to the loss of weight. Consequently, the balance of the two sides of the body is upset. The weight loss is minimal in the below-elbow amputation, but in the above-elbow, unilateral amputation, the shift of the center of gravity, plus disuse atrophy of the muscles, results in greater weight loss which may cause a curvature of the spine (plate 11, page 19). Good body alignment and postural habits should be encouraged from the time of surgery as suggested previously. Back and neck extension and abdominal exercises should be added (plate 12, page 19). The extension exercises are best performed in the prone position with the arms over the head. Abdominal exercises are performed in the supine position.

Most of the biceps and triceps muscles are still intact in the long, above-elbow stump, and exercises to develop these two muscles can be accomplished by having the amputee contract the muscles strongly against manual resistance. Static contractions of the muscles can also be done several times a day. Forearm flexion is lost and, therefore, heavy resistance of the DeLorme type cannot be carried out. Internal and external rotation can also be manually resisted.

All muscles of the shoulder girdle bilaterally should be exercised against resistance. Both shoulders are needed for effective control of

<sup>1/</sup>Genevieve V. Reilly, op. cit., p. 183.

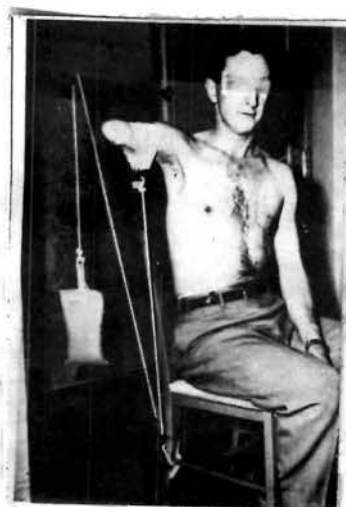

Plate 13



Plate 14



Plate 15

Resistive exercise for the following movements: Plate 13, abduction, plate 14, horizontal adduction, plate 15, serratus anterior



the harness. If there is any limitation of scapula movement on the amputated side, humeral flexion will also be limited. Flexion of the humeral joint is used for both prosthetic forearm flexion and prehension of the hand or hook in the dual control system. Extension of the humeral joint is necessary for the prosthetic elbow lock. The following motions should be performed against resistance:

Humeral motion

1. Flexion and extension
2. Medial and lateral rotation
3. Adduction and abduction (plate 13, page 24)

Shoulder motion

1. Elevation and depression
2. Scapula adduction and abduction - humerus abducted to shoulder level (plate 14, page 24)
3. Serratus anterior (plate 15, page 24)

Good musculature of both shoulders is extremely important in the short, above-elbow stump and shoulder disarticulation. Function of the prostheses is almost completely dependent on shoulder function.

#### 4. Physical Therapy for Cineplasty

##### Pre-operative

The strength of the muscle to be used for cineplasty muscle motor is very important since its magnitude is in direct proportion to the diameter of the muscle. The majority of muscles can be further developed by heavy resistance exercise. Full range of motion of the elbow and humeral joints is essential for good prosthetic control.

The following exercises are suggested if the brachio-radialis muscle is to be used for a muscle motor:

1. Flexion of the forearm on the elbow with the forearm in pronation (resistance applied near the end of the stump)
2. Flexion of the forearm on the elbow with the forearm in anatomical position
3. Pronation and supination - manual resistance
4. Static contractions of all muscles of the forearm stump

The following exercises are suggested if the biceps muscle is to be used for a muscle motor on a below-elbow stump:

1. Flexion and extension of the forearm
2. Flexion and extension of the humeral joint
3. Adduction and abduction
4. Medial and lateral rotation

#### Shoulder motion

1. Scapula adduction and abduction - humerus abducted to shoulder level
2. Elevation and depression of shoulders, bilaterally
3. Serratus anterior

The following exercises are suggested if the biceps muscle is to be used for a muscle motor on an above-elbow stump:

The amputee should perform all the exercises suggested immediately above for the biceps muscle on a below-elbow stump except flexion and extension of the forearm, and in addition:

1. Back extension - prone position
2. Abdominal strengthening - supine position

The pectoralis major should be developed to a maximum if it is to be used for a muscle motor. All shoulder motions should also be performed.

Post-operative

Post-operative physical therapy of a muscle tunnel should begin <sup>1/</sup> as soon as the dressings are removed. The biceps tendon, which was severed from its bony attachment, contracts and slackens and the muscle loses tone. That is, if the biceps has been tunnelized on a below-elbow stump. It is desirable to move this muscle at once to prevent shortening and consequent loss of tunnel excursion which would defeat the purpose of its severance. Early movement is also necessary to prevent fibrous adhesions and to keep the sense of feel or tension stimulated in the muscle. When the sutures have been removed, the muscle pin should be inserted into the tunnel (plate 16, page 28). Part of the sensory end organs, which are located in the tendons and which function to signal states of tension to the central nervous system, are lost when the tendon is severed. An external stimulus, such as exerting tension on the muscle pin, can be produced to signal states of tension to the central nervous system. The first movement of the tunnel should be a very gentle, pain-free, stretch, best performed by the amputee. If the amputee is allowed to do the first stretching, he is assured that he can stop when pain is felt. This will encourage him to stretch the muscle farther and to continue as his tolerance to tension increases. This stretching should be carried out three times a day, to the limit of his tolerance, and held for about 30 seconds.

An active contraction against resistance of the muscle pin is per-

1/R. Deane Aylesworth, Editor, op. cit., Section 10.8.2.

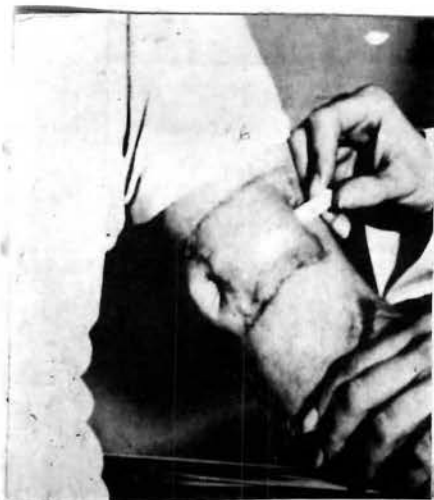

Plate 16

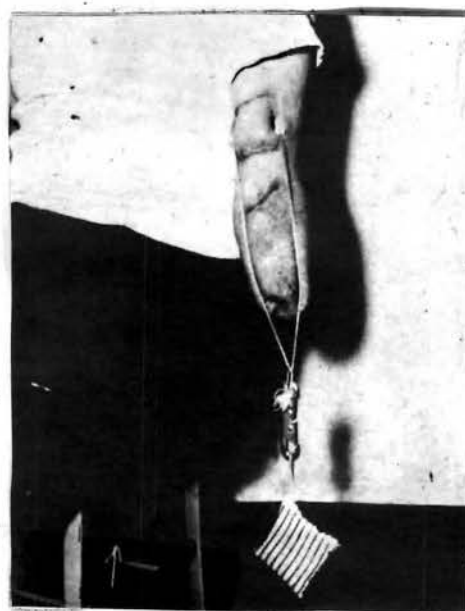


Plate 17




Plate 18

Post-operative cineplasty. Plate 16, first insertion of the tunnel Pin, plate 17, active contraction against resistance, plate 18, heavy resistance to over develop weak brachialis and brachio-radialis

formed after each stretching, and with each contraction of the biceps tunnel, the amputee voluntarily inhibits forearm flexion and supination (plate 17, page 28). When healing is complete, more vigorous stretching can be carried out and more resistance applied to the muscle pin. Bear in mind, that when the prosthesis is fitted, the tunnel is expected to pull a load from 30 to 80 pounds. It must be conditioned to a maximum. Training should be kept up until a prosthesis is fitted.

When the biceps tendon is severed, part of the power to flex the forearm is lost. The brachialis and brachio-radialis must be trained to take over the function of the biceps. Constant use, and heavy resistance (plate 18, page 28), to over-develop the power of these muscles will overcome weak flexion and supination. At the same time these muscles are preparing to take over the work of the biceps, the amputee is voluntarily dissociating forearm flexion with muscle tunnel action.

#### Care of the muscle tunnel

The muscle tunnel should be washed with mild soap and water, or swabbed with hydrogen peroxide daily and dried thoroughly. This will guard against skin burns, tenderness, chafing, and mild excoriations that sometimes appear with vigorous friction against the muscle pin. A very soft, cotton sock, through which the tunnel pin is placed before it is inserted into the tunnel, will absorb perspiration and prevent friction against the skin. A fresh sock should be applied daily. A soiled sock, or one that has not been washed properly can also cause tenderness.

## 5. Summary

A prospective amputee has many disturbing and often detrimental thoughts while he is waiting for his surgery. Whenever possible, a physical therapist should visit the patient before the surgery and explain the procedures of rehabilitation in which he is expected to participate following his amputation. This consideration will instill confidence and help to relieve his anxieties.

Immediate, post-operative measures to prevent faulty posture, contractures of the stump and surrounding joints are desirable for maximum dexterity of the prosthesis. Proper application of an Ace type bandage will aid the prevention of soft tissue swelling and aided by disuse atrophy of the stump, effective shrinkage will result which will give the desired shape. It should be applied before the amputee becomes active in the morning. It should be removed and re-applied at approximate two hour intervals.

Phantom limbs often further complicate the problems of the amputee. The phantom can be either painful or non painful which may continue throughout the life of the amputee or disappear soon after the surgery. Wearing a prosthesis often causes the phantom to disappear.

There are many beneficial modalities of physical therapy that are used with beneficial results in conditioning the stump. When used with caution, massage will improve muscle tone, prevent scar adhesions, reduce sensitivity, and restore circulatory efficiency. Infra red, whirlpool, hot soaks, ultra violet irradiation, novacain and zinc oxide ion transfer

are often used as conservative measures for the healing of minor complications that appear on the stump from time to time. Conditioning the residuals of amputations of the hand, forearm, upper arm, and shoulder is necessary for maximum dexterity of the prosthesis. The physical therapist is responsible for giving the amputee the correct progressive resistance exercises for every muscle involved in prosthetic use whether the prescription for prosthesis is to be conventional, heavy duty, or cineplasty.

Therapeutic measures for the cineplastic muscle tunnel and residuals of the severed biceps are important. Mild stretching and contractions of the tunnel with the pin inserted should begin as soon as the dressings are removed, and increased against resistance with the tolerance of the amputee. The remaining flexor muscles of the forearm must be overdeveloped to overcome weak flexion. Biceps action must be dissociated with forearm flexion.

## CHAPTER III

### PROSTHESES

#### 1. Selection

The Regional Office of The Veterans Administration, Boston, Massachusetts services approximately one hundred and fifty upper extremity amputees to five hundred lower extremity amputees. This approximate ratio is typical of upper and lower extremity amputees all over the country. It is fortunate that the number of upper extremity amputees is fewer for the problems of manufacturing an adequate prosthesis for this disability, and teaching the use of the prosthetic devices, are considerably more involved than the problems faced by the people serving the leg amputee. The recent improvements in prostheses have made the upper extremity amputee almost completely independent, but not one hundred per cent efficient. However, it is hoped that day is not too far into the future. The main question is, which prosthesis, hand, hook, or accessory units will be the most functional for the particular needs of the amputee.

As suggested previously, the physical therapist should describe the functions of the various distal devices to the amputee, however, technical information and advice should come mainly from the surgeon and the prosthetist. The final choice in every case should be made by the amp-



utee. When the amputation stump is ready for the prosthesis, it is ideal to permit the amputee to come before a rehabilitation team which is generally composed of surgeon, prosthetist, physical therapist, and/or occupational therapist, for an evaluation of his residual function and requirements in view of his education, occupation, past experiences, capacity for adjustment, and desires. The surgeon should make his prescription recommendation to the prosthetist on the basis of what each member of the team has contributed to the evaluation.

It is interesting to consider why one amputee chooses to wear a hook when another amputee chooses to wear a hand. The choice of a hook is usually an occupational one. Heavy duty, manual trades, or hobbies, that require functional reliability are better serviced by a hook. Some companies make hooks in many sizes and ranges of function. The hand is usually chosen for cosmetic appearance and light weight performance, yet a few amputees use a hand for heavy work, and some use a hook for very light work. An interchangeable hand and hook is preferable if the amputee does a variety of activities.

Since a bilateral amputee cannot conceal his disability, he must choose prosthetic appliances with which he can obtain maximum performance, regardless of appearance, in order to obtain independence. Most bilaterals choose to wear two hooks, while some wear one hook and one hand.

There are many good prostheses <sup>1/</sup> manufactured by large supplier type

---

<sup>1/</sup>The term "prostheses," used here, refers only to forearm, upper arm, and shoulder pieces.

companies as well as those made in local limb shops. Many of these prostheses have similar, worth-while features, and others have different features of advantage. Rather than to describe specific features of the various trade name prostheses, in the following pages, the writer will explain generally recommended features of the different type prostheses,<sup>1/</sup> using the various levels of amputation as the basis.

## 2. Conventional Below-Elbow Prostheses

### Prostheses for wrist disarticulation

The prosthesis prescribed for the true wrist disarticulation or removal at any point between the radio-ulnar joint and the styloid process, has the same general features. Normal wrist pronation and supination is 180 degrees, and with this type of amputation, approximately 120 degrees is retained. A single wall, plastic laminate, forearm socket, which fits the forearm stump snugly at the distal end, so that natural pronation and supination rotates the socket and hence the terminal device, is recommended. However, if the distal portion of the stump is small, a double wall socket is used which will give the desired diameter for the socket at the wrist. A very flexible elbow joint, such as leather or flexible cable, will permit natural flexion and extension of the elbow and will not interfere with pronation and supination. A triceps pad, or half arm cuff is usually adequate for socket stability. Figure-eight harness for suspension, and single control for the terminal device are sufficient for

---

<sup>1/</sup>R. Deane Aylesworth, op. cit., Section, 5.0-5.3.

this level and for almost all below-elbow prostheses.

#### Prostheses for the long amputation

Normal range of pronation and supination of the long, forearm, amputation stump is from 140 to 160 degrees and 100 to 120 degrees is retained after amputation. Since a good range of forearm motion remains in the stump, the same general features are recommended for this level of amputation prosthesis as for the wrist disarticulation prosthesis. The socket for this below-elbow arm, which is of the double wall type more often than for the wrist disarticulation, is generally made with a "screw-driver" fit distally to aid pronation and supination (plate 19, page 36).

#### Prosthesis for the medium length amputation

Natural pronation and supination of the medium length amputation stump is from 100 to 140 degrees, and retained motion is usually from 60 to 100 degrees. Since a medium length amputation varies greatly in residual function, very often, the fitted socket operated by forearm pronation and supination will not suffice. When this is the case, a rotation socket with a stump driven, step-up rotation unit added will insure full pronation and supination. An inner socket receives and stump and the rotation unit, which is fastened to this socket, rotates inside an outer shell.

The stump is usually of sufficient length to provide good socket stability with the aid of a triceps pad and figure-eight harness. In some instances, the half arm cuff may be used. A flexible or insert type hinge will permit pronation and supination and not restrict flexion of the forearm (plate 20, page 36).



Plate 19



Plate 20

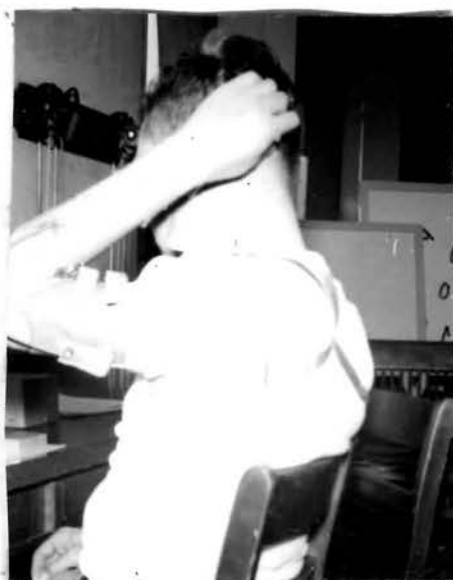

Plate 21

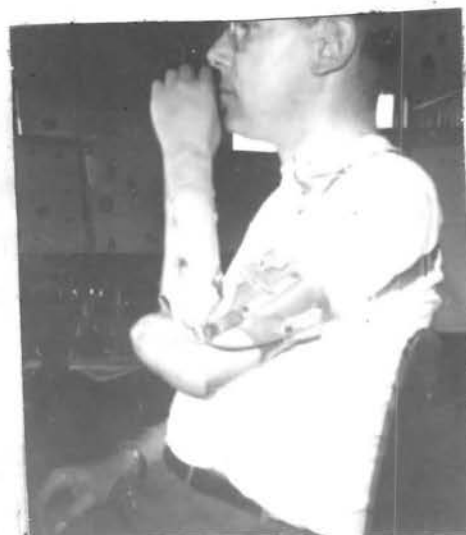

Plate 22

Below-elbow prostheses. Plate 19, rotation socket with leather inner socket and heavy duty leather saddle type harness, plate 20, medium length BE prosthesis with figure-eight harness, plate 21, short BE prosthesis showing figure-eight harness from the rear, plate 22, split socket prosthesis with step-up flexion and full arm cuff

### Prosthesis for the short amputation

Retained pronation and supination is 60 degrees or less in the short, below-elbow, amputation stump. Since the stump driven, step-up rotation unit increases pronation and supination by a ratio of only 2.3 to 1, it does not add enough function to the residual motion to make this a practical prescription. Therefore, rotation of the terminal device of the short stump prosthesis is made possible by a manual wrist rotation unit of which there are two types. If the stump is well shaped, a single wall, forearm socket with metal side or insert hinges attached to a half arm cuff are generally prescribed. A double wall socket is prescribed if the stump has irregularities of shape and size (plate 21, page 36).

### Prosthesis for the very short amputation

A very short, below-elbow, amputation stump provides poor flexion for the prosthetic forearm. Normal pronation and supination are lost for practical purposes. A split socket type prosthesis (plate 22, page 36) is often recommended to supplement this level. It contains an inner wall or socket, made to fit the individual requirements of the stump, and an outer wall or socket of the normal length and diameter. The inner socket continues proximally over the olecranon for better stability, and is not attached to the outer socket except at the elbow hinges. If the natural motion can flex the prosthetic forearm to 90 degrees, with the addition of polycentric elbow hinges, the prosthetic forearm can be flexed to 135 degrees. This is called a step-up flexion unit. It is designed so that the greatest weight can be borne on the arm after passing the

90 degree angle. A full upper arm cuff is necessary for stability. If forearm flexion is weak, dual control may be advised.

#### Heavy duty below-elbow prostheses

The heavy duty, below-elbow arm differs from the conventional arm in the type of harness used and the fabrication of the socket. A full arm cuff and above-elbow type harness provides greater stability and more points for weight distribution. If a plastic socket is made, more layers of stockinette and glass cloth are added to make the socket more durable than the conventional arm. Metal side joints are essential for stability. These permit full flexion but no pronation and supination.

### 3. Above-elbow Conventional Prostheses

Prostheses have been designed to supplement the residual function of the elbow disarticulation, standard, or long length, short, and shoulder disarticulation. Function and leverage diminishes with each higher level of amputation. Provision must be made in the prosthesis for the controls of the hand or hook, rotation of the terminal device, elbow function, and in many cases, some motion of the humeral joint. Performance depends almost entirely on proper harnessing.

#### Prosthesis for the elbow disarticulation

If the amputation is through the elbow, through the epicondyles, or just above the epicondyles, the prosthesis for each have the same features. This has long been a controversial level of upper extremity amputation since the epicondyles create a special prosthetic problem of fitting. Most prostheses designed for this level have the elbow unit set

lower than the natural elbow which requires a shortened forearm piece to bring the prosthetic arm into sizing with the natural arm. Recently, side locking, elbow hinges have been developed which promises to eliminate the above mentioned prosthetic problem. The elbow hinge is capable of great stability and can be locked at the will of the amputee. (To be explained later in the section on cineplasty). Harness and controls for this level of amputation prosthesis depend on the degree of disability as with other above-elbow levels, although dual control and "figure-eight harness with modifications," is the terminology now generally used in prescription. The figure-eight pattern is modified according to the needs of the amputee.

#### Prosthesis for the standard or long amputation

As stated earlier, a standard or long amputation stump is from 50 to 90 per cent of acromion to epicondyle length. All stumps of 50 per cent length may not possess sufficient function to operate the prosthesis (plates 23, 24, page 40) designed for this level. Doubtful cases usually have the Campbell Modulus Formula  $\frac{1}{L}$  applied to determine if function is sufficient. That is, humeral length from the axilla to the end, divided by anterior-posterior diameter of the stump at the axilla. In order to properly operate the standard prosthesis, a modulus greater than 1.33 should be found. If a modulus less than 1.33 is found, the amputee is usually given a prosthesis prescription with features that

1/R. Deane Aylesworth, op. cit., Section, 6.1.1.





Plate 23



Plate 24

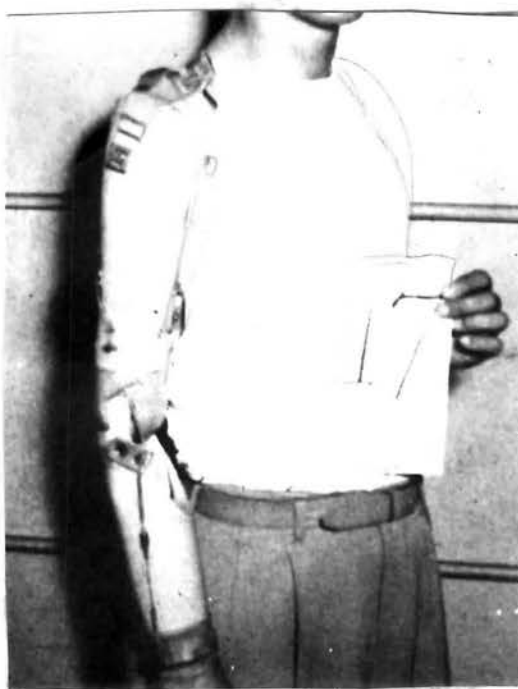

Plate 25

Above-elbow prostheses. Plates 23, 24, front and back views of the standard or long AE prosthesis with webbing shoulder saddle harness, plate 25, prosthesis for the short AE amputation stump



supplement residual function of a short stump. Forearm shells for all above-elbow prostheses can be purchased in lengths from six to  $10\frac{1}{2}$  inches if the desired specifications are given, or they may also be made in local limb shops. The purchased shell is fitted with a manual preposition, rotation unit which serves as a disconnect between the forearm socket and the terminal device and/or the accessory wrist unit. The elbow unit, which is purchased separately or as a part of the prefabricated forearm piece, has full lockable flexion and the upper arm portion is either made with a single or double wall socket depending on the size and condition of the stump. A friction turntable attached to the elbow unit permits the forearm to be rotated into proper position in front of the body. Exceptions to the figure-eight harness with modifications and dual control may be leather or webbing saddle harness and triple control.

#### Prosthesis for the short above-elbow amputation

The prosthesis for the short, above-elbow amputation (plate 25, page 40) is only slightly different from the prosthesis designed for the standard or long length. The upper arm piece contains a double wall for most cases. The inner wall fits the stump snugly and the outer wall continues down to the elbow of the normal diameter and size. Both walls are continued higher on the deltoid to compensate for the loss of leverage. Elbow lock and control system are the usual above-elbow prescription depending on the needs and desire of the amputee.

### Prostheses for the shoulder disarticulation

The same prosthesis is prescribed when the humerus has been removed at the acromial joint, when the head of the humerus is still intact, and when the arm, plus the scapula, have been completely removed. There may be minor variations to fit the individual case, but by and large, the features are the same. There is no stump leverage to aid the control of the prosthesis. Shoulder function is all that remains on the amputated side. Prosthetic function is limited but good cosmetic appearance is achieved.

The prosthesis has the usual forearm shell, an upper arm piece and shoulder piece, which may be made in one piece or in sectional plates. There may be an extra hinge between the upper arm piece and the shoulder socket so that the arm will swing out to permit clothing. The shoulder piece is a double wall, and made to fit the shoulder perfectly. Comfort and performance depend a great deal on the fit of this portion. The dual type of control is used to operate the hand/or hook and flexion of the forearm. These two movements are activated by the shoulder shrug instead of flexion. Elbow lock is activated by a nudge control placed on the shoulder piece and operated by a nudge of the chin or by touch of the other hand. Harness for the shoulder disarticulation may have many modifications to provide good stability for the prosthesis and positive location points for the shrug control.

### Heavy duty above-elbow prostheses

Heavy duty arms are not prescribed for the above-elbow amputation

very often since the above-elbow amputee seldom does heavy work. Heavy duty means that the prosthesis is made to withstand a great deal of strain, and if it is a plastic laminate socket, it simply means the addition of extra layers of glass cloth and stockinette. Shoulder saddle type of harness would probably be prescribed to provide greater stability.

#### 4. Hands, Hooks

##### Hands

An amputee looks for two things in an artificial hand. First, he looks for form and coloring that resembles his natural hand, and second, he looks for a useful grasp.

In recent years, there has been an improvement in the appearance of the hand which has a tremendous psychological effect on the amputee. The improvement is a Vinyl-Resin plastic glove that resembles the natural hand in skin coloring and texture. There are six Caucasian and six Negroid shades from which to choose. Since the desire to resemble a man with no disability is stronger than the desire for functional reliability, very often, this will be the deciding factor in making a choice of a terminal device if he cannot have both a hand and a hook.

Hands are usually made from plywood, combinations of metal and rubber, or an intricate system of coiled springs. Some are made of very heavy steel for hard wear, and some are made of exceptionally light weight material, which are worn for cosmetic effect only. These hands are usually covered with a brown or grey leather glove that is conspicuous and often interferes with function of the hand.

APRL (Army Prosthetic Laboratory) manufactures a hand that is of medium weight, has a useful grasp, and can stand fairly heavy duty. The plastic glove (mentioned on page 43) molds smoothly to the contours of the hand. There is no interference with function. The APRL hand is superior to other hands but is not as functionally reliable as a hook. This fact should be impressed upon the amputee if he cannot have both a hand and a hook. Where this hand leaves a lot to be desired, it is the first really functional hand to be made. New and better hands are being tested in the laboratories now and should be available before too long.

#### Hooks

Hooks are made of strong metal consisting of two prongs, in various shapes, and having plain metal or rubber grasping surfaces.

#### Voluntary opening hands and hooks<sup>1/</sup>

Of the many types of hands and hooks, generally speaking, they are either voluntarily opened or closed. The voluntary opening hands and hooks are opened by a voluntary movement of the shoulder. They are closed by tension exerted on the hook fingers by rubber bands, or with the aid of the other hand, or by springs in the hand. Grasp of the hook or hand cannot be as finely controlled with this method as with the voluntary closing method. The voluntary opening hooks are either single load or two load. The two load provides grasp by an enclosed spring mechanism in a case, and by a lever on the case, a three or six pound

<sup>1/</sup>R. Deane Aylesworth, op. cit., Section, 4.2.

hook tip grasp may be selected. Maximum grasp width is  $3\frac{1}{2}$  inches.

#### Voluntary closing hands and hooks

The voluntary closing hook (plate 26, page 48) can be closed at will and the finger tip grasp varied from less than an ounce to a grasp greater than the grasp of the normal hand. The finger tip surfaces are rubber lined for finer grasp. The case on this hook is lyre shaped and contains a three way switch on the center side which permits a  $1\frac{1}{2}$  inch opening, three inch opening, and free wheeling. Free wheeling permits rapid opening and closing without locking. Automatic locking takes place at the other two prehension levels of force.

The voluntary closing hand (plate 26, page 48) is operated in the same manner as the voluntary closing hook. Its light weight is due to the fact that it is shaped from aluminum. The coiled springs for finger control are inside. The thumb has a two and three fourths and one and three fourths inch openings which must be prepositioned manually. The index and middle fingers are the only two fingers that are voluntarily closed. These fingers move only at the metacarpel-phalangeal joints and are curved slightly to resemble the natural flexed position of the fingers. The ring and little fingers are ductile. Thumb tip length is the same as the normal hand but the rest of the hand is smaller than the normal hand. An artificial hand of the same size as the normal hand appears to be larger than the normal hand.

The portrait artist who created the 12 shades of color for the cosmetic glove says that most skin types will fall within this number.

Now, it is felt that the glove should be matched more closely to the skin coloring of the amputee at the time of prescription. The normal hand changes color with movement, while the prosthetic hand remains the same color which should be taken into consideration. The glove exhibits no change when exposed to weather, oils and grease, but will react to paint and varnish thinners, shoe polish, ball-point ink, stains and dyes. The glove also tears easily but is easily replaced by a prosthetist.

#### Partial hands

Partial hands, complete hands, and forearms are made from Vinyl-Resin with the same skin matching as the glove. This plastic hand has flexible metal frames imbedded in the fingers permitting them to be bent in any position desired. There is no voluntary motion, but it is possible to perform light duties of touch and grip, such as hold a telephone or play cards.

If only part of a hand or finger is missing, a partial replacement can be made which serves as opposition to the normal fingers. Function is limited, but it gives a more normal appearance to the hand.

A functional appliance, called a post can be made for the residuals of a partial hand that can take heavy duty and gives comfortable opposition to the remaining portions. If a thumb is missing, the remaining fingers are almost useless for grasp since there is no opposition for them. If all the fingers except the thumb are lost, the same problem exists.

## 5. Fabrication of Upper Extremity Prostheses

### Materials

Materials used in making upper extremity prostheses are mainly wood, leather, plastic, or combinations of these. Leather has been used with great success because it can be handled with ease, becomes pliable with use, and has good resiliency against the skin. The chief objections to the use of leather are: it is heavy, gives off an odor, stains the clothing, and sometimes chafes the skin. Wood is not used as much as leather because it forms a bulky, thick shell. Many prosthetists are still using wood and leather, and the limbs are preferred by many amputees. The advantages of using plastic, or combinations of plastic and some other material are so great that this material is taking the lead in modern limb making. Plastic can be handled in the local limb shops and it makes a very light weight shell that will not stain clothing, has no odor, cleans easily, and can be made to withstand heavy or light performance. The chief objection to its use is its hardness against the skin.

### Outline of steps in making a single wall plastic socket<sup>1/\*</sup>

1. Dimensions of the stump are measured carefully and bony landmarks indicated
2. A primary wrap is made from plaster of Paris
3. A master mold is made
4. A check socket is made
5. Elbow centers are located

<sup>1</sup>/R. Deane Aylesworth, op. cit., Section, 5.0.

\* These steps are not intended as complete instructions.




Plate 26



Plate 27

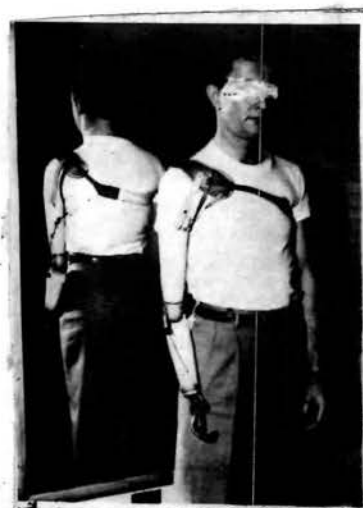

Plate 28

Hand hook and controls. Plate 26, voluntary closing hand and hook, plate 27, AE figure-eight harness, plate 28, AE leather shoulder saddle harness with shrug control



6. A piece of stockinette twice the length of the check socket is pulled tightly over the check socket and tied in the groove under the wrist unit. The other end is tied around the metal tube. The remaining portion of stockinette is brought back over the check socket and tied in a similar manner
7. If metal elbow joints are to be used, they are applied at this time
8. Applications of glass cloth are added to areas that need reinforcement
9. Another piece of stockinette of the same dimensions as the first sheet is added and tied in the same manner
10. A sheet of PolyVinyl Alcohol plastic is added and one end tied
11. Resin laminate is poured into the open end of the plastic bag and the resin is worked down into the stockinette layers
12. The socket with the plastic laminations is placed into an oven and heated at different temperatures for a period of time and then it is ready for refinishing

Steps in the fabrication of a double wall socket, split socket, and shoulder socket are similar to the steps in fabrication of a single wall socket. Less time is required for the prosthetist to produce a plastic socket for the amputee than a wood or leather socket. Fewer fittings are required for the amputee since a check socket is made.

## 6. Harness and Control Systems

There is much truth in the saying, "A prosthesis is as good as its harness." As the level of amputation becomes higher, function of the artificial limb depends more and more on proper harnessing. Harness serves as suspension, but its most important function is to provide adequate points for the controls of the prosthesis. Shoulder harness must be fitted to the amputee. If the conventional method of harness does not provide adequate controls for the particular needs of the amputee, a good prosthetist will vary the method to suit the needs. Attachment points for control cables are mounted on the harness as it is made. Cable

retainers, and forearm levers are installed and the control apparatus assembled.

#### Materials used for harness and control cables

The types of harness used by most prosthetists are: cloth webbing, Vinyon tape webbing, elastic tape, nylon, and leather. Control cables are made of leather and stainless wire. There are individual differences in the methods of harnessing among the different prosthetists even when the same method is supposedly being used. Harness is made to give the best prosthetic performance by actual wear and test.

#### Conventional unilateral and bilateral below-elbow harness

As a general rule, below-elbow arms are suspended <sup>1/</sup> from figure-eight harness (plate 20, page 36). A triceps pad, half or full arm cuff placed above the elbow serves as anchorage for the harness and provides stability for the socket.

One inch harness webbing is used for the figure-eight, and is started at the anterior portion of the delto-pectoral triangle on the amputated side. The webbing is continued over the shoulder, (1) across the back, (2) under the opposite axilla, (3) brought up in front, (4) over the shoulder to the back where it crosses the first strap at approximately the 7th cervical vertebra. Sufficient webbing is left to permit a control attachment strap three inches from the crossing, and a buckle retainer and billet for the control cable adjustment. An inverted Y suspensor strap is attached to the front support strap and the other two

1/R. Deane Aylesworth, op. cit., Section, 6.7.2 - 6.7.5.

ends of the Y are attached to the upper arm cuff. Major load points with harness are shoulder amputated side, shoulder sound side, and axilla sound side. A single control cord for the terminal device is all that is necessary.

Bilateral, figure-eight harness is almost a duplication of the unilateral, figure-eight harness. Both axilla loops are left out, and an elastic back strap is added to prevent the control cables from slipping up on the shoulders and to give more power to the control of the terminal devices.

#### Heavy duty below-elbow harness

Heavy duty, below-elbow harness is a modification of the above-elbow leather saddle (plate 19, page 36), or webbing saddle type. A full arm cuff is usually necessary for added stability of the socket, and instead of the inverted Y suspensor buckles used on the conventional type, medial and lateral D rings are used. The medial and lateral loop suspensors used with the above-elbow arm are not necessary. The webbing to which the control cord is attached in back, joins the continued chest strap as it leaves the axilla at approximately the 10th thoracic vertebra. The saddle provides shoulder and chest expansion needed for better weight bearing.

#### Above-elbow suspension and control

Harness for above-elbow suspension and control is sometimes more complicated than below-elbow harness because functional movements and socket stability necessarily depend more on harnessing. The type of har-

ness usually depends on whether dual or triple control is to be installed, although the trend is toward the use of dual control and figure-eight harness with modifications (plate 27, page 48).

#### Leather dual control

This harness consists of four basic pieces: (1) shoulder saddle, which is made from six to eight ounce strap leather lined with horsehide, (2) lateral loop suspensor, (3) chest strap of one to 1½ inch webbing and (4) front elastic strap. The shoulder saddle is shaped to fit the shoulder region front and back on the amputated side. The chest strap is attached to the saddle front, (1) passed diagonally under the axilla of the opposite arm, (2) across the back to the shoulder saddle on the amputated side. Additional pieces are the take up strap, elastic suspensor, elbow lock billet, and attachment strap. Major load points are shoulder, amputated side, and axilla, sound side.

#### Leather shoulder saddle triple control

The shoulder saddle for triple control harness is shaped more triangularly than the shoulder saddle for dual control. The insertion of shrug control in the back portion of the chest strap (plate 28, page 48), and a separate control for forearm flexion, distinguishes this type from the dual, leather saddle, control harness.

#### Webbing shoulder saddle for dual control

Webbing saddle harness contains all the features of the leather saddle harness except that the saddle is made up of a series of webbing straps. This consists of a base strap which is the chest strap

continued over the shoulder and made of  $1\frac{1}{2}$  inch webbing. Two over the shoulder straps are attached to the chest strap which gives a saddle appearance (plates, 23, 24, page 40).

## 7. Minimum Standard of Performance for Upper Extremity Prostheses

When an amputee receives his prosthesis, it should be checked for mechanical performance by his therapist. The following standards are used at UCLA (University of California, Los Angeles).

### Below-elbow

The tests are planned to cover the functional characteristics of the prosthetic arm and the parts to be tested are, terminal device, accessory units (not primarily) forearm socket, arm cuff, harness, and control system (see plate 29, page 57 for scales used in giving the following tests).

1. Active forearm flexion with the prosthesis should be as great as forearm flexion without the prosthesis.
2. With the prosthesis, an amputation stump of 50 per cent length or more, pronation and supination should be  $\frac{1}{2}$  that of active forearm pronation and supination. Amputation stumps of less than 50 per cent length have little or no usable pronation and supination.
3. With the forearm flexed to 90 degrees, terminal device taped closed, the amputee should be able to resist a force of at least three pounds before the forearm begins to slip below 90 degrees. Force should be applied 12 inches from the elbow pin and the pull

directed straight downward.

4. The efficiency of the control system can be determined by measuring the force required to open (or close) the terminal device at two points and applying the following formula: force measured at the terminal device divided by the force measured through the cable. (a) With the cable disconnected, the measuring scale is applied to the thumb of the hook, in the half open position or the cable of the hand, and the force is read as the hook or hand is opened (or closed). (b) Reconnect the cable to the terminal device. Apply scale to the T-bar of the control cable and again read the force. The efficiency should be greater than 70 per cent.
5. The amputee should be able to control the arm in rotation with the forearm flexed to 90 degrees and abducted about 60 degrees.
6. A 50 pound pull straight downward on the terminal device should not cause failure of any part of the prosthesis or harness or a slippage of the prosthesis of not more than one inch.
7. With the elbow flexed to 90 degrees, no discomfort or pain should be caused when a strong axial push is applied to the elbow.
8. The amputee should be able to actively open or close the terminal device 70 per cent the full amount with the terminal device at or near the mouth or fly.
9. The amputee should be able to obtain full opening and closing of the terminal device with the elbow flexed at 90 degrees.

Above-elbow

A minimum standard of prosthetic performance for both unilateral and bilateral, above-elbow amputees. These tests were designed primarily for the standard length amputation stump. The short, above-elbow amputee cannot be expected to perform all these motions. The parts to be tested are the terminal device, forearm socket, elbow lock, upper arm piece, harness and any accessory units that may be included although the tests were not designed primarily for accessory units.

1. The range of stump motion with the prosthesis should be:
  - Humeral flexion - 90 degrees
  - Humeral extension - 30 degrees
  - Arm abduction - 90 degrees
  - Arm rotation - 30 degrees
2. Humeral flexion required to flex the prosthetic forearm through complete range of flexion (135 degrees) should not exceed 45 degrees.
3. With the forearm flexed to 90 degrees and the arm section fixed, the force required to further flex the forearm should not exceed 10 pounds.
4. With the forearm flexed to 90 degrees, elbow unlocked, terminal device taped closed, the amputee should be able to resist a force of at least three pounds before the forearm begins to slip below 90 degrees. Force should be placed 12 inches from the elbow pin.



5. The efficiency of the control system can be determined by measuring the force required to open (or close) the terminal device at two points and then applying this formula: Force measured at the terminal device, divided by, force measured through the cable. (a) With the cable disconnected, the measuring scale is applied to the thumb of the hook, in the half open position or the cable of the hand, and the force is read as the hook or hand is opened. (b) With the cable connected, the scale is applied to the T-bar of the control cable and the scale force is read as the hook or hand is opened. The efficiency should be greater than 50 per cent.
6. The amputee should be able to obtain full opening or closing of the terminal device with the elbow flexed and locked at 90 degrees.
7. The amputee should be able to actively open or close the terminal device  $\frac{1}{2}$  the full amount with the device near the mouth and near the fly.
8. The prosthetic arm should swing in a natural manner without involuntary locking when the amputee is walking.
9. The amputee should be able to lock the elbow with the forearm flexed to 90 degrees without moving the terminal device more than six inches from the original position.
10. He should be able to control the arm in rotation with the forearm flexed and locked at 90 degrees and abducted about 60 degrees.





Plate 29

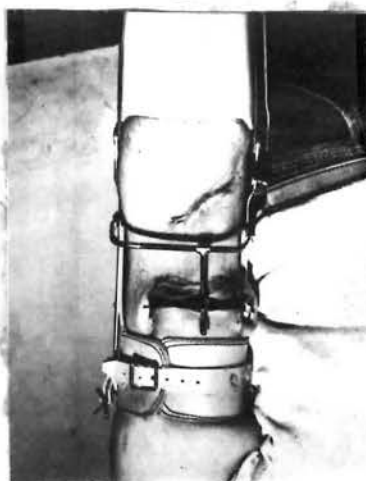


Plate 30

Testing scales and a cineplastic prosthesis. Plate 29, scales used in testing mechanical performance of prostheses, plate 30, a biceps cineplasty on a BE amputation stump with prosthesis (Note the scar on the forearm where the insertion of the biceps was severed)

11. He should be able to withstand a two pound pull in both lateral and medial direction with the elbow flexed to 90 degrees, the turntable tightened to a two pound torque and the scale inserted 12 inches from the elbow pin.
12. A 50 pound pull on the terminal device straight downward should not cause failure of any part of the prosthesis or harness or a slippage of the prosthesis of more than one inch.
13. No discomfort or pain should be caused when the amputee supports his weight on the forearm which is flexed to 90 degrees and is resting on a support.

#### 8. Cineplasty

A short time ago, a research program for cineplasty was carried out at UCLA in cooperation with other installations of research. During this study, a system for checking a below-elbow biceps muscle tunnel was worked out for the purpose of establishing a norm or standard of performance for consequent fitting and harnessing. Since then, similar research has been done with cinetized biceps on above-elbow amputation stumps. Fitting and harnessing are carried out in a prescribed manner unless strength and excursion of the muscle tunnel does not meet the requirements, and in which case, the methods are modified to suit the individual needs.

Minimum performance for the voluntary closing hook <sup>1/</sup> on a below-elbow biceps tunnel is 6.9 lbs. of prehension force at 0.5 inch open-

1/R. Deane Aylesworth, op. cit., Section, 10.2.2.

\*  
ing. The voluntary closing hook control system is assembled with the hook in the half open position unless the muscle tunnel is very strong, and then the hook is placed in the full open position. Minimum performance for a voluntary opening hook starting from the half open position is 7.0 lbs. of prehension force through 1.3 inches of opening. Minimum performance for a voluntary closing hand is 3.9 lbs. at 0.5 inch opening. Finger excursion is 1.25 inches starting from full open position of the hand.

Harnessing a muscle tunnel is planned so that the prehension force does not fall below an acceptable minimum. An adjustable control cable is provided to keep the slack out of the control system which often occurs as excursion of the tunnel increases with use.

Strength and excursion of muscle tunnels vary greatly. The average strength and excursion of biceps muscle tunnels on a group of below-elbow amputees at Walter Reed General Hospital was 73 lbs. and 2.6 inches. Average strength and excursion on a group of above-elbow amputees was 57½ lbs. and 1.7 inches. Average strength and excursion of another group of amputees having pectoral tunnels was 68 lbs. and 3¼ inches.

The plastic laminate, forearm socket usually prescribed for the conventional, upper extremity prosthesis can be used for the upper extremity cineplasty. There may be modifications to suit the level and peculiarities of each amputation stump. Accessory units are the same as those used with the conventional prosthesis. Only the voluntary closing type of hand and

\*Opening means hook or hand opening.

Only the voluntary closing type of hand and hook are used for cineplasty at Walter Reed Hospital. Both the voluntary opening and voluntary closing types of hook and hand are used at UCLA. Harness for cineplasty is minimal. Condyle cuffs of various sizes and shapes are used to provide stability for the socket. The ox bow type of tunnel pin made of reinforced, acrylic-resin, over a metal core, has been found to be the best shape and material for the biceps tunnel pin because it creates less friction and prevents lateral slippage. Pectoral tunnel pins made in the shape of a question mark have been found to be the most satisfactory. For a better fit of the tunnel pin, a wax impression is made of the tunnel in the contracted phase.

The following prescribed prostheses <sup>1/</sup> for cinetized muscles on various levels of amputation have been used at Walter Reed Hospital.

Prosthesis for trans-carpel disarticulation with cinetized biceps

A socket or cup is made to fit the carpal stump very accurately and attached to the proximal portion of the prosthetic hand, and this in turn is linked through a hinge mechanism to an open cuff wrist to permit free flexion and extension of the hand at the wrist. The forearm socket is made of plastic laminate, which extends from the wrist proximally to near the junction of the middle and upper third of the forearm. If a hook is used, the forearm socket is flattened at the distal end as with the wrist disarticulation prosthesis.

<sup>1/</sup>Spittler, August W. Col., M. C., and Lieutenant Colonel Maurice J. Fletcher, M. S. C., op. cit., pp. 378-394.

The voluntary closing hand or hook must be modified to make room for the carpal socket and is laminated to the socket. Other fittings include the usual below-elbow, biceps fittings which will be described later in "Prosthesis for the medium to long, below-elbow amputation with cinetized biceps."

As with all cineplasty, the hand or hook control cable is attached to an equalizer sheave, which is in turn connected to a cable having its two end points secured to a tunnel pin and inserted through the cinetized muscle. With a contraction of the cinetized muscle, the force is transmitted to the hook or hand which closes it (plate 30, page 57).

#### Prosthesis for the disarticulation at the wrist with cinetized biceps

This level of amputation is easier to fit with good prosthetic controls than some of the other levels of amputation. The forearm socket is plastic laminate, which is made with a screw-driver fit at the distal end to permit natural pronation and supination of the forearm. The forearm socket is the usual length for the below-elbow, biceps cineplasty and all other fittings are the same. The hook or hand may be laminated into the socket to give the desired length to the limb, or they may be made on the interchangeable plan.

#### Prosthesis for the medium to long below-elbow amputation with cinetized biceps

The majority of below-elbow biceps cineplasties are done on medium to long amputation stumps. The forearm socket is plastic laminate with an interchangeable voluntary closing hand and hook, and an F. M. wrist disconnect. Wrist rotation may be carried out passively, or a step-up

rotation unit may be added if there is adequate residual pronation and supination. A wrist flexion unit may or may not be used. Other pieces of equipment which are considered fairly standard for the below-elbow, biceps prosthesis are: cable disconnect and extensor, flexible control hing, leather (nylon coated) condyle cuff, ox bow plastic tunnel pin, stainless cable and housing, and sheave type cable equalizer.

Prosthesis for the short below-elbow amputation with cinetized biceps

The cinetized biceps on a short, below-elbow amputation stump presents similar prosthetic problems to an arm of this length that is fitted with a conventional prosthesis. The short, forearm stump is usually not capable of flexing a prosthetic arm through complete range of motion, but with the addition of polycentric elbow joints, complete range of motion is made possible. When polycentric joints are not indicated, side hinges with alternator and holdout locks are used. The prosthesis has the usual plastic laminate, forearm socket, which contains an inner socket that fits the small stump perfectly and swings free of the outer socket. The use of an elbow hinge necessitates the use of a modified, above-elbow cut-out socket, or semi-open above-elbow cuff which also serves as an attachment for an inverted Y suspensor which in turn is attached to figure-eight harness. The use of harness provides a control for the additional forearm lift and elbow lock, plus greater stability for the socket. Other fittings are the usual pieces described earlier.

### Disarticulation at the elbow with cinetized biceps

At Walter Reed Hospital the elbow portion is not lowered in a disarticulation prosthesis. Instead, the APRL side locking hinges are used. The condyles at the elbow give additional stability and prevent rotation of the upper arm socket. An over the shoulder strap actuates the forearm flexion cable and elbow lock cable which are one and the same. When force is exerted on the forearm flexion, the force is also exerted on the elbow locking mechanism causing the elbow to unlock during forearm flexion, and when flexion is relaxed, the elbow automatically locks in that position. To prevent locking of the elbow when the arm is lowered, it is necessary to maintain a slight back pressure on the forearm flexion control cable. Other fittings are the usual type.

### Prosthesis for long above-elbow amputation with cinetized biceps

The long, above-elbow stump is hard to fit, for the large opening necessary in the upper arm piece for the projection of the biceps muscle creates a problem of stability. The greater portion of the load is thrown on the distal portion of the stump. The prescription is the above-elbow type which is: plastic laminate forearm piece, modified Hosmer or Model C Northrop elbow, or side locking hinges and alternator, an over the shoulder strap to operate the elbow lock, and nylon figure-eight harness. Other fittings are those described previously for the below-elbow, cineplasty prostheses.

### Prostheses for the medium above-elbow amputation with cinetized pectoral

The pectoralis major muscle is used as the source of prehension force



on amputation stumps shorter than the long, above-elbow. The forearm, hand, and hook, for this prosthesis are the usual type. The upper arm piece is plastic laminate, with an inner socket, which must be fitted with great care. The tunnel pin is shaped like a question mark instead of the ox bow type. The angle of pull from the tunnel pin causes the upper arm piece and the fleshy part of the stump to rotate about the bone. Careful selection of reactor points on the upper arm socket, and careful harnessing of the forearm flexion control and shoulder strap to oppose the force exerted by the tunnel, will counteract the rotational force induced into the arm. The forearm lift may be an above-elbow polycentric or modifications thereof. The harness is nylon figure-eight with modifications.

Prosthesis for the short above-elbow amputation with cinetized pectoral

An attempt is made to use the residual forces about the humeral joint to aid the control of the prosthesis. The upper arm piece, which is plastic laminate, contains an inner socket which is joined to a plastic laminate shoulder piece by flexible hinges to permit full range of humeral motion. The reaction point can be placed on the collar and stabilized on the body by an under arm chest strap (nylon coated), attached posteriorly to the forearm lift cable, and anteriorly to a shoulder saddle through a Y strap. The upper arm piece contains a turntable above the elbow as with the conventional arm. The remaining equipment is the usual prosthesis prescription described earlier for above-elbow cineplasties.



### Prosthesis for amputations about the shoulder with cinetized pectoral

There is little usable residual motion in a high amputation or shoulder disarticulation, therefore, the shoulder cap and upper arm piece are fused. It is stabilized on the body by a chest strap which is the source or force used to control forearm flexion and elbow lock control. The rest of the prescription is standard.

### 11. Summary

Fabrication of an adequate prosthesis for an upper extremity amputee, and teaching the use of the prosthesis is not a simple procedure. It is ideal to first expose the amputee to an evaluating team to receive the best technical advice and hence, prescription for a prosthesis that will most nearly serve his needs. Prescriptions for above- and below-elbow prostheses are termed, conventional and heavy duty. Conventional prescriptions for the wrist disarticulation and removal in that area, generally speaking, have double wall, sockets that are rotated with the natural pronation and supination of the arm. The medium length, below-elbow arm may require a step-up rotation unit added to the socket to ensure full pronation and supination. Upper arm cuffs, elbow hinges, harness and controls are flexible and simply constructed for arms below the level of short, below-elbow amputation. Prostheses for the short, and very short, below-elbow arms usually require a double wall, or split socket type of prosthesis. Rigid or step-up hinges, plus full, upper arm cuffs are necessary. Heavy duty prostheses mean that the socket is made to withstand heavier wear.

Conventional prostheses are prescribed for the elbow disarticulation, standard length, the short, and regions about the shoulder. The elbow disarticulation may require a shortened forearm to facilitate the elbow unit in the upper arm piece which is lowered to provide for the flare of the condyles. If the new side locking hinges are used, it is not necessary to lower the elbow unit. The upper arm piece contains a turntable which rotates the arm into working position in front of the body. The shoulder socket may or may not be made a part of the upper arm piece for the shoulder disarticulation. A nudge control operates the elbow lock. Dual control and figure-eight harness with modifications are used with most all above-elbow prostheses.

Hands and hooks are either voluntarily opened or closed. APRIL puts out a very good voluntary opening hand and hook. The Sierra two load hook is considered the best voluntary closing hook.

Materials used in making sockets are mainly wood, leather, and plastic. Plastic is the latest material to be used and is fast becoming the leading material in modern limb making. Harness is made from cloth webbing, Vinyon tape webbing, elastic and Nylon. The harness is made up to give the best prosthetic performance by actual wear. When the amputee receives his prosthesis, it should be checked for mechanical efficiency, and any deficiencies should be reported to the limb maker. At Walter Reed Hospital, prostheses for all upper extremity cineplasties are made from plastic laminate, and the terminal devices are the voluntary closing type. The cinetized biceps muscle is used as the prehension force

for all levels of amputation up to and including the long, above-elbow type. The pectoral muscle is used as the prehension force above this level. Modified elbow units, side locking hinges and modified upper arm pieces are standard pieces of equipment for levels of amputation above the elbow. Modified figure-eight harness, made of Nylon, is used with all cineplasties.

## CHAPTER IV

### TRAINING

The extent of training of the normal hand and the extent of training the prosthetic hand depends largely on the inclination of the amputee. However, the normal hand assumes all one handed skills, and therefore becomes the leader, and the prosthetic hand becomes the assistant with the majority of amputees. A few amputees are so decidedly major handed that single-handed performance is more easily acquired with the prosthetic hand than to transfer these tasks to the normal hand.

Training should begin as soon as the amputee receives his prosthesis in order to make this limb a part of his daily living as soon as possible. The therapist should check every part of the prosthesis while the amputee is learning the use of it and inform the prosthetist of mechanical defects or good performance.

#### Psychological aspects of training

When a therapist receives an amputee for training, her first consideration is to create a harmonious and friendly working relationship between the amputee and herself. During the early stage, the prosthesis is more of a hindrance than an aid for he has been relying on his sound arm for everything. It is necessary for the therapist to maintain the interest and enthusiasm of the amputee throughout his training period, in order that he may realize the full potential of his prosthesis. There are

still too many amputees with an empty sleeve for one reason or another, and if a therapist can do not more than to create a receptive attitude in the amputee toward his prosthesis, half the problem of training has been won.

## 1. Prosthetic Controls

### Single control

Below-elbow amputees have only one consideration with single control and that is hook or hand operation. By flexing the humerus, the hook or hand will open or close.

### Dual control<sup>1/</sup>

Humeral flexion controls two motions: (a) Forearm flexion when the forearm is unlocked, (b) terminal device operation when the elbow is locked. Above-elbow amputees must first learn to use the elbow joint.

(1) Sitting or standing, arm at side. Flex the prosthetic elbow to 45 degrees by thrusting the arm forward. Relax slowly. Flex the elbow to 90 degrees and relax slowly. Flex the elbow as far as possible and raise the hook to the mouth and relax slowly.

(2) Sitting or standing, arm at side.. Flex the elbow to 45 degrees and lock the elbow by thrusting the arm gently backward, and at the same time, allowing the shoulder on the amputated side to flex or come forward slightly. If the arm is extended too far backward, the forearm will fall. Sometimes the elbow must be elevated slightly. The elbow will click when

<sup>1/</sup>Veterans Administration, A guide for the Arm Amputee, Pamphlet, October, 1952, Number, 10-32, Washington D. C., pp. 8.



Plate 31



Plate 32

Approach and grasp activities. Plate 31, the thumb of the hand in open position to grasp the large object, plate 32, the thumb of the hand in closed position to grasp the small object

locked. Unlock the elbow by thrusting the arm downward and backward. Flex the elbow to 90 degrees and repeat the locking procedure. Flexion should always be in the parasagittal plane with the shoulder kept in a fixed position. Locking the elbow while maintaining forearm flexion is a tricky operation. To maintain flexion, the humerus must be in a forward position, and to lock the elbow the humerus must be thrust slightly to the backward plane. The locking movement must be executed very deftly in order to keep the forearm flexed. Arm flexion movements should be confined to the amputated side for the unilateral amputee unless it is a case of a very high amputation, or a shoulder disarticulation and the upper arm piece is integrated with the shoulder cap. In these cases, the shrug control is used as the source of power for forearm flexion and prehension.

(3) Terminal device operation. (a) Flex the elbow to 90 degrees by flexing the humerus. Lock the elbow, and flex the humerus again to the degree necessary to operate the terminal device.

(4) Arm rotation. Sitting or standing, abduct the humerus to 60 degrees, flex the elbow to 90 degrees, lock, roll the arm in and out.

#### Triple control

Three cables are used to control three prosthetic motions. The motions are the same as for dual control except that shoulder shrug on the sound side operates the terminal device.

(1) Terminal device operation. Sitting or standing, flex the elbow to 90 degrees by flexing the humerus. Lock the elbow, and shrug both

shoulders slightly. The motion is described as, rounding the shoulders.

## 2. Approach and Grasp

Once the amputee has mastered the fundamental controls of the arm, training should be progressed to grasping various objects with the hand and arm in different positions.

A training kit can be obtained which contains objects for use of initial training in approach and grasp. It contains blocks in different sizes, shapes, and thicknesses in wood, metal and rubber. These objects are approached and grasped with the prosthesis, and placed in the spot designated for them (plates, 31, 32, page 70). Other items in the kit are a fork, spoon, plastic block, padlock and key, nail file, ice cream cone, paper cup, screw cap jar, and others. These objects enable the amputee to learn the use of locking positions, free wheeling on the voluntary closing appliances, and the correct amount of tension to apply in picking up objects of different weights, sizes and compositions.

### Operation of the voluntary closing hand

The method of operation of all voluntary closing appliances (APRL) is pull to close. The hand has a three finger gripping force, two of which are operated by the voluntary pull to close. The thumb must be prepositioned manually. The maximum gripping force is about 39 lbs. which would automatically unlock if the fingers stuck. The thumb has two positions, which is usually operated by the other hand or by pressing the thumb against the body or an object.

(a) Open position. Press the tip of the thumb toward the palm.



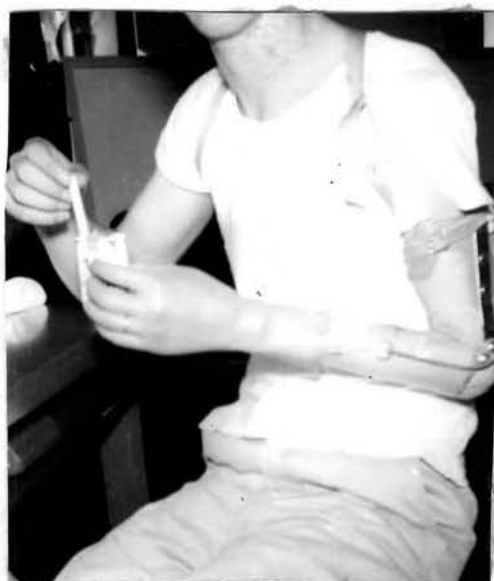

Plate 33



Plate 34



Plate 35

Two handed activities. Plate 33, taking a cigarette from the package,  
Plates 34, 35, tying a tie



Plate 36



Plate 37

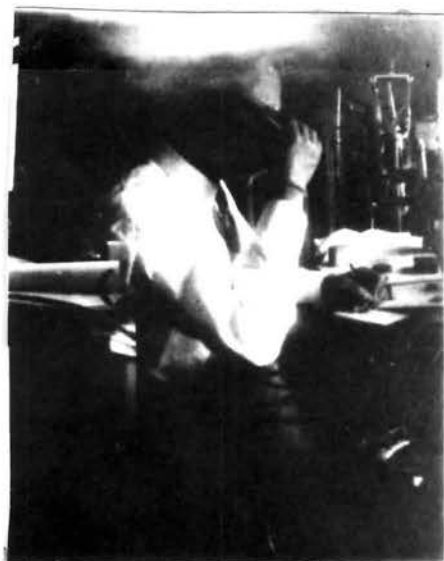

Plate 38



Plate 39

Two handed activities. Plate 36, BE amputee cutting food, Plate 37, AE amputee cutting food, plate 38, BE amputee using a telephone and writing a message, plate 39, AE amputee using a telephone and writing a message



Plate 40



Plate 41



Plate 42

Two handed and prosthetic hand activities. Plate 40, opening a beer can, plate 41, carrying a food tray, plate 42, using a button hook and buttoning a shirt sleeve button with the prosthetic hand

Release the pressure and the thumb will spring wide open.

- (b) Closed position. Press the tip of the thumb toward the palm slowly, stop at the first click. Relax completely.

The thumb is positioned before attempting to grasp an object. If the object is small, the thumb must be put in the small opening, otherwise, the thumb cannot make contact with the small object.

The pull to-close-the-two-movable-fingers can be stopped at any point desired, but in order to lock the fingers at that point, the tension must be completely relaxed. To open or unlock this position, it is necessary to make another pull on the control cord (a little harder than the pull to close) then relax completely again, and the fingers will spring open. When they have opened fully, there will be another click which cocks the fingers for the next pull-to-close. It is done in four movements.

- (a) Pull-to-close
- (b) Relax-click-lock
- (c) Pull-click-unlock
- (d) Relax-fingers-open-click

An important thing to remember, is that the fingers will not lock unless the movement is started from a completely relaxed position! The amputee should be able to close, lock, and open the hand at waist level, and at his mouth, otherwise the harness should be checked. The shoulder straps may be too loose or too tight, the control cable may be too long, or there may be sharp bends causing too much friction in the control sys-

tem.

### Operation of the voluntary closing hook

The voluntary closing hook has a two prong gripping force, one of which is movable with the pull-to close. The hook is carried in a medial position but must be pronated still more to put in a position of grasp. Hook operation is described in this manner.

- (a) Pull-to-close
- (b) Relax-click-lock
- (c) Pull-click-unlock
- (d) Relax-click-prongs open

An above-elbow amputee, wearing either a hook or a hand, must make sure that it is locked before attempting to lift an object. The prongs of the hook must be closed when the position of the lever on the case is changed.

With the voluntary opening hook, the pull-is-to-open the prongs of the hook. Amount of tension on the object is determined by the number of rubber bands on the hook and the way that the amputee relaxes tension of the opened position.

Training in approach and grasp should not be over-emphasized lest the amputee lose interest in his prosthesis. Many of the items used in approach-and-grasp are things that the amputee may never be called upon to do in daily living. This phase of training is to accustom the amputee to a variety of approach-and-grasp-activities in different situations such as: objects that are placed low and objects that are placed high;

very fragile and very heavy objects; different materials; thick and thin; and etc.

### 3. Two Handed Activities

One cannot expect the prosthetic arm to operate with the same coordinated movements of the natural arm. Every motion is the result of a carefully, thought out plan by the design engineer, and it requires a lot of patience and practice on the part of the amputee to gain proficiency in its use. The natural arm without the hand is little more than a crane with tactile sensation, but when a prosthesis is worn, it becomes a valuable assistant. The number and dexterity of activities that each amputee can perform varies with the site of amputation and the desire to become self sufficient. Every therapist should keep a list of activities to be accomplished, a method of rating the performance, and the time required to perform the activity. The time element is not considered a major item when learning to use the prosthesis. It should be used only as an indication of progress, because the time will decrease as avoidable delays and awkward movements are eliminated. Dexterity should come first, and speed should come last, but in no case should the time element be forgotten because many amputees do not wear the prosthesis, as they say, "it takes too long to perform the activities."

The activities listed on the following pages would probably be found on the list of beginning activities of every therapist. They are general and considered a minimum. Every therapist should keep not only her list of training activities, but a record of, "tricks of the trade,"

which she can pass on to others.

### Unilateral

Following is a list of activities that can be performed best with the normal hand acting as major, and the prosthetic hand acting as the assistant, with a few activities that can be done with either hand. <sup>1/</sup>

Activity	Prosthesis	Normal Hand
Take cig. from package	Hold cig. pack Reverse procedure	Take cig. out (plate 33, Reverse procedure page 73)
Book matches	Hold the book	Strike the match
Key in lock	Hold door knob	Turn the key
Open the door	Take key from lock	Turn door knob
Card playing	Hold cards	Play
Tie a tie	Hold short end	Form the tie (plates, 34, 35, page 73)
Pocket Knife	Hold knife	Open
Cutting food	Hold fork in food	Cut with knife (plates, 36, 37, page 74)
Pencil sharpener	Hold pencil Reverse procedure	Turn crank Reverse procedure
Screw top bottle or tube	Hold bottle or tube	Unscrew cap
Telephone and write message	Hold phone to ear Reverse procedure	Write message (plates, 38, Reverse procedure 39, page 74)
Bottle opener	Hold bottle (concluded on next page)	Lift cap

<sup>1/</sup>R. Deane Aylesworth, op. cit., Section, 8.3.3.

(concluded)

Activity	Prosthesis	Normal Hand
Beer can	Hold can	Punch hole (plate 40, page 75)
Nail in the wall	Hold the nail	Pound with hammer
Drinking cup	Carry to mouth	Put into pros. hand
Carry food tray	Grasp one side of tray	Grasp other side (plate 41, page 75) of tray
Wrap and tie package	Grasp paper and string	Wrap

#### Prosthetic hand activities

- (a) Pull a glove on the normal hand.
- (b) Button shirt sleeve on the normal side (plate 42, page 75).
- (c) File the finger nails.
- (d) Clean the nails.
- (e) Wash the normal hand.

#### Bilateral

A bilateral amputee should learn to perform activities the shortest, and easiest way possible. The time required for a bilateral amputee to be self sufficient throughout the day is much longer than the time required for a unilateral amputee to be self sufficient. The bilateral amputee may learn to do many of the things that the unilateral amputee does, but the number and dexterity of things that he can do depend a great deal more on patience, persistence, and the desire of the amputee.

#### Undressing in the morning

If the clothes have been placed on a chair in the order which he is



going to put them on, it will be much easier for him. It is necessary for the amputee to put one prosthesis on (if the harness is separate) before he can remove his pajamas. Use the stumps to place the harness over his head and then insert the stumps into the buckets. Hold one side of the pajamas with the assistant hook or stump, and with the major hook, unbutton the button or buttons. It is wise to buy pajamas with only one button at the top and preferably a large button, or the slip-on type of pajama top.

#### Showering

The prosthesis or prostheses must be removed before showering and one stump sock left on if he is using any kind of device with a cuff on the stump. The sock will prevent chafing from the moisture. With the aid of a device, such as a long handled brush, the amputee is able to reach all parts of the body.

#### Dressing

After showering, a T shirt should be put on to prevent rubbing of the harness. Put the stumps into the sleeves of the T shirt and swing it over the head. The bottom can be grasped between the two stumps and pulled down. Don the prostheses again.

If the shorts have been provided with snaps and the corresponding snaps placed on the inside of the top of the trousers they can be pulled on in one operation. Grasp each side of the top of the trousers with the corresponding hook and pull up. Trousers should have a zipper front with a clasp added to the tab for better grasping.

The shirt may be put on by putting the two prosthetic arms into the sleeves of the shirt and throwing the shirt over the head. If he wishes to have buttons, he can use a button hook. With the new wrist flexion unit it is not too difficult. Shirts with grippers on the front instead of buttons can also be had and are easy to put on.

Socks are donned by grasping the corresponding side with the hook and pulling. Tension over the heel can be freed by grasping the inside of the heel and pulling.

The moccasin type of shoe or the kind with a zipper in the side are easier to get into. A shoe with not more than two and preferably one eyelet is best. If lacing is preferred, grasp the tip of one lace with the hook on the corresponding side and push it through the hole or eyelet, catch it on the other side with the other hook and pull the lacing through. Cross the lacing to the side of the opening and perform the same steps until the top hole is reached. Do the same with the other end of the lacing. Grasp both strings and apply tension. When the bow knot is begun, thrust one lace over the other lace twice for better tension. Fold a loop in one end of the string, at the same time, catch the loop in place with the other hook, and then with the hook that made the loop, catch the other string, bring under the loop and catch with the hook that was holding the first loop in place. Now the two loops can be grasped with the two hooks and pulled as tightly as wanted.

Many amputees prefer to wear the sport type of shirt with an open collar to eliminate the task of tying a tie. Of course, ties both long

and the bow type can be bought made up, but there are times when the amputee wants to tie his own tie which can be done. It can first be tied over a bed post or chair and then slipped over the head and tightened, or it can be done on the amputee in the usual manner. Place the tie around the neck under the collar, adjust the tie ends and cross the left end over the right. Grasp the crossed tie ends at the crossing with the right hook. The left end is flipped over this crossing and pulled up behind and over the neck loop allowing it to come down in front. Push the tip of the larger end through the center of the knot with the left hook. Release the left hook and grasp the protruding large tie end and pull it entirely through. Tighten the tie by pulling on the smaller end with the right hook and push the knot upward with the left hook to desired tightness.

### Clothing

Arm amputees have considerable trouble operating the controls of the arms when clothing is tight. Special clothing can be bought, but more often, the amputee prefers to use discretion in choosing conventional clothing.

Shirts, coats and overcoats should have ample room without any constriction on the controls of the arm and yet not too large to cause bunching. Linings should be smooth and firm and free from wrinkles to permit the hand or hook to enter the sleeve of the garment without catching. The box-type of pocket on a coat is hard in which to put the hand or hook. Slanted pockets should be had whenever possible. Soft leather reinforce-

ments should be added to areas of clothing where there is friction with the controls or the prosthesis. Large buttonholes make buttoning easier. Zippers are used in many instances instead of buttons. Zippers are easier to use if large rings are added to the tabs.

An upper extremity amputee should always be on the alert for shorter and easier ways of performing daily activities without drawing undue attention to the act of performance.

#### Shaving

If tube shaving cream is used, the tube is placed on a shelf, held firmly with one hook and with the other hook the cap is unscrewed. When applying cream, the arm is moved instead of the face. An electric razor or safety razor can be used. The razor is simply grasped between the two prongs of the hook and moved up and down as required.

#### Combing the hair

A rat-tail comb is the easiest to use. The tail can be braced between the prongs of the hook which steadies the comb.

The methods described here are meant only, 'as one way of doing specific activities.'

### 4. Women and Children 1/

#### Women

By and large, women and children use the same prosthetic appliances and present the same prosthetic problems as the men with few exceptions.

1/Kessler Institute for Rehabilitation, Seventh Annual Conference, April 24, 25, 1953.

Appearance is more important to a woman than function. A woman who has a below-elbow, amputation stump will often prefer a plastic hand to a prosthesis because there is no unsightly harness or hook, and the appearance is more like a normal hand. The junction of the arm and plastic hand can be disguised by a watch, bracelet, or three-quarter sleeve. Nail polish and rings can be worn on the hand as with the normal hand.

Above-elbow amputees often prefer a cineplastic arm to a harness operated arm. Movements of the cineplastic arm are more life-like. The mutilation of the muscle tunnel can be disguised more easily with clothes than the harness. Shoulder and chest expansion of a woman are often not sufficient for good prosthetic control of a harness-operated arm. A few women prefer the harness-operated arm to having further mutilation of the stump or shoulder necessary for a muscle tunnel. Basic instruction in control and use of the arm are the same for a woman as for men with greater emphasis on performing her own toilette, dress, and household duties.

### Children

Function is more important to a child than appearance. If a child can grasp the handles of his bicycle, use a saw, dress a doll, or eat with his prosthesis, he is not too concerned with how it looks. A truly functional prosthesis has not been devised for children yet. Hooks do not come in a variety of sizes. A split hook is generally used for children under ten years of age. A harness operated prosthesis is often impossible because the chest and shoulders are too small for the prosthetic controls. Weight of the prosthesis is becoming less of a problem since

the use of plastic has come into practice for sockets. At Kessler Institute for Rehabilitation, the cineplastic prosthesis is widely used for children. Many congenital, unilateral, and bilateral amputees are given a pectoral muscle tunnel or tunnels at this institution and they are happily assuming their rightful places in the home and among other children.

Teaching the child the controls and use of a prosthesis is not too difficult. They learn fast, and their eagerness to do the things that other children do is a very powerful motivator. A five or six year old will learn faster than a child of twelve years. A pre-school child will adjust to a prosthesis better than one who is older. Children in school will adjust to a prosthesis better than to a deformity, or, to a deformity and then to a prosthesis.

Children are a challenge to rehabilitation. A prosthesis that is suitable for present specifications and provisions for growth adjustment is a problem of no small importance to the prosthetist and an item of great expense to the parents. The child must have a new prosthesis almost as often as he has a new pair of shoes.

Congenital amputees offer still other problems. Some surgery must be performed on almost all cases before the question of a prosthesis can be considered. The age of the child, the level of the amputation, how much the child has to supplement the prosthesis, and many other considerations must be accounted for before surgery. Very often, the parents of the congenital amputee suffer from feelings of guilt, shame, or

over-protectiveness which have existed from birth of the mal-formed child. These feelings must be dispelled by a psychiatrist, or some member of the rehabilitation team before they can fully cooperate with the rehabilitation of their child.

### 5. Prescriptions and Training

The next few pages are devoted to actual prescriptions for prostheses, which were ordered by the surgeon on the basis of individual needs as decided by the evaluation team of the prosthetic clinic held once a week in The Veterans Administration Regional Office, department of Physical Therapy, Boston, Massachusetts. <sup>1/</sup> Observation of the amputees was followed through physical therapy, (when indicated) delivery of prostheses, initial and final checkouts, and training. These amputees are veterans of World War I, World War II, and The Korean War. Nearly all have been wearers of prostheses before these prescriptions, since the majority of them received their amputations during World War II.

#### Below-Elbow

Mr. A. has a left, long, amputation stump with good musculature, full range of motion, screw-driver shape, and no phantom limbs. He is a "wearer" now, and since he has always been right handed, he has continued to make this hand dominant and the prosthetic hand the assistant. His occupation is maintenance inspector.

PRESCRIPTION.— His new prescription calls for a rotation type, double-wall socket, wrist rotation unit, strap hinge, figure-eight, Vinyon harness, with an APRL hand and hook.

TRAINING.— This amputee was considered a good user of the old prosthesis, but did not use the prosthetic limb as an assistant when eating. He

<sup>1/</sup>Permission was granted from the Veterans Administration to use this data.



had initial training of two hours during which he learned the prosthetic controls and performed the training activities specified very well. He did not care to give up the habit of using only the natural hand for purposes of eating.

Mr. B. has a right, long, amputation stump with good musculature and full range of motion of the surrounding joints. Pronation and supination are limited to 60 degrees. He was right handed before the amputation and since then has made the left hand dominant. No feelings of phantom are felt. He considered his old prosthesis adequate, and came in for a new prescription because it was badly worn. He used both a hand and hook interchangeably and had the voluntary closing control system. His profession is trumpet player, and it is necessary to use a wrist flexion unit to hold the trumpet in place.

PRESCRIPTION.— His new prescription for a prosthesis is a rotation type, plastic laminate, double-wall, forearm socket, APRIL hand and hook, figure-eight, Vinyon harness, triceps pad, strap hinge, T bar reactor and inverted Y suspensor. The old wrist flexion unit can still be used with the new prosthesis.

TRAINING.— The amputee had formed the habit of using both shoulders to operate prehension force to the terminal device. It is necessary to use only humeral flexion on the amputated side. He could not be persuaded to give up the habit and was allowed to take the prosthesis home after initial training of two hours.

Mr. C. has a left, amputation stump of 50 per cent length with good musculature and full range of motion of the elbow. The stump is conical in shape and has 60 degrees of pronation and supination. He was right handed before the amputation and has continued to use the natural hand as major and the prosthetic hand as the assistant. He has no feelings of phantom. He has been using a Dorrance Hook for all activities including playing the piano and typing. He is a clinical psychologist, having superior intelligence and ability for adjustment. He objects to wearing a hand because "it is not functional enough." He does not mind the appearance of the hook.

PRESCRIPTION.— The prescription consists of a double-wall, plastic laminate, forearm socket, flexible hinge, model C wrist unit, no rotation unit, figure-eight, Vinyon harness, half-arm cuff, inverted Y suspensor and T bar reactor plus a Sierra, two-load hook. He did not want to change to the voluntary closing system because of the relearning involved. He was happy with the old type of prosthesis, and was an excellent user, which is a very good argument for not changing. Needed initial training for checking the mechanics of the prosthesis which was sufficient in his case.

Mr. D. has a left, amputation stump of 5 inches in length. The ulna has been removed which reduced the size of the stump and left multiple scars. Flexion of the forearm is limited to 30 degrees and



and extension lacks 15 degrees. There is no pronation or supination, and strength is very poor. He was right handed before the amputation and has continued to be so, using the prosthetic hand as an assistant. He is an elevator operator and likes to do carpentry and general work with tools. He is intelligent and appears to be well adjusted. At times, he feels a phantom at the tip of the stump; at other times it is only a dull ache; still other times there is only a feeling of numbness.

PREScription.— A double-wall, plastic laminate, forearm socket to compensate for the size of the stump. A screw-in wrist unit, with an APRL hand and Sierra two-load hook, polycentric elbow hinges, figure-eight, Vinyon harness, and half arm cuff.

TRAINING.— When he received his prosthesis, the control efficiency of the hand was 60 per cent and of the hook 80 per cent. Hand and hook opening at the mouth and at the fly were 80 per cent. At the first check-out, it was decided that greater efficiency could be accomplished if the control plate was moved to a more lateral position, which was done, and at the final check-out, control efficiency was improved. Mr. D. learned to be a good user and tried successfully to perform a variety of activities (plates 41, 42, 43, page 75). The amputee stated that he could not hold a nail with the particular slant of the two-load hook, and was advised to buy the type of hammer that holds the nail. He had five hours of training.

Mr. E. has a left, amputation stump, three inches in length, having good musculature and complete range of motion. There is no sensitivity or phantom sensation. He is an office worker and has always used a hand. He does a variety of activities, but does not use the prosthetic hand to assist with telephone and messages.

PREScription.— The prescription was a plastic laminate, double-wall, forearm socket with metal side joints, full arm cuff and figure-eight, Vinyon harness, an APRL hand, FM wrist unit but no hook.

TRAINING.— He could open and close the hand fully at the fly but lacked about two inches being able to get the hand to the mouth. It was necessary to bend the head forward a bit to meet the hand. The prosthesis was considered satisfactory at the final check-out. He was considered a good user of the hand when initial training of two hours was finished including the use of the telephone.

Mr. F. has a very short, left, amputation stump of good musculature, full extension but limited forearm flexion. There is sensitivity on the radial side of the distal end of the stump. A phantom hand, and sometimes pain is felt somewhere between the normal hand length and the stump end. He was right handed before the amputation and continues to use the normal hand as dominant, and the prosthetic hand as the assistant. His occupation is not known, but is considered to be fairly intelligent.

PREScription.— The prescription given was a split-socket, plastic lamin-

ate, forearm piece with polycentric elbow hinges to permit full forearm flexion. A Dorrance hook and an APRL hand, figure-eight, Vinyon harness, model C wrist unit and an auxiliary arm lift completed the prescription. It was suggested that a hole be left in the inner socket to relieve the pressure on the sensitive spot.

TRAINING.— At the initial check-out, it was thought that an FM wrist unit would have made the task of changing the hand to the hook an easier one. The hole, which was left in the inner socket to relieve the pressure on the sensitive areas did not prevent the skin from being rubbed off after use for an hour. He was advised to wear a different weight stump sock. He formed an unnecessary habit of raising the elbow too high when using the prosthesis, otherwise, he was considered a good user of both the hand and hook after five hours of training (plates, 21, 22, page 36).

Mr. G. has a very short, left amputation stump of good strength and full range of motion. There is no phantom, but he sometimes has a slight finger itch. His profession is mail clerk, and he uses the hand to do everything. He does not like a hook. His hobby is carpentry.

PRESCRIPTION.— The prescription given was a double-wall, plastic laminate, forearm socket, to be bent about 15 degrees to aid flexion. Polycentric elbow joints, figure-eight, Vinyon harness, and a half-arm cuff were added. The harness was to be crossed to the right, first at the center, and lower than usual in back. A quick disconnect wrist unit, an APRL hand and no hook completed the prescription.

TRAINING.— This amputee learned to use the prosthesis very well for activities in the region between the shoulder and the belt level. He lacked about five inches being able to reach his mouth and could not use the hand to full efficiency near the fly. He had two hours of training.

Mr. H. has a very short, amputation stump, with full extension and only 50 degrees of flexion. He has poor strength and musculature, and multiple scars. He has no phantom limbs, but sometimes feels pain at the distal end. He does not work and has no hobbies.

PRESCRIPTION.— Because of this man's disability, he was given an above-elbow type of limb, having the usual plastic laminate, forearm socket, Sierra two load hook, no hand, a plastic, upper arm cuff with APRL side elbow hinges, quick disconnect wrist unit, and figure-eight, Vinyon harness. He did not return for training.

#### Above-elbow

Mr. A. has an above-elbow, right amputation stump of 90 per cent length with complete range of motion at the humeral joint, and fair strength and musculature. The terminal portion of the stump is small and atrophied. He has no pain, sensitivity, or phantom sensations. He

was right handed before the amputation, but since the amputation has made the left hand dominant. His profession is radio and television repairman. He appears to be well adjusted and intelligent.

PRESCRIPTION.— The prescription calls for a plastic laminate, conventional forearm, double wall, upper arm piece, an APRL hand and Sierra two load hook. This hook was recommended because he needs a very positive locking device. The remaining pieces of the prescription was an FM wrist unit, model C Hosmer elbow, figure-eight Vinyon harness with modifications, and dual control.

TRAINING.— At the initial check-out, one of the buckles did not work smoothly and the prosthetist repaired it. The arm fitted very well and the amputee liked it. He wore the arm home after the first three hours of instruction in use, and had the final check-out after six hours of training. He was able to perform all the training activities with fair degree of skill and dexterity, and wore the arm most of the time.

Mr. B. has a right, amputation stump of standard length, having normal range of motion and good musculature. He has no sensitivity or phantom pain. He was right handed before the amputation and since then has made the left hand dominant. His occupation is glass inspector, and he likes to bowl and work around the house. The old prosthesis is badly worn and the glove is discolored. He has always worn a hand, but is not averse to having a hook prescribed also.

PRESCRIPTION.— A conventional, plastic laminate, forearm socket, double-wall upper arm piece, an APRL hand and a Dorrance 88 hook, model C elbow or equivalent were ordered. This particular hook was ordered because he needs a light weight hook. He was also given an FM wrist unit, and modified Carnes harness with dual control.

TRAINING.— The amputee was shown the prosthetic controls of the arm and did not return for further training.

Mr. C. has a standard length, right, amputation stump which is small and atrophied. There is complete range of motion at the humeral joint, but strength and musculature are poor. He was right handed before the amputation and has made the left hand dominant since the amputation. Mr. C. is a retired, World War I veteran who does gardening and light work around the house. He has never worn a hand and has used a Dorrance 8 and a Farmer's hook interchangeably.

PRESCRIPTION.— The prescription was a conventional, plastic laminate, forearm, a double-wall, upper arm piece, model C elbow or its equivalent, an FM wrist unit, an APRL hand and hook, and figure-eight, Vinyon harness with modifications, and dual control.

TRAINING.— When the amputee received his prosthesis, the upper-arm piece did not fit perfectly and he had to return to the limb shop for a new socket. The new socket fitted well and the amputee was able to take the prosthesis home after four hours of training. He liked the new prosthesis and could do all the training activities moderately well after 10 hours of instruction.

Mr. D. has a right, amputation stump of standard length, which is cylindrical in shape, with normal range of motion but poor musculature and strength. He has pain and needle sensations on the terminal portion of the stump most of the time. He was left handed before the amputation and has continued to make this hand dominant. His occupation is mail room clerk and he has worn a hand from 12 to 15 hours a day. The evaluating team thought that a hook would service this amputee better than a hand in his work.

PRESCRIPTION.— The prescription ordered was a conventional forearm, double-wall, upper-arm piece, (4 layers of stockinette, and 1 layer of glass cloth) model C elbow or its equivalent, an FM wrist unit and no accessory units. The remaining pieces of the prescription were, figure-eight, Vinyon harness with additions and dual control, an APRL hand, and hook.

TRAINING.— When the prosthesis was delivered, it was not considered a good fit. There was mal-function of the hand, the elbow joint stuck, and the front suspensor had to be moved up to be in line with the cable. The coordination of the amputee was poor and he developed a high spot on the terminal portion of the stump. Consequently, he was sent back to the prosthetist again and again, and his training periods had to be limited to  $\frac{1}{2}$  hour per week. He could not get the hand to the mouth with ease for which there was no very good reason. He took the prosthesis home and was considered a fair user after seven hours of instruction.

Mr. E. has a right, amputation stump of medium length with complete range of motion and fair musculature. The stump is cylindrical in shape with a burning sensation on the terminal portion. There is also a phantom hand at the terminal end when he thinks of it. He is a lawyer by profession and does not use the hand or hook to any extent. He was right handed before the amputation and since then has transferred all major activities to the left hand.

PRESCRIPTION.— The prescription was, a conventional forearm, plastic laminate, upper arm piece, model C elbow, an APRL hand, and hook, an FM wrist unit, a wrist adapter, figure-eight, Vinyon harness with modifications and dual control.

TRAINING.— The arm fitted well but the amputee does not have a great desire to be proficient in the use of this arm. After six hours of instruction, he had learned the prosthetic controls and the use of the hook but did not return for instruction in the use of the hand.

Mr. F. has a left, amputation stump of standard length, cylindrical in shape, of normal range of motion and poor strength. There is a heavy scar on the terminal end of the stump. He was right handed before the amputation and continues to be so. He is a letter carrier and holds the letters in his hook while distributing mail. He has never worn a hand. The evaluating team decided that he needs an arm of light weight and a positive locking hook, which, in this case would be better serviced by a two load hook. He has been using the voluntary opening system and with a two load hook, there would be no relearning involved.



PRESCRIPTION.— The prescription was a conventional forearm, double-wall, upper arm piece, model C elbow or its equivalent, an FM wrist unit, an APRL hand, glove, and a Sierra two load hook, figure-eight, Vinyon harness with modifications and dual control.

TRAINING.— At the initial check-out the prosthetic controls were considered good and the arm fitted well with the exception of one axilla loop which necessitated the return to the limb shop for slight revision. This amputee was considered a very good user of both the hand and hook after nine hours of training. Since he had never used a hand, most of the training time was spent learning the use of the APRL control system.

## 6. Summary

Training in the use of a prosthesis should begin as soon as the amputee receives it from the limb shop. It is important that the therapist create an enthusiastic and harmonious atmosphere in their relationship during the training period in order that the amputee may realize the full potential of his prosthetic appliance.

An amputee must first learn the prosthetic controls of his prosthesis, second, approach and grasp, and third, two handed activities. The controls of a below-elbow arm consist of hook or hand operation only. If the level of amputation is above-elbow, the prosthetic arm is either dual or triple controlled. Dual control means that two cables control three motions; elbow lock, forearm flexion, and hook or hand operation. Triple control means that three cables control these three motions.

When the controls of the arm have been mastered, the amputee is taught correct approach and grasp of items of different sizes, weights, and compositions, and then his training is progressed to two handed activities. With the majority of amputees, the natural arm will assume the role of leader and the prosthetic arm will become the assistant. The

therapist should keep a list of activities to be performed, which are things that the amputee is not necessarily expected to do in daily life, but which will give him practice in a variety of activities.

A bilateral amputee can perform the same activities as the unilateral if he has sufficient patience, persistence, and a strong desire to be self sufficient. He should learn to do everything the easiest way for him. It is a major feat if the bilateral amputee can and will dress himself, shower, shave and feed himself without assistance. It is not unusual for a bilateral to hold an important job, but when he leaves his office and enters his home, he often has an assistant to do everything for him. This is attributed to the fact that many amputees do not take the time to learn to do the necessary details of daily living well. He should always be alert for shorter methods of doing everything so that his prosthesis will become increasingly more important to him. For instance, by using a cuff on his stump and a long handled brush, he can take a shower comfortably. With the aid of a button hook he can button his own clothes. Grippers can be put on shirts, shorts and trousers. With a little more time and effort the bilateral can do everything the conventional way.

There is little difference in the prostheses and training for women and children and for men. Women usually prefer a good cosmetic appearance to function. Whenever possible, a woman will choose to wear a plastic hand to a prosthesis because its appearance can be disguised more easily. Cineplasty is often preferred to a harness operated arm for the

same reason.

Children care little for cosmetic appearance if the prosthesis is functional. Their greatest desire is to be able to do the things that other children do. A cineplastic arm is often prescribed because shoulder and chest expansion are not sufficient for a harness operated arm. Congenital amputees must often have some surgery before the question of an adequate prosthesis can be brought up. The parents of these children often must have psychiatric guidance before they can properly cooperate in the rehabilitation of their child. Children in general outgrow their prosthetic appliances and must have adjustments and replacements often. Truly adequate prostheses have not been made for children.

### Further Research Needed

How completely independent is the upper extremity amputee with present prosthetic devices is a topic one often hears discussed today. Some are of the opinion that with a prosthesis having an interchangeable hook and hand, the amputee is able to do everything that a person having two normal hands can do. The writer agrees with this opinion if one is willing to overlook the factors that the amputee must overcome in order to attain complete independence.

With the present devices, the therapist can do no more than to teach the amputee the controls of the prosthesis. Among the many upper extremity amputees, we find varying degrees of proficiency, ranging from little more than cosmetic effect to near 100 per cent efficiency. Independence is a matter of temperament and the "stick-to-it" qualities of the individual amputee. A man with a wooden peg for a leg is able to walk and to become a good dancer if he sticks to the task long enough. The cave man and the pioneer were self sufficient and independent when they put enough effort into the task of procuring the necessary food and shelter. Is this independence? The answer is yes, but at what price independence. Our civilization demands the greatest independence with the least expended effort. With this in mind, one must say that the upper extremity amputee is not independent.

The present model hook is not as functional as the normal hand, and the artificial hand is not as functional as the hook. Obviously,



the greatest need for research is in the artificial hand. The primary objective is to make an artificial hand that is as functional as the hook, and the ultimate objective is to make an artificial hand that is as functional as the normal hand. The first need is an improvement in materials to make a hand that weighs less, and at the same time, is more functional than the present model. (2) There should be some sensory control. Unless the hand is cineplastically controlled, the amputee must watch every movement made by the hand. (3) There should be five articulating fingers with movable, interphalangeal joints. (4) The plastic glove should be improved. The present model reacts to stains and tears too easily for general wear.

Therefore, one must conclude that the upper extremity amputee will be made completely independent when the artificial hand has that quality of motion at the wrist that makes it possible to stir a cup of coffee; (2) the sense of touch that enables the blind to see and to hear; (3) the graceful expressions of the normal hand that enables the dumb to talk, and the music conductor to lead; (4) the speed of a stenographer; (5) the delicacy of a jeweler; (6) and the power of a prize-fighter.

## SELECTED ANNOTATED BIBLIOGRAPHY

1. Advisory Committee on Artificial Limbs, sponsored by The National Research Council, Studies Relating to Pain in the Amputee, Progress Report, 1952, Series 1, Issue 23, pp. 116 (mimeographed). Department of Engineering Berkeley, Medical School San Francisco, California.

Results of studies made with three groups of amputees on painful and non painful phantom limbs and various other types of pain found in amputation stumps.

2. Aldredge, Rufus H. M. D., "Sites of Election and Stump Pathology," The Journal of OALMA (May 1951), pp. 4-8.

Ideal sites of election for amputation of the upper extremity.

3. Aylesworth, Deane R. (Editor), Upper Extremity Prosthetics. Manual, Artificial Limbs Project, sponsored by The National Research Council, Department of Engineering, University of California, Los Angeles, California, 1953, Sections, 1-10.

A workbook on prosthetics. It is a "how to do it" book in which basis of prescription and technical procedures are explained in detail.

4. Canty, T. J., "New Cineplastic Prostheses," Journal of Bone and Surgery (1951) 33-A, Number 3: 612.

Descriptions and illustrations of cineplastic prostheses.

5. Committee on Artificial Limbs, A Review of Literature, Patents, and Manufactured Items concerned with Artificial Legs, Arms, Harnesses, Hands, Hooks: Mechanical Testing of Artificial Legs, (December 1945-June 1947). Serial number Cal. 12 (mimeographed). Northwestern Technological Institute, Evanston, Illinois.

A review of items mentioned, with sketched illustrations in brief outline form.

6. Daniel, Earl H., Amputation Prosthetic Service. Williams and Wilkins Company, 1950, pp. 327.

A narrative description of all phases of rehabilitation of both upper and lower extremity amputees.

7. Deaver, George G. M. D., and Earle H. Daniel, "The Rehabilitation of the Amputee," Archives of Physical Medicine (October 1949), Volume 30 Number 10: 648-654.

Primary amputations and secondary surgical procedures are briefly explained; prostheses and rehabilitation are described in greater detail.

8. Jampol, Hyman, "Physical Therapy for the Upper Extremity," The Physical Therapy Review (November 1952), Volume 32 Number 11: 552-558.

Discussion and diagrams of methods of providing heavy resistance exercise for motions of the amputated stump.

9. Slocum, Donald B., Atlas of Amputations. C. V. Mosby Company, 1949, pp. 540.

An extensive atlas of methods of surgery in amputation of both upper and lower extremities in view of the best prosthetic function and successful rehabilitation.

10. Spittler, August W. Colonel, M. C., and Lieutenant Colonel Maurice J. Fletcher M. S. C., "Techniques of Cineplastic Surgery and Prosthetic Appliances for Cineplasty," Off-print, American Academy of Orthopedic Surgeons. Instructional Course Lectures. Volume 10, 1953, J. W. Edwards Company, Ann Arbor, Michigan, pp. 378-394.

Descriptions and illustrations of the techniques and sites of cineplastic surgery and recommended prostheses for the various levels of amputation.

11. Veterans Administration, Guide for the Arm Amputee, Pamphlet, October 1952, Number 10-38, Washington, D. C., pp. 8.

Description of the fundamental controls of the prosthesis.

## Glossary

Adhesion--Abnormal union of two surfaces as a result of inflammation

AE--Above-elbow

Amputation--Surgical removal of a diseased member, part, or organ

Axillary fold--Pertaining to the axilla or armpit; junction of the fleshy part of the arm and the axilla

BE--Below-elbow

Bilateral--Two sides of the body

Bulbous end--When the circumference of the distal end of the amputation stump is greater than the circumference of the remaining portion of the stump

Cineplasty--After amputation, formation of muscle on the stump to make it possible to impart motion and function to an artificial limb

Congenital anomaly--Anything occurring during fetal life or at birth that is contrary to the general rule which destroys the normal appearance

Contra-indication--When circumstances are unfavorable or against

Control harness--Harness that is made primarily for the controls of the prosthesis

Conventional prosthesis--A prosthesis made for general use as distinguished from a heavy duty or cosmetic prosthesis

Cylindrical shape--A long, circular stump of uniform diameter

Disuse atrophy--Diminishing in size of a part as a result of degeneration of the cell

Double wall socket--When the stump end is small or of abnormal proportions, the socket is made with an outer wall that extends the stump length and increases the outside diameter to permit a gradual taper down to the diameter of the wrist unit

Ductile--Flexible, tractible, capable of being drawn out in threads or wire

Edema--An abnormal amount of fluid usually intercellular and distending tissue spaces which normally are collapsed

Election--The act of eliciting the desired level; voluntary preference

Excoriation--Abrasion of the epidermis or the coating of any organ of the body

Figure-eight harness--A suspension and control harness that by nature of its make-up, resembles the figure eight

Flexible hinge--A hinge that consists of spiral wire housing and an inner cable covered by plastic tubing with metal insert strips, or a hinge made of leather strips

Friction turntable--A turntable for the above-elbow prosthesis located just above the elbow mechanism. By pulling the terminal device toward the midline of the body, the forearm and elbow are rotated into a position of work in front of the midline of the body

Full arm cuff--A cuff that encircles the arm completely above the elbow and provides greater stability for the below-elbow prosthesis than the half arm cuff or the triceps pad

Half arm cuff--A cuff that is not as large as the full arm cuff but larger than the triceps pad and used chiefly with the rotation or

split socket types of prostheses

Insert hinge--A semi-flexible hinge used mainly with medium and short below-elbow amputation prostheses

Immobilized--A part that is made stationary or immobile

Manual friction rotation unit--Commonly referred to as the "screw-in" wrist unit. Friction is increased or decreased by tightening or loosening the terminal device. 360 degrees of wrist rotation is possible but only moderate twist loads can be resisted

Manual lock rotation unit--A wrist unit having 360 degrees of rotation with 10 to 15 degrees in between positions which can be locked in. This unit is used when the hook and hand are to be used interchangeably because of the relative ease of changing from one to the other and because of its stability against twist loads

Metacarpel--A bone in the hand

Metal side joint--A rigid, metal joint having either single or double pivot.

Full forearm flexion is possible but no pronation and supination

Muscle motor--Tunnel formation in the muscle that constitutes the excursion and transmits power to the terminal device

Myotendinous junction--Junction of the tendon and muscle

Nudge control--A mechanism placed on the shoulder socket of the shoulder disarticulation prosthesis which operates the elbow lock and is activated by a slight pressure of the hand or chin

Phantom limb--An apparition or model of the missing limb

Plastic laminate--A socket made of laminations of stockinette and glass cloth and impregnated with resin

Polycentric elbow hinge--A rigid steel joint with step-up flexion action used to increase forearm flexion

Prosthesis--Replacement of a missing part by an artificial substitute

Prosthetics--The branch of surgery that treats with a prosthesis

Prosthetist--A person who makes prostheses

SD--Shoulder disarticulation

Shrug control--When a harness control strap is placed almost horizontally across the back of the shoulders so that so that flexion of both shoulders activates the control cord which transmits power to the terminal device

Single wall socket--A single wall socket is about half the thickness of a double wall socket, and is used when the diameter near the distal end of the stump is sufficient to permit a gradual taper down of the socket to the outside diameter of the wrist unit

Split socket prosthesis--A forearm socket designed for the very short, below-elbow amputation . It contains an inner socket made to fit the stump and an outer socket of the normal length and diameter

Static muscle contraction--Contraction of a muscle without movement of the limb

Step-up rotation unit--A stump driven rotation unit attached to a socket that increases the remaining pronation and supination by a ratio of 2.3 to 1

Suspension harness--Harness that is made primarily for suspension of the prosthesis

Terminal device--The prehensile tool attached to the distal end of the

socket which is generally a hand or hook

Trauma--A wound

Triceps pad--A four cornered piece of leather that fits over the triceps above the elbow that serves as an attachment for the hinge and control cord and stability of the socket

Tunnel pin--A plastic pin which is inserted through the muscle tunnel to which the control cables are attached

Unilateral--One sided